



CASE STUDY

A MASSIVE GROWTH IN AN UNCOMMON SITE IN MANDIBLE “PYOGENIC GRANULOMA”

¹Dr. Vasupradha, G., ²Dr. Evuru Prasanth, ¹Dr. Dinakaran, J., ³Dr. Bhaskar Jayaraman,
⁴Dr. Marathamuthu Karthikeyn, ¹Dr. Hema Latha and ^{*4}Dr. Karthikeyan

¹Department of Oral Pathology, Adhiparasakthi Dental College & Hospital, Melmaruvathur, Tamilnadu, India

²Department of Dental Surgery, Government Dental College, Andhra Pradesh, India

³Department of Periodontia, Sree Balaji Dental College & Hospital, Pallikaranai, Chennai 600100,
Tamilnadu, India

⁴Department of Oral & Maxillofacial Surgery, Adhiparasakthi Dental College & Hospital, Melmaruvathur,
Tamilnadu

ARTICLE INFO

Article History:

Received 18th December, 2016

Received in revised form

06th January, 2017

Accepted 25th February, 2017

Published online 31st March, 2017

Key words:

Massive growth,
Pyogenic granuloma,
Epulis.

ABSTRACT

On the gums lesions associated with gingival tissues means Epulis or Epulides. A reactive focal connective tissue proliferation confined only to gingiva, but its histopathology etiology is unknown. Fibrous epulis is a slow growing, painless, hyperplastic fibrous tissue mass located only in gums. Commonly found in anterior region of oral cavity. Here we report a case of giant fibrous epulis which occurred in the third molar region of mandible associated with impacted third molar. The case of fibrous epulis at the lower left quadrant of mandible for past 5 months duration is presented, it was painless, slow growing mass, on examination well pedunculated growth over the third molar on left lower mandibular region. Provisional diagnosis was fibrous epulis with impacted third molar tooth. Surgical excision was done under local anesthetic solution along with removal of impacted third molar and second molar also. Histopathology report suggests of pyogenic granuloma with no signs of malignancy. Considering the fact that all the clinical features resembles that for fibrous epulis, we would like to emphasize the good histopathologic consideration for the post – operative follow up by the dentist.

Copyright©2017, Dr. Vasupradha et al. This is an open access article distributed under the Creative Commons Attribution License, which permits unrestricted use, distribution, and reproduction in any medium, provided the original work is properly cited.

Citation: Dr. Vasupradha, G., Dr. Evuru Prasanth, Dr. Dinakaran, J., Dr. Bhaskar Jayaraman, Dr. Marathamuthu Karthikeyn, Dr. Hema Latha and Dr. Karthikeyan, 2017. “A massive growth in an uncommon site in mandible “Pyogenic granuloma”, *International Journal of Current Research*, 9, (03), 47957-47959.

INTRODUCTION

The word epulis is a gingival mass (or) tumour like lesion of gingival tissues with chronic inflammatory hyperplasia occurs due to reactive phenomenon. [1] Etiology of epulis includes trauma, chronic irritation due to dentures, faulty restoration, sub gingival calculus, etc. [2] Most commonly trauma and inflammatory factors favours epulis development. [3] It is of 4 types – granuloma, vascular, fibrous and giant cell. [1] Females are affected and most common site is anterior gingival region. [4] Fibrous epulis is a type of hyperplastic, painless lesion located at gingival which may be pedunculated (or) non – pedunculated and firm on palpation. [1,3] Color ranges from lighter shades of surrounding gingiva to red colour with presence of increased quantity of collagen and abundant vascularized granulation tissue. [3] Diagnosis is made based on its clinical findings followed by adequate surgical excision and sent for H/P examination. [3,5] Some investigators use the term

pyogenic granuloma for this lesion, fibrous epulis may represent as resolving pyogenic granulomas. [6,7]

Case report

A 46 year old female patient reported with a chief complaint of swelling in her left side face for past two weeks. Her past medical history reveals that she is a known diabetic for past 10 years and under medications. Her past dental history reveals a history of extraction of lower left back tooth region before 3 years. Later on she reported to a local dentist for intraoral swelling. On intraoral examination, pedunculated swelling of 4*2.5*3 cm size was noticed in left buccal mucosa.

Based on clinical findings, provisional diagnosis of fibrous epulis was made. Surgical excision of the lesion was done under 2% lignocaine local anaesthetic solution and submitted for histopathologic examination. Along with lesion removal, offending teeth were also extracted.

*Corresponding author: Dr. Karthikeyan,

Department of Oral & Maxillofacial Surgery, Adhiparasakthi Dental College & Hospital, Melmaruvathur, Tamilnadu

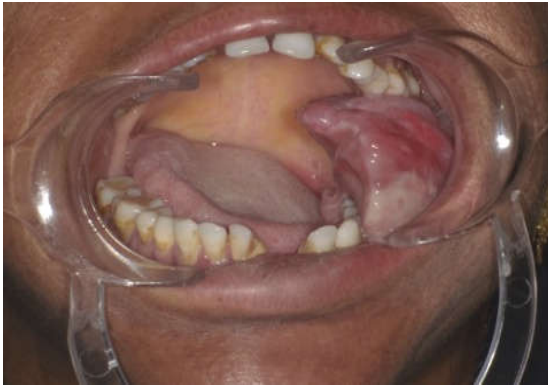

Figure 1. A pedunculated swelling seen on the left buccal mucosa

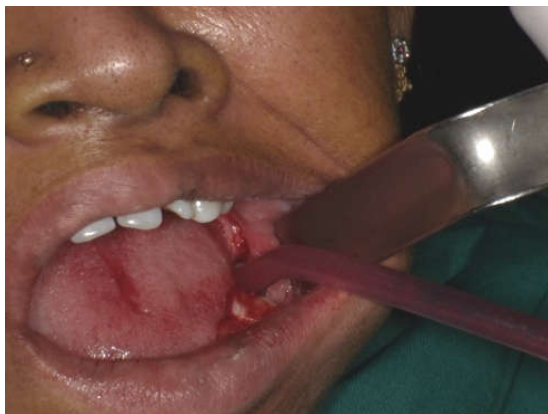

Figure 2. Lesion surgically Excised

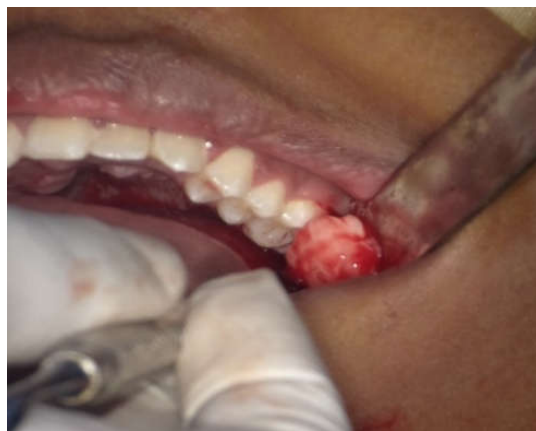

Figure 3. Teeth extracted out of the socket

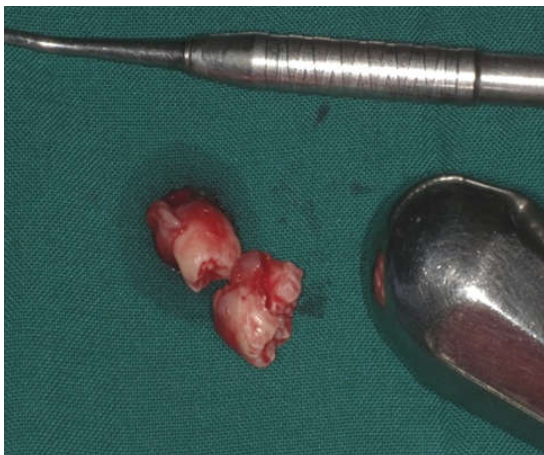

Figure 4. Extracted teeth

On histopathology examination, a given specimen shows parakeratinized stratified squamous epithelium with underlying connective tissue stroma. Fibrous connective tissue shows high cellularity with diffuse, moderate chronic inflammatory cell infiltrate and numerous endothelial lined blood vessels are seen. [Fig.no.5&6] Based on histopathological reports, it was diagnosed as 'Pyogenic granuloma'.

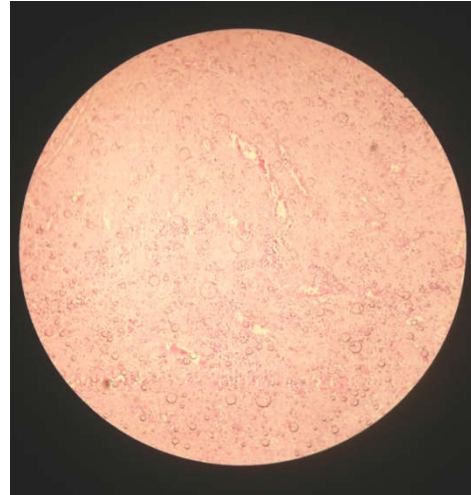


Figure 5. H&E stained section showing connective tissue stroma with endothelial lined blood vessels

DISCUSSION

Pyogenic granuloma – one of the most inflammatory hyperplasia seen in oral cavity. [8] It is a reactive exuberant overgrowth of granulation tissue resulting from irritation, injury or from infection by local tissues and hormonal factors [1,8,9] Because of irritation, underlying fibrovascular connective tissue becomes hyperplastic and there is proliferation of granulation tissue leads to formation of pyogenic granuloma. [10,11] The predisposing factors includes female sex, diabetic condition, subgingival calculus and age of 2nd to 4th decade of life, which are positive in this case report. Clinically it appears as exophytic growth with pedunculated or sessile mass usually hemorrhagic. The most common site includes lips, tongue and buccal mucosa and over the maxillary gingiva were affected. [8] Here in this case, mandibular gingiva was affected over left buccal mucosa. Many treatment techniques have been described for treating pyogenic granulomas which includes, surgical excision, laser therapy, cryosurgery and electrodesiccation.[8] Excisional biopsy is the simple procedure which was done here. Proper excision reduces the incidence of recurrences.

Conclusion

This case report is an effort to emphasise the importance of good clinical and H/P correlation to understand the variation of occurrence of pyogenic granuloma in oral cavity. The proper diagnosis and careful management of such an inflammatory lesion should be done by a dentist along with regular follow-ups reduces the rate of recurrences of such a trivial benign oral lesion.

REFERENCES

1. Head and neck diagnostic pathology – Liu Honggang.

2. Congenital fibrous epulis in infant – M Inanl, O Yalginz, M Pul, Yonsu *Medical Journal*, 2002.
3. Journal PDGI (59)3 Hal 90-94, Management of radicular cyst and fibrous epulis in an 11 year old girl.
4. International journal of clinical and medical imaging.
5. Fibrous epulis experiences in clinical presentation and treatment of 39 cases, *J Natl Med Association*, 1978 May 70 (5), 317-319.
6. Leyden, J.L. and Mastin G.H. 1973. Oral cavity pyogenic granuloma, *Arch dermatology*, 108:226-228.
7. Fibrous epulis associated with impacted lower right third molars – *Dental Journal*, Volume 42, no.4, October – December 2009.
8. Oral pyogenic granuloma - *A review, Journal of Oral Science*, Volume 48, no.4,167-175,2006.
9. Clinical outline of oral pathology, 4th edition – Louis. R. Eversole.
10. Oral pathology and clinical pathology correlation– Joseph. A.Regezzi, James.J.Sciubba.
11. Pyogenic granuloma – hyperplastic lesion of gingival – case reports. *The open dentistry Journals*, 2012, 6,153-156.
