



RESEARCH ARTICLE

BILATERAL UDT PRESENTING AS INTRA ABDOMINAL NSGCT IN ADULT FERTILE MALE

***Abhay Desai and Dr. Amit Mandhare**

General and Cancer Surgeon, B K L Walawalkar Hospital and Rural Medical College, Dervan, Taluka Chiplun.
District Ranagiri, Maharashtra 415606, India

ARTICLE INFO

Article History:

Received 19th October, 2017
Received in revised form
05th November, 2017
Accepted 21st December, 2017
Published online 19th January, 2018

Key words:

Cryptorchidism,
Undescended Testis (UDT),
Infertility, Testicular Germ Cell tumor
(TGCT), Non Seminomatous Germ Cell
Tumor (NSGCT).

ABSTRACT

The failure of testicular descent or cryptorchidism is the most common defect in newborn boys. It often escapes attention of health workers & parents who probably notice it but fail to seek timely advice. We report a case of Bilateral undescended testis presenting as intra abdominal tumor a NSGCT in an adult fertile male. He was investigated, Tumor removed and referred for Chemotherapy. The case also establishes need for proper clinical examination while examining a case of intra abdominal lump.

Copyright © 2018, Abhay Desai. This is an open access article distributed under the Creative Commons Attribution License, which permits unrestricted use, distribution, and reproduction in any medium, provided the original work is properly cited.

Citation: Abhay Desai. 2018. "Bilateral udt presenting as intra abdominal nsget in adult fertile male", *International Journal of Current Research*, 10, (01), 63960-63962.

INTRODUCTION

UDT are found in 1 pc boys at the age of 1-year old, 3% of full-term male infants and 33% in premature babies at birth. Spontaneous descent is possible until 6 months of age. Clinical examination finds that 80% of UDT are palpable and sit in the inguinal superficial pouch (30%), the inguinal canal (20%), the upper scrotum (45%) and rarely (5%) the perineum or the thigh and that 20% of UDT are non-palpable and sit in the abdominal cavity. Cases of Bilateral not palpable testis with genital abnormalities like hypospadias and micropenis will require genetic and endocrine assessment. For others laparoscopy is mandatory to look for intra abdominal testis (Pierre, 2008). Cryptorchidism is an established risk factor for Infertility and Testicular Germ Cell Tumors (TGCT). The most common type of TGCT in cryptorchid testis is Seminoma (Lydia Ferguson, 2013). This case is unusual & rare; bilateral cryptorchidism in a fertile male presenting as Intra abdominal NSGCT.

Case Report

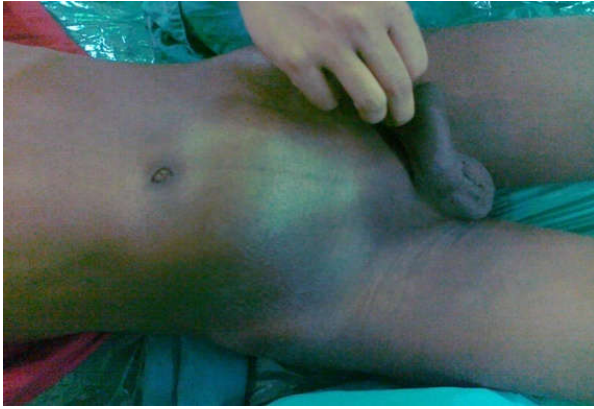34 year old male with one 4 year old child presented with large suprapubic mass extending above umbilicus (Figure 1a).

***Corresponding author: Abhay Desai**
India.

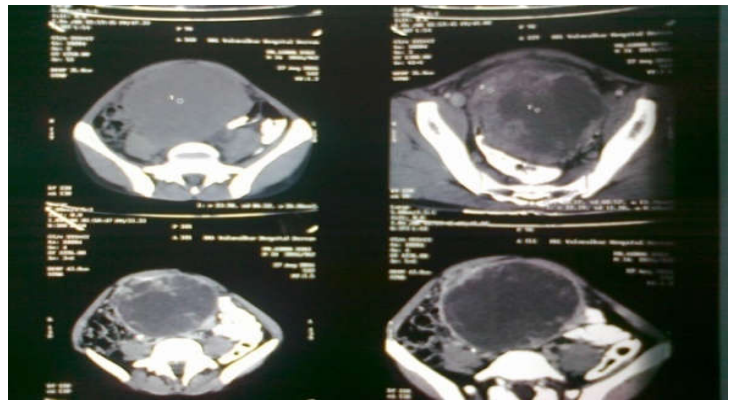
His scrotum was empty. His secondary sexual characteristics were normal. CT Scan (Figure 1b) demonstrates heterogeneous tumor arising out of Pelvis. AFP 314, beta HCG 5.2, LDH 1757. Surgery: No Biopsy is required with the availability of imaging and Tumor markers and high Orchiectomy is indicated. In this case it was Laparotomy and excision of tumor along with adherent omentum and loop of sigmoid. Spermatic cord located & divided between ligatures near internal ring. End to end anastomosis done. (Figure 2b) Right sided Normal looking testis noted intra abdominally above deep ring and decision as to whether to remove it or bring it down was deferred for later. (Figure 2a). Histo-pathological Report: 14/13/9 cm growth with large areas of necrosis & Hemorrhage. Adherent omentum involved. Sigmoid involved up to sub mucosa. Germ cell tumor. Yolk sac tumor. He was referred for Chemotherapy.

DISCUSSION

The complications associated with UDT: atrophy & Necrosis are found in 3% of non operated UDT. Trauma & Torsion of UDT are classically more common as the testicular attachments of UDT are looser than in normally descended testis (Pierre, 2008). Clinical presentations of malignant intra abdominal testis can range from an asymptomatic mass to symptoms stimulating appendicitis or retroperitoneal mass, incarcerated hernia, urinary frequency or dysuria from mass

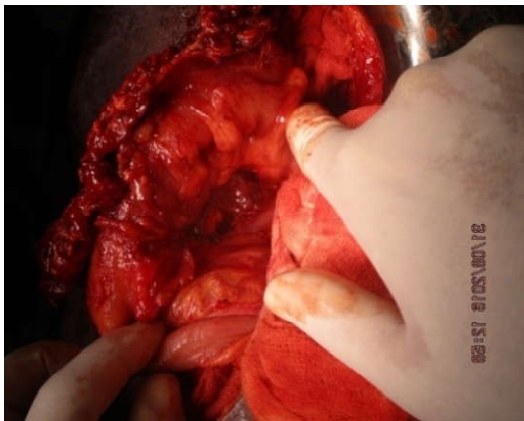


a. Abdominal Lump & Empty Scrotum

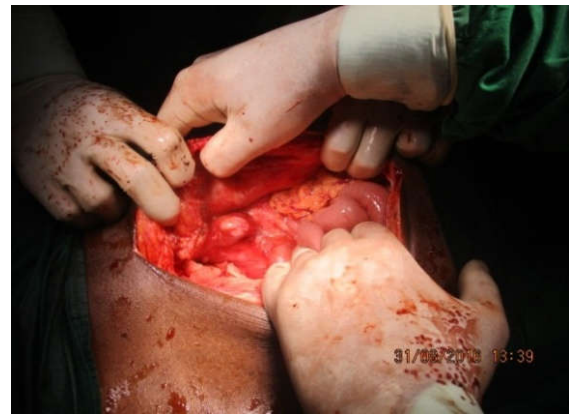

b. CT Scan Heterogeneous tumor

Figure 1



a. Sigmoid colon involvement



b. Normal Right Testis at Internal ring

Figure 2

effect on bladder or acute abdominal pain due to torsion or hemorrhage (Sajjad Hussain, 2015) Infertility & Malignancy are the others as discussed below:

Malignancy Risk

Testicular cancer afflicts 1% of the male population and is the most common solid tumor to affect young males between the age of 15-34. No age is immune and it can occur in infants as well as elderly men. Very little is known about the mechanism of TGCT tumorigenesis and at present there is no animal model that develops testicular cancer as a result of an UDT phenotype (Lydia Ferguson, 2013). The cancer risk of ectopic testis is 40 times higher in a normal testis. Furthermore, an abdominal testis is four times more likely to undergo malignant degeneration than an inguinal testis. The cancer of UDT usually peaks in the third or fourth decade of life (Dr. Govind K Purushothaman, 2013). Persistently cryptorchid testis are at higher risk for Seminoma (74%). While corrected cryptorchid or scrotal testis testicles that undergo malignant transformation are most likely to become Nonseminomatous (63%, $p < 0.0001$), presumably because of decreased risk of Seminoma. Patients who undergo orchiopexy after age 12 years or no orchiopexy are 2 to 6 times as likely to have testicular cancer as those who undergo prepubertal orchiopexy (Wood, 2009).

Infertility risk

Impairment of germ cell maturation and subsequent infertility in adulthood are well-recognized consequences of

cryptorchidism. General population the incidence of Azoospermia is about 0.5 %. The incidence of azoospermia in unilateral cryptorchidism is 13% and this figure increases to 89% in untreated bilateral cryptorchidism, making cryptorchidism the most common etiologic factor of azoospermia in the adult (Eric Chung, 2011). How far Orchiopexy corrects the condition is uncertain.

Conclusion

There is still a lack of awareness among people and also lacunae in Health services that such cases go undetected and present at such late stage. Once detected argument for early Orchiopexy is reducing the risk of testicular cancer by half though it is still higher compared to general population. It does lend to earlier detection. Cases of testicular cancer are rare and those that present as abdominal NSGCT are even rarer. Patient often would not divulge important history points and it is important for clinician to carry out complete clinical examination.

REFERENCES

- Dr. Govind K Purushothaman, Dr. Shailendra Kumar *et al.* 2013. Rare Presentation of Intra-Abdominal Testicular Mass: A Case Report ;*International Journal of Science and Research (IJSR)* ISSN (Online): 2319-7064 Index Copernicus Value 6.14 | Impact Factor (2014): 5.611 Vocan Clume 4 Issue 12, December 2015.

- Eric Chung, Gerald B. Brock. 2011. Cryptorchidism and its impact on male fertility: a state of art review of current literature. *Can Urol Assoc J.*, Jun; 5 (3): 210-214
- Lydia Ferguson, Alexander I. Agoulnik; 2013. Testicular Cancer and Cryptorchidism. *Front Endocrinol (Lausanne)* 2013; 4: 32. Published online Mar 20. Doi: 10.3389/fen do 2013 00032.
- Pierre, D. E. Mouriquand, 2008. Undescended testes in children: the paediatric urologist's point of view; *European Journal of Endocrinology*, 159 S83–S86.
- Sajjad Hussain; 2015. Torsion of Giant Intra abdominal Testicular Seminoma Presenting as Acute Abdomen. *Indian Journal Surg.* April; 77 (Suppl 1) 64-65.
- Wood, H.M., Elder, J.S. (Feb 2009) Cryptorchidism and Testicular Cancer: separating the fact from fiction. *The Journal of Urology*: 181(2): 452-61.
