



ISSN: 0975-833X

Available online at <http://www.journalcra.com>

International Journal of Current Research
Vol. 11, Issue, 03, pp.2112-2113, March, 2019

DOI: <https://doi.org/10.24941/ijcr.34672.03.2019>

INTERNATIONAL JOURNAL
OF CURRENT RESEARCH

CASE REPORT

VESTIBULAR DEEPENING PROCEDURE WITH CONTINUOUS LOCKING SUTURE: A CASE REPORT

*Priya Malhotra, Vipin Bharti, Harmesh Sharma, Deepak Kajla, Sumanjit Kaur and Ketouelhhou Vizo

Department of Periodontology, Government Dental College and Hospital, Patiala, India

ARTICLE INFO

Article History:

Received 28th December, 2018

Received in revised form

20th January, 2019

Accepted 17th February, 2019

Published online 31st March, 2019

Key Words:

Vestibular deepening, Width of attached gingival, Continuous locking suture.

ABSTRACT

Shallow vestibule along with inadequate width of attached gingiva is a common cause of gingival recession especially in mandibular anterior region. Vestibular deepening procedures have always been a point of concern for the Periodontist. Multiple techniques have been developed to increase the vestibular depth. This case report presents a vestibular deepening procedure with continuous locking suture.

*Corresponding author: Priya Malhotra

Copyright©2019, Priya Malhotra et al. This is an open access article distributed under the Creative Commons Attribution License, which permits unrestricted use, distribution, and reproduction in any medium, provided the original work is properly cited.

Citation: Priya Malhotra, Vipin Bharti, Harmesh Sharma, Deepak Kajla, Sumanjit Kaur and Ketouelhhou Vizo, 2019. "Vestibular deepening procedure with continuous locking suture: A Case Report", *International Journal of Current Research*, 11, (03), 2112-2113.

INTRODUCTION

Periodontal plastic surgery not only emphasizes on biological and functional problems that affect the periodontium but also focuses to improve the esthetic appearance. Gingival recession is defined as the exposure of the root surface by the apical migration of the junctional epithelium, resulting in an unaesthetic appearance, hypersensitivity and root caries (Kassab and Cohen, 2003). Aberrant frenum along with inadequate vestibular depth causing gingival recession is a common clinical finding in the front region of the lower jaw. The shallow vestibule was one of the three original mucogingival problems cited by Friedman in the late 1950's that required the increased apicocoronal dimension of the gingiva. Shallow vestibular depth leads to food impaction against the gingival margin and into the interproximal area and usually interferes with the oral hygiene procedure causing ineffective plaque control (Goldman, 1953). The term mucogingival surgery was introduced by Friedman and Levin in 1957 to describe the surgical procedure that correct the relationship between the gingiva and oral mucous membrane such as attached gingiva, shallow vestibule and aberrant frenum. Several independent and effective surgical procedures have been developed for the management of shallow vestibule (Freidman, 1957). The aim of this vestibular extension procedure is to have healing by secondary intention by giving sutures which does not allow both the edges of the epithelium to come in contact during the process of healing.

Basis of the innovation: This new technique is derived from the Pterygoplasty surgery in which pterygium is detached and its direction is changed towards the lower eyelid. The nature of

the epithelial cells is to proliferate and crawl to adapt the wound bed giving cover for the new tissue. The basis of this new technique is not to allow epithelial cells to migrate till the secondary intention healing takes place.

CASE REPORT

A 22 year old female reported to the Department of Periodontics, Government Dental College, Patiala with the chief complaint of receding gums of her lower front tooth. Intraoral examination revealed Miller's Class II gingival recession with some mobility wrt 41 (Figure 1) due to shallow vestibular depth and inadequate width of attached gingiva. Hence, to prevent the progression of gingival recession and to increase the width of attached gingiva, vestibular deepening procedure was planned. The patient was informed about the procedure and an informed consent was signed by the patient. Before surgery, thorough scaling and root planing was done. Two weeks after Phase I therapy, the patient was prepared for surgical procedure.

Surgical procedure: At the time of surgery, local anaesthesia was administered and a horizontal incision was given with 15 no. B.P. blade at the mucogingival junction (Figure 2). A partial thickness flap was reflected towards the alveolar mucosa along with dissection of the muscle fibres. The flap was undermined to change the direction of the epithelium inwards and then undermined flap was sutured with continuous locking sutures (Figure 3). The operated area was then covered with periodontal pack (Figure 4). Suturing and periodontal pack were removed after 14 days of surgical procedure. Healing was satisfactory with secondary wound closure and adequate

vestibular depth and width of attached gingiva was obtained. No post operative complications and signs of relapse were seen after 6 months (Figure 5).

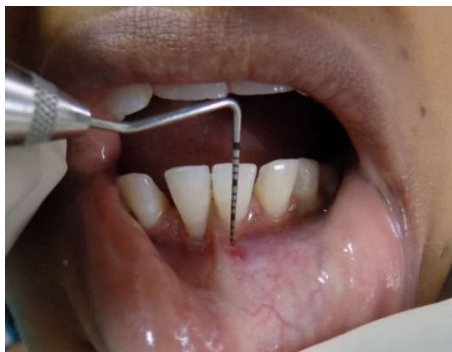

Figure 1. Preoperative view

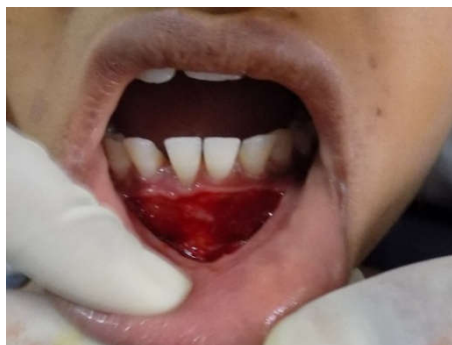

Figure 2. Horizontal incision placed

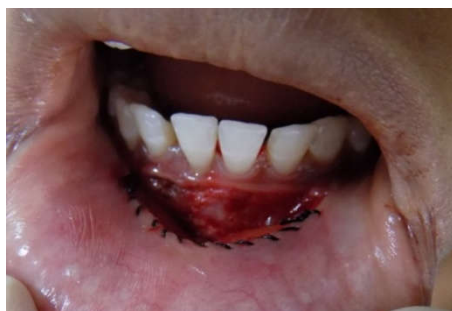

Figure 3. Flap undermined and sutured with continuous Locking suture

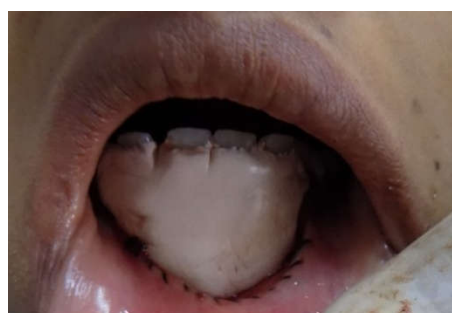

Figure 4. Periodontal pack placed

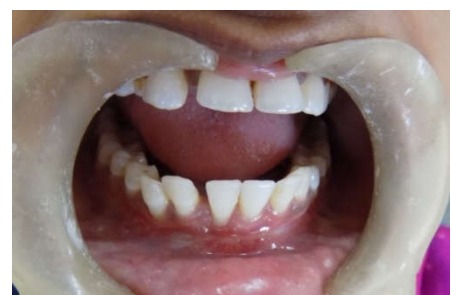


Figure 5. postoperative view

DISCUSSION

Gingival recession and shallow vestibule may occur without any symptoms but this may cause unaesthetic appearance, difficulty to perform plaque control procedures, dentinal hypersensitivity etc. Several studies indicated that the role of adequate vestibular depth is very important. Wennstrom and Prini Prato reported that the combination of the shallow vestibule and inadequate width of attached gingiva might favour the food accumulation during mastication and difficulty to maintain oral hygiene (Wennstrom, 2003). Wade also reported that before root coverage procedures, adequate width of attached gingiva is a common requirement (Wade, 1969). Goldman was the first to introduce the rationale and techniques of emerging field of mucogingival surgery in 1956 (Goldman *et al.*, 1956). The technique to deepen the vestibule in edentulous patient was primarily introduced in 1924 by Kazanjian (Kazanjian, 1924). The Schlugar "pouch" and the Fox "push back" procedures previously known only through personal communication were formally introduced into the literature and renamed the "local extension of the vestibular trough" and the "gingival extension operation" respectively. Several other techniques have been developed but most of them are unsatisfactory due to scar formation and frequent relapse of the state of the vestibule and all these techniques expose the extensive areas of the bone (Bohannon, 1962; Bohannon, 1962). The conventional procedure of deepening the vestibule is a successful procedure and literature shows it is an excellent procedure for gaining the width of the attached gingiva. In the present case report, the epithelium from the buccal side of the flap is sutured using continuous locking technique which guides the re-attachment of the epithelium thus causing healing by secondary intention.

Conclusion

The combination of conventional vestibular deepening and continuous suturing method has led to an innovation in the field of Periodontal Plastic surgery and is a successful procedure for gaining the depth of the vestibule and width of attached gingiva and to prevent progression of gingival recession.

REFERENCES

- Bohannon HM. 1962. Studies in the alteration of vestibular depth : I. Complete denudation. *J Periodontol.*, 33:120.
- Bohannon HM. 1962. Studies in the alteration of vestibular depth: II. Periosteum retention. *J Periodontol.*, 33:354.
- Freidman N. and Levin HL. 1957. Mucogingival surgery. *Tex Dent J.*, 75:358.
- Goldman HM Periodontia, 1953. In 3rd ed St. Louis C V Mosby Co., p.552-61.
- Goldman HM, Schluger S, Fox L. 1956. Periodontal Therapy. St. Louis CV. Mosby Co.:1956.p.301-11.
- Kassab MM, Cohen RE. 2003. The etiology and prevalence of gingival recession. *J Am Dent Assoc.*, 134:220-5.
- Kazanjian VH. 1924. Surgical operations as related to satisfactory dentures. *Dent Cosm.*, 66:387.
- Wade AB. 1969. Vestibular deepening by the technique of Edlan and Mejchar. *J Periodontal Res.*, 4:300-13.
- Wennstrom J, PiniPrato GP. 2003. Mucogingival therapy periodontal plastic surgery In: Lindhe J, Karring T, Lang N. Clinical Periodontology and Implant Dentistry. 4th ed. Copenhagen Blackwell Munksgaard, p. 576-650.