



ISSN: 0975-833X

Available online at <http://www.journalcra.com>

International Journal of Current Research
Vol. 11, Issue, 03, pp.2528-2530, March, 2019

DOI: <https://doi.org/10.24941/ijcr.34829.03.2019>

**INTERNATIONAL JOURNAL
OF CURRENT RESEARCH**

CASE STUDY

STOMAL MYIASIS – A RARE CASE OF MUCOCUTANEOUS INFESTATION

*Ashish Vora, Ekta Yadav, Himanshu Agrawal, Siddharth Desai and Mayank Mathur

PGIMER & Dr. Rml Hospital, New Delhi, India

ARTICLE INFO

Article History:

Received 26th December, 2018

Received in revised form

20th January, 2019

Accepted 08th February, 2019

Published online 31st March, 2019

Key Words:

Maggot's, Myiasis, Adenocarcinoma ano-Rectum, Abdomino-perineal resection (APR), Colostomy.

Copyright ©2019, Ashish Vora et al. This is an open access article distributed under the Creative Commons Attribution License, which permits unrestricted use, distribution, and reproduction in any medium, provided the original work is properly cited.

Citation: Ashish Vora, Ekta Yadav, Himanshu Agrawal, Siddharth Desai and Mayank Mathur, 2019. "Stomal myiasis – A rare case of Mucocutaneous infestation", *International Journal of Current Research*, 11, (03), 2528-2530.

INTRODUCTION

Living with a colostomy is still a taboo. An ostomate may develop complications like parastomal hernia, stomal stenosis, necrosis, retraction, skin irritation or rare complications like prolapse, perforation, fistula, dehydration etc. Colostomy care is sometimes neglected by the patient and relatives in developing countries. In contrast to other sites with open surface stomal infestation of maggots is an uncommon finding (Mahjoubi *et al.*, 1989). Myiasis comes from the Greek term "myia" meaning fly, first introduced by Hope (Hope, 1840) in 1840. This phrase is used to define the infestation of human and vertebrate hosts by larval stages of dipterous flies, usually known as maggots. Infestation may affect the skin, wounds, intestines and body cavities (oral, nasal, aural, ocular, etcetra). Members of the Diptera family consist of Gasterophylidae, Sarcophagidae, Oestridae, Hypodermatidae, Calliphoridae, Glossinidae and Muscidae. All these have been positively implicated in causing enteric myiasis. These are mostly oviparous, while a limited number may be viviparous. Intestinal myiasis is usually an accidental phenomenon which is transient and asymptomatic and may be excreted in feces (Herms and James, 1961). Myiasis can cause massive destruction in neglected patients accompanied by marked inflammatory reactions and secondary bacterial infections.

Case Presentation: A 44 year old male presented with complaints of discomfort and pain around the site of the colostomy.

*Corresponding author: Ashish Vora

PGIMER & Dr. Rml Hospital, New Delhi, India.

ABSTRACT

Infestation of Maggot's around colostomy is an uncommon finding. Common sites include nose, ear, orbit, tracheostomy wound, face, gums and serous cavities. We report a case of myiasis in post-operative patient of adenocarcinoma ano-rectum with abdomino-perineal resection (APR) and end colostomy.

He was a follow up case of moderately differentiated adenocarcinoma of the ano-rectum (T3 N1 Mx) and underwent APR with creation of end colostomy. He complained of foul smelling discharge, skin irritation and sensation of something crawling, at around colostomy site. On general examination mild pallor was present with poor personal hygiene. Routine blood investigations revealed anemia and leucocytosis and biochemical and serological tests were normal. Per abdomen examination revealed soft abdomen with end colostomy in the left iliac region. Local examination revealed functioning colostomy with healthy mucosa. The parastomal skin and subcutaneous tissues were inflamed with thick whitish flakes of pus on the surrounding skin. On gentle exploration with forceps, numerous creeping maggots were found (Fig.1.a.). Maggots were dull white in color, 7-8 mm in length with both the ends tapering. This was managed by application of turpentine oil as a repellent for maggots followed by gentle removal (Fig.1.b.) and patient was started on antibiotics and maggots were removed in the following 2-3 days till no larvae were seen. Patient was given two piece stoma bag with snugly fitting base plate to compensate for parastomal tissue loss and was discharged uneventfully after 5 days.

DISCUSSION

German entomologist Fritz Zumpt describes myiasis as "the infestation of live human and vertebrate animals with dipterous larvae, which at least for a period, feed on the host's dead or living tissue, liquid body substances or ingested food. Intestinal myiasis is usually an accidental phenomenon (Zumpt, 1967; Aguilera *et al.*, 1999).

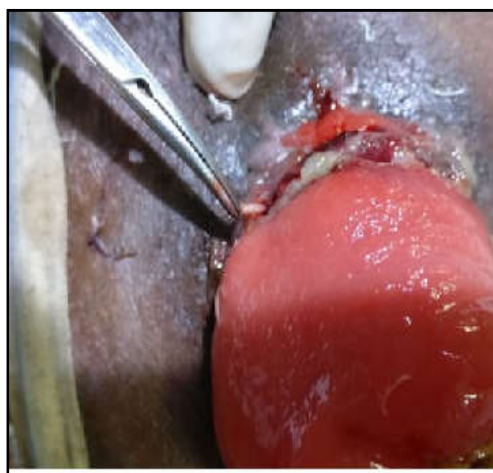
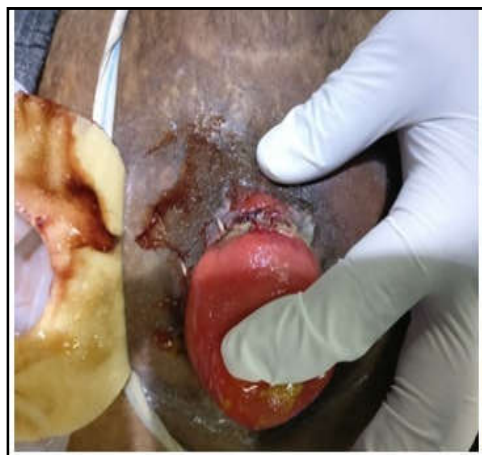


Fig. 1. (a) Multiple creeping maggots seen at the periphery of the colostomy. (b) Post turpentine-oil application extraction of maggots

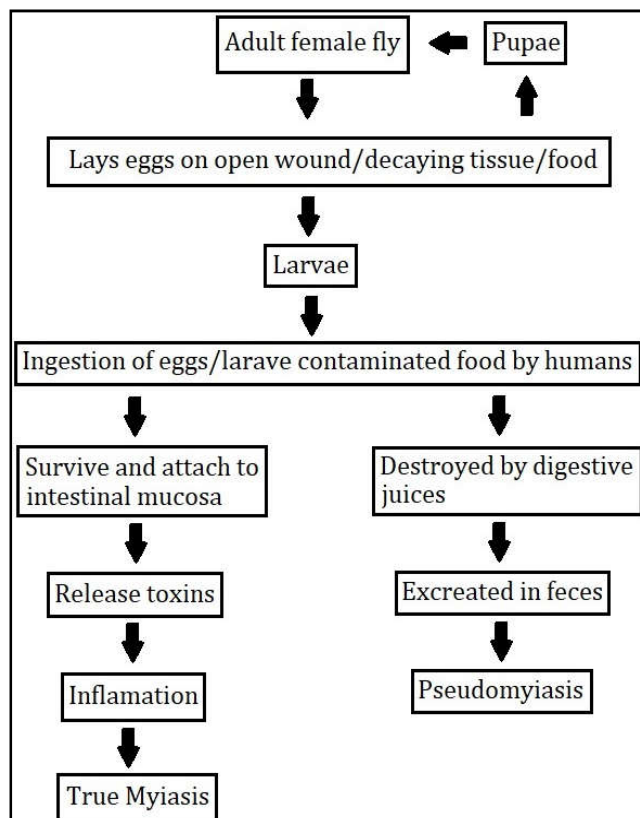


Fig. 2. Pathogenesis of myiasis

Classification of myiasis

- According to part of the host involved
- Dermal
- Sub dermal
- Cutaneous
- Arterial
- Nasopharyngeal
- Ocular
- Auricular
- Intestinal
- Gastric
- Urogenital

According to relationship between the host and the parasite: (Zumt, 1967; Aguilera et al., 1999)

- Obligatory- where the parasite cannot complete its life cycle without its parasitic phase, which may be specific, semispecific or opportunistic.
- Facultative or accidental- when it is not essential to complete the life cycle of the parasite in the host and perhaps a normally free-living larva accidentally gains entrance to the host.

Myiasis is common in countries where nutritional and sanitary conditions are very poor (fig. 2). More than 50 fly species have been reported out of which *Eristalis tenax* (rat tailed maggots) is the most common species involved in intestinal myiasis and has a worldwide distribution, while *Musca domestica* (house fly) common in India (Shivekar et al., 2008; Bhatia, 1989; Sehgal et al., 2002). Clinical symptoms are variable ranging from asymptomatic cases to symptoms like local pain, discharge, fever, pruritis or bleeding.

Management

- General measures improving the nutrition, correction of anemia, psychological support and local hygiene.
- Local measures involves usage of antilarval measures (turpentine oil or mixture of turpentine oil and chloroform) followed by removal of the larvae without rupture the maggots because they may cause secondary infections or trigger potentially severe allergic reactions. A broad spectrum antibiotic to prevent secondary infections.
- Preventive measures including washing, adequate cooking and proper storage of food/vegetables/fruits before consumption.

Conclusion

Though maggots insurgence is not considered to be a threat to colostomy site but in country like India where the flies population and hygiene is an issue it is better to counsel an ostomate about it and in a case of colostomy presenting with local pain and discomfort it must be considered.

REFERENCES

Aguilera, A., Cid, A., Regueiro, BJ., Prieto, JM. and Noya, M. 1999. Intestinal myiasis caused by *Eristalis tenax*. J Clin Microbiol., 37:3082.

- Bhatia, RS. 1989. Accidental intestinal myiasis. *J Assoc Physicians India.*, 37:403-5.
- Herms, WB. And James, MT. 1961. Myiasis, *Medical Entomology*, 5th ed. New York: Macmillan Company; p. 362-95.
- Hope, FW. 1840. On insects and their larvae occasionally found in the human body. *Transactions of the Royal Society of Entomological*, 2:256-71.
- Mahjoubi, B., Moghimi, A., Mirzaei, R. and Bijari, A. 1989. Evaluation of the end colostomy complications and the risk factors influencing them in Iranian patients. *Colorectal Dis.* 2005 Nov; 7(6):582-7.) Anil S, Jacob OA, Hari S. Oral myiasis: A case report. *Ann Dent.*, 48:28-30.
- Sehgal, R., Bhatti, HP., Bhasin, DK., Sood, AK., Nada, R., Malla, N., *et al.*, 2002. Intestinal myiasis due to *Musca domestica*: A report of two cases. *Jpn J Infect Dis.*, 55:191-3.
- Shivekar, S., Senthil, K., Srinivasan, R., Sureshbabu, L., Chand, P., Shanmugam, J., *et al.*, 2008. Intestinal myiasis caused by *Muscina stabulans*. *Indian J Med Microbiol.*, 26:83-5.
- Zumpt, F. 1967. Myiasis in man and animals in the old world. A textbook for physicians, veterinarians and zoologists. London: Butterworth;
