



LEFT VENTRICULAR LEAD STABILIZATION IN CORONARY SINUS VIA STENT CASE REPORT AND LITERATURE REVIEW

Osama Abdelkarim Alshoubaki,* Ziad khalef Aldarabaa, Ashraf Hatem Qubbaj, Ramzi abdelmajid Alhyari, Laith Saed Obiadat and Yazan Bani Hamad

Queen Alia Heart Institute, Amman, Jordan.

ARTICLE INFO

Article History:

Received 19th February, 2021
Received in revised form
24th March, 2021
Accepted 25th April, 2021
Published online 28th May, 2021

Key Words

Cardiac Resynchronization,
LV lead Stent,
Coronary Sinus Stent,
Case Report, Literature Review.

ABSTRACT

Background: Left ventricular lead instability encounters some cardiac resynchronization therapy implantations affecting heart failure patient's responsiveness. We present a left ventricular lead stabilization in the coronary sinus via a drug-eluting stent in addition to the literature review of this technique. **Methods:** A 33-year-old male patient had advanced heart failure and implanted cardiac resynchronization therapy. Left ventricular lead dislocation mandated redo-implantation. Lead instability complicated the procedure until a drug-eluting stent anchored it in the posterolateral branch of the coronary sinus. Furthermore, we reviewed the literature to address all studies and reports of left ventricular lead stabilization via coronary stent in the coronary sinus during cardiac resynchronization therapy implantation. We explored words as left ventricular lead stabilization, lead stenting, coronary sinus stent, coronary sinus angioplasty. **Results:** A total of 14 studies spotted left ventricular lead stenting in the coronary sinus during biventricular pacing between 2000 and 2021; four observational studies: three case series: seven case reports. The studies included 400 patients, and mean follow-up was 20 months. Stenting the lead during the primary procedure (n=368) versus stenting in the redo procedure (n=32). Stenting for lead instability and phrenic nerve stimulation (n=374), whereas stenting due to unfavorable anatomy (n=26). Most patients received a bare-metal stent (n=396), a drug-eluting stent (n=2), and a bioabsorbable scaffold (n=2). Overall reported stenting the left ventricular lead since the first procedure description in years 2003 to 2011 was 390 stents and between the years 2012–2021 was ten stents. **Conclusion:** During cardiac synchronization therapy implantation, left ventricular lead retention in the coronary sinus by stent is feasible and effective.

Copyright © 2021. Osama Abdelkarim Alshoubaki et al. This is an open access article distributed under the Creative Commons Attribution License, which permits unrestricted use, distribution, and reproduction in any medium, provided the original work is properly cited.

Citation: Osama Abdelkarim Alshoubaki,* Ziad khalef Aldarabaa, Ashraf Hatem Qubbaj, Ramzi abdelmajid Alhyari, Laith Saed Obiadat and Yazan Bani Hamad. "Left ventricular lead stabilization in coronary sinus via stent. case report and literature review.", 2021. International Journal of Current Research, 13, (05), 17450-17454.

INTRODUCTION

Cardiac resynchronization therapy (CRT) with optimal medical therapy is the mainstay approach in treating advanced heart failure (1,2). Complete implantation of left ventricular (LV) lead in the coronary sinus (CS) vein is still the preferable technique in CRT and can be accomplished in 90% of implantations (2,3).

When trans-coronary sinus LV lead implantation is unfeasible due to access, recurrent dislodgement, or phrenic nerve stimulation (PNS), different techniques were described to implant LV lead as vein angioplasty and stabilize the lead by stenting (4,5), anchor balloon (4), or using gooseneck snare (6), transeptal endocardial LV lead implantation (7), use active fixation leads in CS (8,9), epicardial implantation of the lead is another technique in case of unattainable transvenous approach (10–12). Wireless LV pacing and His-bundle pacing are new and growing alternatives for conventional CRT implantation (13,14). In 2003, Van Gelder BM et al. reported the first case of LV lead emplacement using angioplasty and stenting of the occluded branch to reimplant the lead (5). In the 27th Congress of the European-Society-of-Cardiology, Gellér L et al. were the first to describe the possibility of CS side-branch stenting as a tool for stabilization of LV lead (15).

*Corresponding author: Osama Abdelkarim Alshoubaki,
Queen Alia Heart Institute, Amman, Jordan.

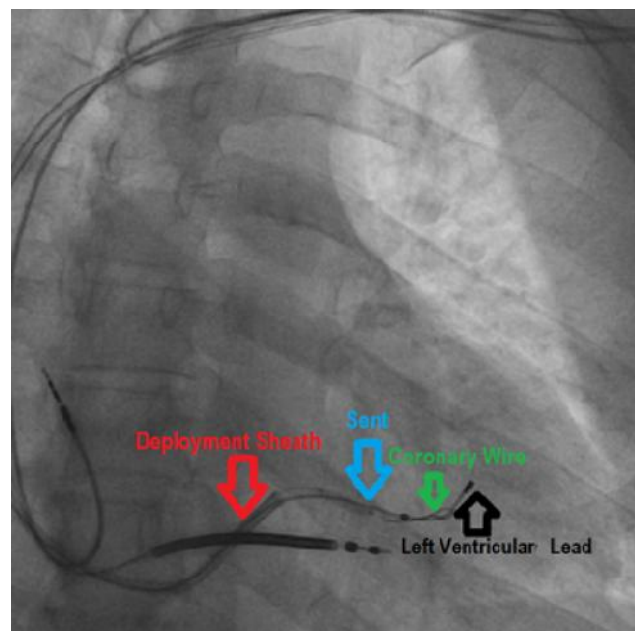
Maintaining LV lead at its intended site by stenting permits satisfactory pacing parameters, minimizing PNS, and reimplanting procedures (16,17). This study is the first literature review of anchoring the LV lead in CS by stent between 2003 till 2021.

METHODS

Case presentation: Our case is a 33-year-male with symptomatic severely dilated cardiomyopathy who had cardiac resynchronization therapy defibrillator (CRT-D). The Ejection Fraction <20 and Left Bundle Branch Block QRS duration was 156ms on the cardiac electrocardiogram. After two weeks, device interrogation revealed a high threshold and right ventricle capture. Fluoroscopy confirmed LV lead dislodgement outside the CS. Subsequently, we scheduled him for revision. In the reimplantation procedure, vancomycin was given. The patient was draped on with aseptic technique, and 30ml of 2% xylocaine was infiltrated into the implantation field.

We explanted LV lead smoothly over extra support wire. The first difficulty was re-accessing the CS by a deflectable catheter delivery system (attain.6227DEF, Medtronic) due to severe subclavian vein stenosis despite multiple stenotic dilations. Anyhow, we only accessed by a deeper puncture and cannulating the CS by using delivery integrated valve sheath (attain command + surevalve) and decapolar coronary catheter. CS venogram showed only one suitable posterolateral branch (PLV) approximately 2.5 mm in diameter. The second difficulty was pumping the lead (Attain Ability™ MRI SureScan™ 4196, Medtronic, Minneapolis, MN, USA) out of the CS immediately. Finally, after three trials of unsuccessful reimplantation, we decided to stabilize the lead in PLV via a coronary stent. Using the same delivery sheath, we wired the vein by CHOICE PT Floppy wire (H749 12132-01J 2, BOSTON SCIENTIFIC).

The drug-eluting stent (XienceXpedition, everolimus-eluting stent 2.75x12 mm, Abbott Vascular, Santa Clara, LA USA) passed through the surevalve over the wire. Then, we dragged the lead to the possible proximal PLV part where there was no diaphragmatic pacing, which we encountered before, and the threshold was less than one millivolt, impedance was 755ohm. The stent was positioned proximal to the distal lead end and then deployed at low pressure (10 atmospheric pressure) (Figure 1). After removing the balloon and wire, we tugged the lead for stability. Then, the attain sheath peeled successfully without affecting the lead position and parameters (figure 2). After confirming lead stability, it connected to the generator, and the wound was closed. The total procedure time was 185 min, all tools used in this procedure were based on availability in our catheterization laboratory. We discharged the patient on dual antiplatelets for three months. The short and long-term follow-ups showed a super device responder with a smooth healing course and stable lead parameters. With the literature search in PubMed, Wiley Online Library, and Google Scholar, we sorted out all published studies and reports that addressed the retention of LV lead via coronary stent in CS branches during CRT implantation between the years 2000–2021. Data subcategorized as study type, the chronology of the studies, patient numbers, patient demography, indication, procedure, results, follow-ups, and conclusions.



Red arrow: The delivery integrated valve sheath.

Blue arrow: The drug-eluting stent.

Green arrow: Coronary wire.

Black arrow: left ventricular lead.

Figure 1. Shows the right anterior oblique view of stent deployment in the posterolateral branch of the coronary sinus over the left ventricular lead through the sheath.

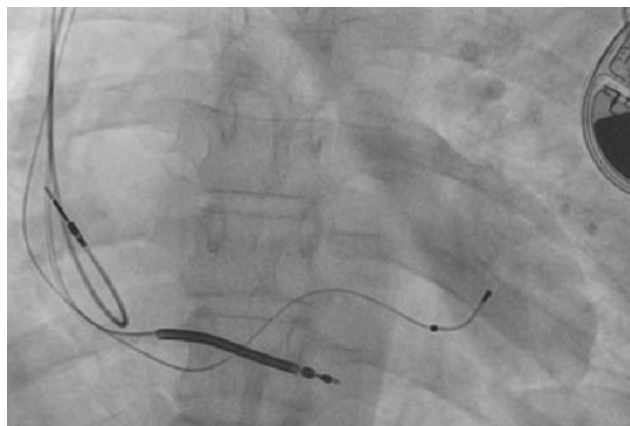


Figure 2 . Shows the right anterior oblique view of the stable left ventricular lead after peeling the sheath.

Words like left ventricular lead stabilization, left ventricular lead stent, coronary sinus stent, coronary sinus angioplasty were browsed.

RESULTS

With the aid of electronic search between the years 2000–2021, 14 studies were found concerning LV lead entrapment in CS by stenting: four observational studies(16–19): three case series(20–22): seven case reports(23–29). The studies included 400 patients, 74% male, mean age was 63.2 years, and mean follow-up was 20 months (range: 1–30 months). The LV lead stenting declined over the last decade or maybe under-reported. The percentage of deployed stents to stabilize the LV lead since the first procedure described in the years 2003 to 2011 was 97.5% (stents no=390), and it dropped between the years 2012-2021 to 2.5% (stents no=10). Greatest stents used were bare-metal stents (n=396), a drug-eluting stent (n=2), and

a bioabsorbable scaffold (n=2). The most common indications for lead stenting were lead instability and PNS (n=374, 93.5%), where stenting due to unfavorable anatomy (n=26, 6.5% of the cases). All patients had bipolar leads, except for two who had quadripolar leads. The 349 patients of the four observational studies underwent ad hoc lead stenting because of PNS, anatomy obstacles, or in-procedure dislodgement. Minor sequences were seen during a mean follow-up of 23 (range: 11–30) months, such as micro-lead dislocation (n=2), perforation (n=1), later PNS (n=18), only seven of them required reposition, lead dislocation (n=2) and lead extraction (n=8), which was uneventful. No stent-related mortality was registered.

DISCUSSION

Ideally, the pacing of the mid-lateral wall of the LV through the lateral and PLV of the CS in cardiomyopathy causes enhancements in functional capacity and LV function(30–32). Anyhow, large PLV present in only 68% of hearts(31). The size and distribution of the CS branches differ widely; large branches in heavier hearts or severely dilated cardiomyopathy (33,34). Where small or absent in ischemic cardiomyopathy (35). Even with the availability of PLV, implanters still confront several difficulties such as lead instability and PNS during CRT implantation because of the anatomical and the electrical disparity in these patients (36–39). Diaphragmatic stimulation occurs in up to 37% of CRT implantations and switches off 5% of the device (3,36,40). The left phrenic nerve crosses the mid-region of left marginal veins in 53.3% (41). Leaving the preferred area for LV lead implantation (the marginal and posterior veins) is in jeopardy of PNS (42). The first-year incidence of LV lead dislodgement after cardiac resynchronization therapy implantation occurs in about 10.6% of the patient (43). LV lead instability is due to lead or anatomical-related factors. Lead-related factors owed to unsuitable lead slack, the discrepancy between the lead and vein diameters, and the way of attachment inside the chosen vein (44). On the other hand, the anatomical obstacles of CS are ostium orientation or obstruction, venous valves, vein direction and angulation, vein deformity caused by cardiac dilation, and anomalies (45–47). In this review, 93.5% (n=374/400) of the leads stabilized by stent were due to lead instability and PNS, where stenting based on unfavorable anatomy was 6.5%.

The non-uniform circumferential stress of the stent and the vessel wall grabbed the lead between the stent and the partially embedded veins in the myocardium (48). As well, shear stress is caused by parallel friction of the lead against the vein wall and the stent (49). LV lead stabilization by stent was applied in some centers commonly. For instance, the Semmelweis University group (Hungary, 2004–2009) and the University of Bologna group (Italy, 2009–2010) stented 39.7% and 30% of CRT patients, respectively. 97.5% of stents were deployed between the years 2003 and 2011. After that, stenting was less reported (only 5 case reports and one case series of 5 patients). All over, ten stents were deployed between the years 2012–2021. During the first procedure, immediate lead stenting was done in 349 patients who met specific criteria, as reported in four observational studies (16–19). The most extensive series was from Budapest. Gellér et al. (2011) included 296 of 312 patients who had lead stenting during the first procedure due to intraoperative lead instability or PNS, reoperation was required

in two patients, and 18 patients had PNS during a median follow-up of 28.4 months (17). In Szilagyi S et al. (2007) study, 29 patients had in procedure lead dislocation that required direct stenting without fluoroscopic dislocation during follow-up (11.5 +/- 5.5, 2–23 months)(19). As noted in Biffi M et al. (2014) study, early recognition of alarming coronary vein anatomy that predisposes to lead dislodgement such as coronary sinus branch has an ascendant path, branch adjacent to the coronary sinus ostium or branch with a flat take-off at a more than 80° angle from the CS may predict and necessitate ad hoc LV lead stabilization, in this study 16 patient had ad hoc lead stenting based in these coronary sinus anatomical features, none of them had adverse events during 23.8 ± 3.1 months follow-up(16). Due to these favorable results, randomized trials with more significant numbers of patients to assess the long-term efficacy and cost-effectiveness of ad hoc lead stenting in the first cardiac resynchronization implantation are needed.

Some implanters advocate using short and smaller stent diameter by approximately 0.5 mm for lead stabilization to ease extractions if needed (50). However, still believe that using at least 1:1 sized stent in a distensible vein can hold the lead in place, adapt the jailed lead without affecting their integrity, and prevent stent and lead dislocation. Also, the necessity for lead extraction is low, and all cases that required extraction were done smoothly without complication, as reported in this review (16,17,51). As well, the microscopic examination of two coronary sinus specimens in which the lead stabilized with stent showed that the lead and stent were separated and covered by an intact intimal tissue layer. There was no particular damaging effect on the vascular system after extraction (52). Moreover, the examination of stented coronary sinus lead by optical, confocal, x ray, and scanning electron microscopy demonstrated multiple surface injuries were created on the insulation without affecting their electronic integrity (53).

CONCLUSION

Stenting the left ventricular lead during cardiac synchronization therapy implantation in discriminated cases seems safe and effective without adverse events such as loss of lead integrity or coronary vein distortion. Large randomized trials are needed to support using this technique in biventricular pacing implantation procedures.

Funding: None

Conflict of interest: none declared.

Patient consent

The patient gave his informed consent for publication. The scientific and research ethics committee of the royal medical service (Jordan) approved the protocol of this study.

REFERENCES

1. Thébault C, Donal E, Meunier C, Gervais R, Gerritse B, Gold MR, et al. 2012. Sites of left and right ventricular lead implantation and response to cardiac resynchronization

- therapy observations from the REVERSE trial. *Eur Heart J*. Nov;33(21):2662-71.
2. Daubert J, Saxon L, Adamson PB, Auricchio A, Berger RD, Beshai JF, et al. 2012. EHRA/HRS expert consensus statement on cardiac resynchronization therapy in heart failure: implant and follow-up recommendations and management. *Heart Rhythm*. 2012 Sep;9(9):1524-76.
 3. Knight BP, Desai A, Coman J, Faddis M, Yong P. 2004. Long-term retention of cardiac resynchronization therapy. *J Am Coll Cardiol*. 2004 Jul 7;44(1):72-7.
 4. Kumagai Y, Arimoto T, Yamauchi S, Kutsuzawa D, Tsuchiya H, Watanabe M. 2018. Implantation of a cardiac resynchronization therapy device using the anchor balloon technique in a patient with a tortuous coronary sinus branch. *HeartRhythm Case Rep*. Aug;4(8):339-42.
 5. Van Gelder BM, Meijer A, Basting P, Hendrix G, Bracke FA. 2003. Successful implantation of a coronary sinus lead after stenting of a coronary vein stenosis. *Pacing Clin Electrophysiol*. Sep;26(9):1904-6.
 6. Seth J. 2017. Worley, Coronary Sinus Lead Implantation, Clinical Cardiac Pacing, Defibrillation and Resynchronization Therapy, 10.1016/B978-0-323-37804-8.00030-4, (739-834).
 7. Gellér L, Salló Z, Molnár L, Tahin T, Özcan EE, Kutya V, et al. 2019. Long-term single-centre large volume experience with transeptal endocardial left ventricular lead implantation. *EP Europace*. Aug 1;21(8):1237-45.
 8. Hansky B, Vogt J, Gueldner H, Schulte-Eistrup S, Lamp B, Heintze J, et al., 2007. Implantation of active fixation leads in coronary veins for left ventricular stimulation: report of five cases. *Pacing Clin Electrophysiol*. Jan;30(1):44-9.
 9. Gerontitis D, Diab I, Chow AWC, Hunter RJ, Leyva F, Turley AJ, et al. UK multicenter retrospective comparison of novel active versus conventional passive fixation coronary sinus leads. *J Cardiovasc Electrophysiol*. 2020 Nov;31(11):2948-53.
 10. Chen L, FU H, Pretorius VG, Yang D, Wiste HJ, Yuan H, et al. 2015. Clinical Outcomes of Cardiac Resynchronization with Epicardial Left Ventricular Lead. *Pacing and Clinical Electrophysiology*. Oct;38(10):1201-9.
 11. Garikipati NV, Mittal S, Chaudhry F, Musat DL, Sichrovsky T, Preminger M, et al., 2014. Comparison of Endovascular Versus Epicardial Lead Placement for Resynchronization Therapy. *The American Journal of Cardiology*. Mar;113(5):840-4.
 12. Marini M, Branzoli S, Moggio P, Martin M, Belotti G, Molon G, et al. Epicardial left ventricular lead implantation in cardiac resynchronization therapy patients via a video-assisted thoracoscopic technique: Long-term outcome. *Clin Cardiol*. 2020 Mar;43(3):284-90.
 13. Vijayaraman P, Chung MK, Dandamudi G, Upadhyay GA, Krishnan K, Crossley G, et al. His Bundle Pacing. *Journal of the American College of Cardiology*. 2018 Aug;72(8):927-47.
 14. Galand V, Singh JP, Leclercq C. Alternative left ventricular pacing approaches for optimal cardiac resynchronization therapy. *Heart Rhythm*. 2019 Aug;16(8):1281-9.
 15. Gellér L, Szilágyi S, Róka A, Merkely B: Coronary sinus sidebranch stenting as a tool for coronary sinus lead dislocation in patients with heart failure and left bundle branch block. *Eur Heart J* 26(Suppl1), 52/P486 (2005).
 16. Biffi M, Bertini M, Ziacchi M, Diemberger I, Martignani C, Boriani G. Left ventricular lead stabilization to retain cardiac resynchronization therapy at long term: when is it advisable?. *Europace*. 2014 Apr 1;16(4):533-40.
 17. Gellér L, Szilágyi S, Zima E, Molnár L, Széplaki G, Végh EM, et al. Long-term experience with coronary sinus side branch stenting to stabilize left ventricular electrode position. *Heart Rhythm*. 2011 Jun;8(6):845-50.
 18. Demir AD, Cay S, Erbay AR, Maden O, Atak R, Balbay Y. Long-term follow-up data of coronary sinus stenting for the stabilization of the left ventricular leads. *Pacing Clin Electrophysiol*. 2010 Dec;33(12):1485-9.
 19. Szilagy S, Merkely B, Roka A, Zima E, Fulop G, Kutya V, et al. Stabilization of the coronary sinus electrode position with coronary stent implantation to prevent and treat dislocation. *J Cardiovasc Electrophysiol*. 2007 Mar;18(3):303-7.
 20. Kowalski O, Lenarczyk R, Prokopczuk J, Pruszkowska-Skrzep P, Zieli ska T, Sredniawa B, et al. Effect of percutaneous interventions within the coronary sinus on the success rate of the implantations of resynchronization pacemakers. *Pacing Clin Electrophysiol*. 2006 Oct;29(10):1075-80.
 21. Oto A, Aytemir K, Okutucu S, Canpolat U, Sahiner L, Ozkutlu H. Percutaneous coronary sinus interventions to facilitate implantation of left ventricular lead: a case series and review of literature. *J Card Fail*. 2012 Apr;18(4):321-9.
 22. Maldonado JGA, Fank C, Maduro S, Castro R, Oliveira H, Gomes A. Supporting stent of coronary sinus lead in cardiac resynchronization: report of 5 cases. *Arq Bras Cardiol*. 2012 Nov;99(5):e159-e161.
 23. Cesario DA, Shenoda M, Brar R, Shivkumar K. Left ventricular lead stabilization utilizing a coronary stent. *Pacing Clin Electrophysiol*. 2006 Apr;29(4):427-8.
 24. Fujii S, Tasaka H, Kawakami T, Mitsudo K, Takenaka S. Stent placement to stabilize the left ventricular lead in the coronary sinus. *Journal of Arrhythmia*. 2008;24(3):162-5.
 25. Weipert K, Gemein C, Chasan R, Wiebe J, Doerr O, Boeder N, et al. First-in-Man Coronary Sinus Lead Stabilization Using a Bioresorbable Vascular Scaffold System. *Circ ArrhythmElectrophysiol*. 2015 Dec;8(6):1518-9.
 26. Grabowski M, Michalak M, Zawadzki J, Kochman J, Opolski G. Repositioning of the left ventricular lead with bioresorbable vascular scaffold stabilization. *Kardiol. Inwazyjna* 2017; 12 (3), 6–8.
 27. Kamalzadeh H, Yazdani S, Jalali M. Coronary Sinus Stenting for the Management of Left Ventricular Lead Displacement during Resynchronization Therapy: A Report of Two Cases. *J Tehran Heart Cent*. 2018 Jan;13(1):27-31.
 28. Agarwal D, Makhija A, Mohanty A, Mantri RR. A rare case of left ventricular lead stabilization utilizing a coronary stent placement during CRT-D implantation. *The European Research Journal* 2019;5(2):407-409.
 29. Barwad P, S Vemuri K, CR P, Vijay J. Coronary sinus stenting for stabilizing a difficult quadripolar left ventricular lead. *J Cardio Case Rep*. 2020;3(2).
 30. Rossillo A, Verma A, Saad EB, Corrado A, Gasparini G, Marrouche NF, et al. Impact of coronary sinus lead position on biventricular pacing: mortality and echocardiographic evaluation during long-term follow-up. *J Cardiovasc Electrophysiol*. 2004 Oct;15(10):1120-5.
 31. Gerber TC, Sheedy PF, Bell MR, Hayes DL, Rumberger JA, Behrenbeck T, et al. None. *The International Journal of Cardiac Imaging*. 2001;17(1):65-75.
 32. Singh JP, Klein HU, Huang DT, Reek S, Kuniss M, Quesada A, et al. Left ventricular lead position and clinical outcome in the multicenter automatic defibrillator implantation trial-cardiac resynchronization therapy

- (MADIT-CRT) trial. *Circulation*. 2011 Mar 22;123(11):1159-66.
33. Silver MA, Rowley NE. The functional anatomy of the human coronary sinus. *Am Heart J*. 1988 May;115(5):1080-4.
 34. von Lüdinghausen M. The venous drainage of the human myocardium. *Adv AnatEmbryol Cell Biol*. 2003;168:I-VIII, 1-104.
 35. Boonyasirinant T, Halliburton SS, Schoenhagen P, Lieber ML, Flamm SD. Absence of coronary sinus tributaries in ischemic cardiomyopathy: An insight from multidetector computed tomography cardiac venographic study. *J Cardiovasc ComputTomogr*. 2016 Mar-Apr;10(2):156-61.
 36. Gurevitz O, Nof E, Carasso S, Luria D, Bar-Lev D, Tanami N, et al. Programmable multiple pacing configurations help to overcome high left ventricular pacing thresholds and avoid phrenic nerve stimulation. *Pacing Clin Electrophysiol*. 2005 Dec;28(12):1255-9.
 37. Bisch L, Da Costa A, Dauphinot V, Romeyer-Bouchard C, Khriis L, M'baye A, et al. Predictive factors of difficult implantation procedure in cardiac resynchronization therapy. *Europace*. 2010 Aug;12(8):1141-8.
 38. Da Costa A, Gate-Martinet A, Rouffiangé P, Cerisier A, Nadrouss A, Bisch L, et al. Anatomical factors involved in difficult cardiac resynchronization therapy procedure: a non-invasive study using dual-source 64-multi-slice computed tomography. *Europace*. 2012 Jun;14(6):833-40.
 39. Katbeh A, Van Camp G, Barbato E, Galderisi M, Trimarco B, Bartunek J, et al. Cardiac Resynchronization Therapy Optimization: A Comprehensive Approach. *Cardiology*. 2019;142(2):116-28.
 40. Biffi M, Moschini C, Bertini M, Saporito D, Ziacchi M, Diemberger I, et al. Phrenic stimulation: a challenge for cardiac resynchronization therapy. *Circ ArrhythmElectrophysiol*. 2009 Aug;2(4):402-10.
 41. Spencer JH, Goff RP, Iaizzo PA. Left phrenic nerve anatomy relative to the coronary venous system: Implications for phrenic nerve stimulation during cardiac resynchronization therapy. *Clin Anat*. 2015 Jul;28(5):621-6.
 42. Moubarak G, Bouzeman A, Ollitrault J, Anselme F, Cazeau S. Phrenic nerve stimulation in cardiac resynchronization therapy. *J Interv Card Electrophysiol*. 2014 Oct;41(1):15-21.
 43. Linde C, Abraham WT, Gold MR, Daubert C. Cardiac Resynchronization Therapy in Asymptomatic or Mildly Symptomatic Heart Failure Patients in Relation to Etiology. *Journal of the American College of Cardiology*. 2010 Nov;56(22):1826-31.
 44. Zhao X, Burger M, Liu Y, Das MK, Combs W, Wenk JF, et al. Simulation of LV Pacemaker Lead in Marginal Vein: Potential Risk Factors for Acute Dislodgement. *Journal of Biomechanical Engineering*. 2011 Mar 1;133(3).
 45. Habib A, Lachman N, Christensen KN, Asirvatham SJ. The anatomy of the coronary sinus venous system for the cardiac electrophysiologist. *Europace*. 2009 Nov 1;11(Supplement 5):v15-v21.
 46. Sinha M, Pandey NN, Sharma A. Anomalies of the Coronary Sinus and Its Tributaries. *Journal of Thoracic Imaging*. 2020 Mar;35(2):W60-W67.
 47. Alves Silva LA, de Souza Meira EB, Curimbaba J, Pimenta JA. Coronary Sinus Phlebography in Cardiac Resynchronization Therapy Patients: Identifying and Solving Demanding Cases. *J Innov Card Rhythm Manag*. 2020 Jul;11(7):4161-70.
 48. Choy JS, Dang Q, Molloy S, Kassab GS. Nonuniformity of axial and circumferential remodeling of large coronary veins in response to ligation. *Am J Physiol Heart Circ Physiol*. 2006 Apr;290(4):H1558-65.
 49. Anwar MA, Shalhoub J, Lim CS, Gohel MS, Davies AH. The effect of pressure-induced mechanical stretch on vascular wall differential gene expression. *J Vasc Res*. 2012;49(6):463-78.
 50. Merkely B, Molnár L, Szilágyi S, Gellér L. Advanced Techniques for CRT Implantation. In: Das MK, editor. *Modern Pacemakers* [Internet]. Rijeka: IntechOpen; 2011. Available from: <https://doi.org/10.5772/14929>.
 51. Niazi I, Bajwa T, Sra J, Akhtar M. A Review of Innovative Strategies for CRT Implantation: Part II Coronary Venous Stenting. In 2011. DOI: 10.19102/icrm.2011.020201.
 52. Balázs T, Merkely B, Bognár E, Zima E. Interaction of intraluminal tissue and coronary sinus lead stabilized with stent placement. *J Cardiovasc Electrophysiol*. 2013 Apr;24(4):468-70.
 53. Balázs T, Merkely B, Bognár E, Gellér L, Szilágyi S, Dobranszky J, et al. Methods for examination an explanted coronary sinus lead stabilized with a coronary stent. *Pacing Clin Electrophysiol*. 2013 Feb;36(2):e27-30.
