



RESEARCH ARTICLE

MANIFESTATIONS OF OCCIPITAL VERTEBRAE - ITS EMBRYOLOGICAL AND CLINICAL SIGNIFICANCE

*Dr. Radhika, P. M., Dr. Prathap, K. J., Dr. Shailaja Shetty and Dr. Anupama, K.

Department of Anatomy, M. S. Ramaiah Medical College, MSRIT Post, Bangalore, Karnataka 560054, India

ARTICLE INFO

Article History:

Received 04th January, 2013
Received in revised form
09th February, 2014
Accepted 25th March, 2014
Published online 23rd April, 2014

Key words:

Occipital vertebrae,
Hypocondylar arch,
Basilar process,
Median occipital condyle,
Paracondylar process,
Proatlas.

ABSTRACT

Background: Manifestations of the occipital vertebrae in the region of anterior rim of foramen magnum, either in the midline and/or laterally are due to failure of segmentation of the proatlas. The proatlas is derived from the fourth occipital sclerotome. There is a broad spectrum of occipital vertebrae variations which includes: third occipital condyle (condylus tertius), basilar process, paracondylar process and prebasiooccipital arch (hypocondylar arch).

These manifestations, if present can cause brainstem myelopathy and lower cranial nerves palsy during first and second decades of life.

Materials and Method: Two hundred dry adult human skulls of Indian origin were studied in the Department of Anatomy, M.S Ramaiah Medical College. The base of these skulls was observed for presence of remnants of occipital vertebrae.

Results: Out of 200 skulls, 4 skulls showed remnants of occipital vertebrae (2%). Median occipital condyle was observed in one skull (0.5%), hypocondylar arch was observed in one skull (0.5%), bilateral basilar process in one skull (0.5%) and bilateral paracondylar process in one skull (0.5%).

Conclusion: The knowledge of manifestations of occipital vertebrae is important for the radiologists during interpretation of radiographic images of the craniovertebral junction to make a distinctive diagnosis of its diseases and the neurosurgeons while doing skull base surgeries. An attempt has been made in the present study to throw light on the various manifestations of occipital vertebrae, its embryological and clinical significance.

Copyright © 2014 Dr. Radhika et al., This is an open access article distributed under the Creative Commons Attribution License, which permits unrestricted use, distribution, and reproduction in any medium, provided the original work is properly cited.

INTRODUCTION

The manifestations of occipital vertebrae are the rare congenital bony anomalies in the craniovertebral junction. They are due to failure of segmentation of the fourth occipital sclerotomes. They present as bony malformations in the region of anterior margin of foramen magnum either in the midline and/or laterally. These anomalies have been grouped under the term 'proatlas segmentation abnormalities'. These includes: median occipital condyle, processus basilaris, processus paracondylaris and arcus praebasioccipitalis. The term 'occipital vertebra' was introduced by Kollmann (Prescher 1996). At an early embryonic stage, a transient mesenchymal thickening is found ventral to the developing vertebral body in each vertebral segment and it is termed as 'hypochordal bridge'. These hypochordal bridges disappear with the exception of first cervical sclerotome, which forms the anterior arch of atlas. If it persists after birth in the occipital region along the anterior margin of foramen magnum between the occipital condyles, it can result in bony malformations in the craniovertebral transition zone (Pang 2011). The manifestation of occipital vertebrae may have the clinical features depending

on the structures compressed. It can either result in compression of neural or vascular structures or alteration in the dynamic flow of CSF (Reena Agrawal, 2010). The anatomical variations of Craniovertebral junction have recently become significant because of newer imaging techniques such as computed tomography and magnetic resonance imaging. Knowledge of these anomalies is important in interpreting unusual clinical presentations caused by these variations. The present study aims to note the frequency, embryology and clinical significance of the median occipital condyle, the basilar processes, hypocondylar arch and paracondylar process in Indian adult skulls.

MATERIALS AND METHODS

The study was conducted on 200 dry adult Indian skulls of unknown sex, which were collected from the Medical and Dental students, in the Department of Anatomy of M.S. Ramaiah Medical College, Bangalore, over a period of 3years. The base of the skull was examined for the presence of manifestations of occipital vertebrae.

RESULTS

In the present study, median occipital condyle was observed in 1/200 (0.5%) skulls (Figure 1), bilateral basilar processes in

*Corresponding author: Dr. Radhika, P. M.
Assistant Professor, Department of Anatomy, M. S. Ramaiah Medical College,
MSRIT Post, Bangalore, 560054, India.

1/200 (0.5%) skulls (figure 2), hypocondylar arch in 1/200 (0.5%) skulls (figure 3) and bilateral paracondylar processes were seen in 1/200 (0.5%) skulls (figure 4). Remaining 196 skulls were normal.




Figure 1. Median Occipital Condyle at the anterior aspect of foramen magnum

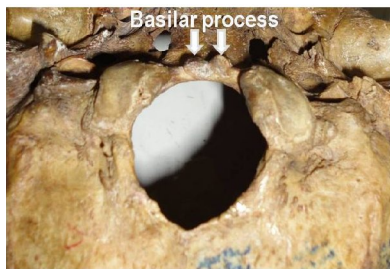


Figure 2. Bilateral basilar processes at the anterior margin of foramen magnum

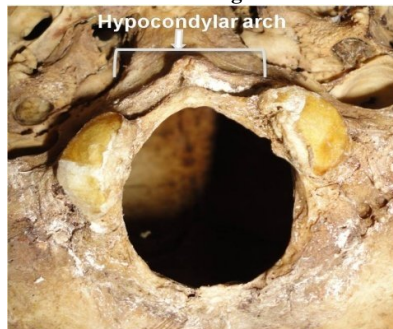


Figure 3. Hypocondylar arch extending between the two occipital condyles and present on the anterior aspect of foramen magnum

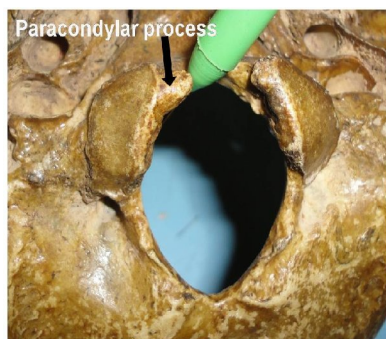


Figure 4. Bilateral paracondylar processes, anteromedial to the occipital condyles

DISCUSSION

The proatlas is a term used for the remnant of the fourth occipital sclerotome, if it is present as a separate entity. The proatlas is a vestigial bone formation that rarely persists as bony remnants in adult human which is due to failure of regression of embryonic structures. It is normally found between atlas and occipital bone in lower animals such as rodents, reptiles and dinosaurs. In humans, the proatlas fuses with the occipital bone around the foramen magnum. It is thus not usually observed as a separate structure in man. However, there are reports in which proatlantal remnants have been noted in humans (Mitchel Michlemana 2012; Menezes 2009). Although rare, manifestations of the occipital vertebra are seen if the proatlas is not completely incorporated into the base of the skull or into the upper cervical vertebrae or if its hypochordal blastema persists. The proatlas segmentation abnormalities can appear in various forms. The various forms of these abnormal manifestations of the occipital vertebra are median occipital condyle, processus basilaris, processus paracondylaris and arcus praebasioccipitalis (Prescher 1997).

Median occipital condyle

It is also called as third occipital condyle / condylus tertius. It was J.F. Meckel in 1815, who first described the median occipital condyle as a bony prominence in the anterior margin of the foramen magnum in the midline. The incidence of the third occipital condyle ranges from 0.25% to 1%. The Median occipital condyle results if the hypochordal bridges persists in the median aspect and disappears in the lateral aspects (von Lüdinghausen 2002).

Table 1. The incidence of median occipital condyle is compared with the previous studies

Authors	Incidence	Percentage
Von Lüdinghausen, 2002	7/209	3.34%
Taitz, 2000	1/214	0.47%
Rao, 2002	1/153	0.65%
Kale, 2009	2/397	0.5%
Present study	1/200	0.5%

The knowledge of the median occipital condyle is of clinically importance to the surgeons, as it may result in a 3-legged mechanism of head bearing, which can be one of the reasons for stiffness of neck, restrictions of head movement and even a bone-derived torticollis (von Lüdinghausen 2005).

It is important to distinguish median occipital condyle from os avis on radiographs because both these bony projections are present at the tip of clivus. The median occipital condyle is more stable when compared to os avis and the treatment in both these cases differs. There is possibility of misinterpretation of third occipital condyle as os avis or as ossification of the apical ligament of dens or vice-versa on radiographs since these bony projections are present at the tip of clivus. However, it is important to distinguish them because of their different implications of their stability. In the median occipital condyle, odontoid process has normal height and therefore it remains as a stable pivot joint with the transverse ligament of atlas. In os avis, the odontoid process becomes hypoplastic resulting in

loss of its tip, thus the height is reduced leading to instability of median atlanto-axial joint. In case of ossification of the apical ligament of dens, it appears as a small peaked bony spur at the same place on the radiograph (Prescher 1996; Rao 2002). Although some third occipital condyles are short, it can result in ventral cervicomedullary junction compromise resulting in brainstem myelopathy and cranial nerve defects (Kotil 2005; von Torklus 1972).

Processus basilaris

These are small bony projections present at the anterior edge of the foramen magnum. If the lateral parts of the hypochordal bar persist while the central part degenerates, the processus basilaris result. They can present in various forms. These tubercles may occur either unilaterally or bilaterally. Occasionally, these tubercles may be well developed and fuses together in the midsagittal region to form a pseudocondylus tertius, which is perforated by a fine sagittal canal called canalis intraoccipitalis. This fine bony canal within the pseudocondylus differentiates it from the condylus tertius, which does not have a canal. If the processus basilaris more closely resemble bulges, they are sometimes also described as "labia foraminis magni anteriora". The processus basilaris can be demonstrated by conventional frontal tomography or in CT. It may be firmly attached to the margin of foramen magnum or they may form accessory bony element (Prescher 1996; Rao 2002).

Table 2. The incidence of basilar process is compared with the previous studies

Authors	Incidence	Percentage
Kale, 2009	5/397	U/L 1.3%
	14/397	B/L 3.5 %
Present Study	1/200	0.5%

A pseudojoint may be formed between the basilar process and the tip of the dens or with the anterior arch of the atlas, thereby affecting the integrity and functioning of the atlantooccipital joint (Vasudeva 1996).

Arcus praebasioccipitalis

It is also called as hypochondylar arch/ praebasioccipitalis arch. It is a bony arch which is present at the entire anterior margin of the foramen magnum. It can either be present as an isolated horseshoe shape bony arch or it cranially articulating with the basilar part of the occipital bone and caudally with the anterior arch of the atlas as well as with the tip of the dens. It was described by Prescher, the hypochondylar arch resembles the "hat of Napoleon" on radiographic images (Prescher 1996).

Table 3. The incidence of arcus praebasioccipitalis is compared with the previous studies

Authors	Incidence	Percentage
Taitz, 2000	1/214	0.47%
Kale, 2009	26/397	6.5%
Lombardi G, 1961	1/4000	0.025%
Present study	1/150	0.67%

Embryologically, if the entire hypochordal blastema of the proatlas persists, it results in hypochondral arch and therefore practically it represents a combination of bilateral basilar processes with median occipital condyle (Prescher 1996; Rao 2002). The arcus praebasioccipitalis may often be associated with severe arthrosis resulting in impairment of the kinetics of the atlantooccipital and atlantoaxial joints of the skull.

Processus paracondylicus

It is also called as paracondylar process. It is a broad based, cone-shaped osseous mass projecting down from the lateral aspect of the occipital condyle towards the transverse process of atlas. The paracondylar process also referred to by various misnomers like paramastoid process, paroccipital process, jugular process, parajugular process (Nolet 1999). A paracondylar process can range in size from a small protuberance to an elongated process and may occasionally articulate with an epitransverse process extending from the atlas. If the process presents in the rudimentary form, it is called as 'tuberculum paracondylicum'. If it gets separated from the occipital bone and presents as an isolated conical bony mass, it is termed as 'massa paracondylicca'. If this massa paracondylicca fuses with the transverse process of atlas, it is called as 'processus epitransversus' (Prescher 1996; Rao 2002). The process is present close to the insertion of the lateral rectus capitis muscle. In case of larger processes, this muscle may be either diminished in size or completely absent (PS Nolet, 1999). A paracondylar process represents vestigial remnant of the rostral half of the first cervical sclerotome. The presence of paracondylar process represents caudal shifting of the vertebra, which means taking the characteristics of its caudal vertebrae, due to this there is a separation of the occipital vertebrae from the basi-occiput. This can be distinguished from 'occipitalization of the atlas', in which there is cranial shifting of the vertebra (Anderson 1996; Smoker 1995). 'Occipitalization of the atlas' is due to failure in segmentation and separation of the most caudal occipital sclerotome and first cervical sclerotome during the fourth week of intrauterine life, resulting in complete fusion of atlas to the base of the cranium (Radhika 2013).

Table 4. The incidence of Processus paracondylicus was compared with the previous studies

Authors	Incidence	Percentage
Jasbir Kaur, 2012	7/100	U/L 7%
	14/100	B/L 14%
Anderson, 1996	6/1300	0.46%
Lombardi G, 1961	5/4000	0.12%
Present Study	1/200	0.5%

The paracondylar process may often be associated with severe arthrosis causing severe impairment of the biomechanics of the joints and may result in torticollis. The paracondylar process may fuse or it may form a pseudojoint with the transverse process of the atlas causing restriction of the head movements resulting in bony torticollis or the head may remain in the attitude of flexion called as caput obstipum. The paracondylar process may interfere in skull base surgeries or while performing a neck dissection (Todd McCall 2012).

Conclusion

The proatlas segmentation anomalies may result in one of the following presentation

- It may cause narrowing of the foramen magnum resulting in compressive neurological symptoms. These manifestations if present can cause brainstem myelopathy and lower cranial nerves palsy during first and second decades of life.
- It may form a pseudojoint either with the tip of the dens or with the anterior arch of atlas, thereby affecting the integrity and functioning of the atlantooccipital joint.
- A complete persistent occipital vertebra may unite with the anterior arch of the atlas causing abnormal angulation between the clivus and atlanto-axial complex with subsequent ventral compression of the cervicomedullary junction.

The patients having vague symptoms like neck pain, dizziness, torticollis or disturbances in equilibrium often seek repeated medical advice. Without proper diagnosis, there can be a chance of delay in the treatment and at times, can result in untoward complications. So, the physician should be aware of such rare anomalies like "manifestation of occipital vertebrae" so as to diagnose and treat such conditions. Hence the understanding of anatomy, embryology and anomalies of the craniovertebral junctions is of immense importance to the orthopedicians, neurologists, Head and neck surgeons, radiologist and neurosurgeon.

Acknowledgement

The authors are grateful to authors, editors, and publishers of those articles, journals and books from where the literature for this article has been reviewed and discussed.

REFERENCES

- Agrawal, R., Ananthi, S., Agrawal, S. 2010. Anomalies of the craniovertebral junction – a very rare case report. *Eur J Anat.*, 14 (1): 43-47.
- Anderson, T. 1996. Paracondylar process- manifestation of an occipital vertebra. *International Journal of Osteoarchaeology.*, 6(2):195-201.
- Goel, A and Shah, A. 2010. Unusual bone formation in the anterior rim of foramen magnum: Cause, effect and treatment. *Eur Spine J.*, 19(2): 162–164.
- Kale, A., Ozturk, A., Aksu, F., Gurses, I A., Gayretli, O., Bayraktar, B., et.al. 2009. Bony variations of the craniovertebral region. *Neurosciences.*, 14 (3): 296-297.
- Kaur, J., Srivastava, D., Singh, D., Raheja, S. 2012. The study of hyperostotic variants: significance of hyperostotic variants of human skulls in anthropology. *Anat Cell Biol.*, 45:268-273.
- Kotil, D and Kalayci, M. 2005. Ventral cervicomedullary junction compression secondary to condylus occipitalis (median occipital condyle), a rare entity. *J Spinal Disord Tech.*, 18(4):382–385.

- Lombardi, G. 1961. The Occipital vertebra. *American Journal of Roentgenology.*, 86, 260-269.
- McCall, T., Coppens, J., Couldwell, W. 2010. Symptomatic occipitocervical paracondylar process. *J Neurosurg Spine.*, 12:9–12, 9-12.
- Menezes, A.H and Fenoy, K.A. 2009. Remnants of occipital vertebrae: proatlas segmentation abnormalities. *Neurosurgery.*, 64:945–953.
- Menezes, A.H and Van Gilder, J.C. 1990. Anomalies of the craniovertebral junction. In: Youman JR (ed). *Neurological surgery.* 3rd ed. Saunders, Philadelphia. 1359-1420.
- Michlemana, M., Charran, O., Matusz, P., Shoja, M.M., Tubbs, R.S., Loukas, M. 2012. The proatlas- a comprehensive review with the clinical implications. *Child nerv system.*, 28:349-56.
- Nolet, D.C., Friedman, L.P.S., Brubaker D. 1999. Paracondylar process: a rare cause of craniovertebral fusion - a case report. *J Can Chiropr Assoc.*, 43(4). 229-235.
- Pang, D.N. and P.D Thompson. 2011. Embryology and bony malformations of the craniovertebral junction. *Childs Nerv Syst.*, 27: 523–564.
- Prakash, B.S., Padmalatha, K., Menda, J.L., Ramesh, B.R. 2011. A tubercle at the anterior margin of foramen magnum. *International Journal of Anatomical Variations.*, 4: 118–119.
- Prescher, A. 1997. The craniocervical junction in man, the osseous variations, their significance and differential diagnosis. *Ann Anat.*, 179:1–19.
- Prescher, A., Brors, D., Adam, G. 1996. Anatomic and radiologic appearance of several variants of the craniocervical junction. *Skull Base Surg.*, 6: 583–594.
- Radhika, P.M., Shetty, S., Komala, N., Prathap, K.J., Jyothi, K.C. 2013. An Osteological Study of Occipitocervical Synostosis: Its Embryological and Clinical Significance. *Journal of Clinical and Diagnostic Research.*, 7(9): 1835-1837.
- Rao, P. 2002. Median (third) occipital condyle. *Clin Anat.*, 15:148–151.
- Smoker, W.R. 1995. Congenital anomalies of the cervical spine. *Neuroimaging Clin N Am.*, 5(3):427-429.
- Taitz, C. 2000. Bony observations of some morphological variations and anomalies of the craniovertebral region. *Clin Anat.*, 13: 354-360.
- von Lüdinghausen, M., Schindler, G., Kageyama, I., Pomaroli, A. 2002. The third occipital condyle, a constituent part of a median occipito-atlanto-odontoid joint: a case report. *Surg Radiol Anat.*, 24(1):71-76.
- Vasudeva, N and Choudhry, R. 1996. Precondylar tubercles on the basiocciput of adult human skulls. *J Anat.*, 188 : 207–210.
- von Lüdinghausen, M., Fahr, M., Prescher, A., Schindler, G., Kenn, W., Weiglein, A., et al. 2005. Accessory joints between basiocciput and atlas/axis in the median plane. *Clin Anat.*, 18: 558-571.
- von Torklus, D and Gehle, W. 1972. Anomalies and malformations. In: von Torklus D, Gehle W (eds) *The upper cervical spine.* Thieme, Stuttgart. 14–53.
