



ISSN: 0975-833X

CASE STUDY

STOP - RED SIGNAL AGAIN, SERRATIA MARCESCENS REAPPEARS IN COMMUNITY

***Dr. Sangeeta Das Ghosh, Dr. Mandira Chakraborty, Dr. Indrani Bhattacharyya, Dr. Abhisek Mitra, Dr. Siddhartha Bhowmik and Dr. Dipankar Paul**

Department of Microbiology, Calcutta School of Tropical Medicine, India

ARTICLE INFO

Article History:

Received 10th February, 2015
Received in revised form
14th March, 2015
Accepted 03rd April, 2015
Published online 25th May, 2015

Key words:

Serratia marcescens, Immunocompetent,
Community acquired, Antibiotic resistance.

Copyright © 2015 Dr. Sangeeta Das Ghosh et al. This is an open access article distributed under the Creative Commons Attribution License, which permits unrestricted use, distribution, and reproduction in any medium, provided the original work is properly cited.

ABSTRACT

We present 2 cases of urinary tract infections from rural areas of West Bengal, caused by *Serratia marcescens*. Though *Serratia marcescens* is an important nosocomial pathogen, its emergence as a community acquired uropathogen has not been reported frequently. Further, both the cases were immunocompetent & of extreme age groups- contradicting the idea of its age & immune status dependent virulence. In both of our cases, the isolated *Serratia marcescens* strains were beta lactamase producing, conferring resistance to broad spectrum beta lactam antibiotics. So in our cases treatment was modified to ceftazidime & patients' conditions improved.

INTRODUCTION

S. marcescens was discovered in 1819 by Venetian pharmacist Bartolomeo Bizio, as the cause of an episode of blood-red discoloration of polenta in the city of Padua. Once considered a harmless saprophyte, ***Serratia marcescens*** is now recognized as an important opportunistic pathogen combining a propensity for healthcare-associated infection and antimicrobial resistance. ***Serratia marcescens*** is a member of the genus ***Serratia***, which is a part of the family **Enterobacteriaceae**. As members of the **Enterobacteriaceae** family, ***Serratia*** spp are motile, non-endospore forming Gram-negative rods (Ananthanarayan and Paniker, 2013). Currently 14 species of ***Serratia*** are recognized within the genus, eight of which are associated with human infection. Of the eight species implicated in clinical infections ***S. marcescens***, ***S. liquefaciens*** and ***S. odorifera*** are best known. Of all ***Serratia*** species, ***S. marcescens*** is the most common clinical isolate and the most important human pathogen (Patric *et al.*, 2005). ***Serratia marcescens*** is having a strong propensity to cause health care associated infections in immunocompromised hosts. Here we are emphasizing two facts, that neither of our patients is immunocompromised nor were they hospitalised before acquiring infections. From our institution a case has already been reported establishing community acquired infection by *S. marcescens* (Bhattacharyya *et al.*, 2014). As the patient was HIV positive expectations were still there that *Serratia* infections need some kind of immune suppression.

But here both the patients are immune competent, strongly supporting the probability that *Serratia* can invade healthy individuals in community. So the clinicians shouldn't exclude *Serratia* infections, merely considering an individual as immunocompetent, without getting culture & antibiotic sensitivity reports from a microbiologist, as the organism is having devastating potential to elaborate antibiotic resistance.

Case Reports

Case 1

A female patient aged 9 months, attended tropical medicine OPD with history of fever & reddish discoloration of urine for last 2 days. Mother was also giving history of sudden onset of crying of the baby during micturition. According to her mother, the child was apparently well 5 days back, when she noticed bloody tinge in her diaper.

On physical examination, pulse rate was 120/min, respiratory rate was 28 breaths/ min, & body temperature was 100^o F. There was no lymphadenopathy. Other systemic examinations were within normal limits. Laboratory tests showed the following results-TLC-9960/ microlitre, with 40% neutrophils, 52% lymphocytes, 5% monocytes & 3% eosinophils. Haemoglobin-9.6gm/dl, platelet count 454000/ microlitre, urea 10mg/dl, creatinine 0.5mg/dl. Sodium131/ mmol, K⁺ 4.7, total protein 6.1gm/dl, ESR 60 mm in 1st hour. CRP was also increased with a value of 83.08 / l. The immunisation history of the child was complete up to 9 months of age & a BCG scar was present. Developmental milestones were normal. The mother was nonreactive for HIV 1 & 2.

*Corresponding author: Dr. Sangeeta Das Ghosh,
Department of Microbiology, Calcutta School of Tropical Medicine, India.

Case 2

A 56 year old male patient attended OPD with complaints of frequency & burning sensation of micturition along with lower abdominal pain. When he was enquired about the colour of the urine it was revealed to have reddish tinge. On physical examination, pulse rate was 82/ min, respiratory rate was 14/min, body temperature was 98.6⁰ F without lymphadenopathy. Laboratory tests showed the following results-TLC-9960/ microlitre, Hb 11gm/ dl, platelet-150000/microlitre, urea, creatinine, CRP and electrolytes were within normal limits. ESR was 45 mm in the 1st hour. The patient was nonreactive for HIV 1 & 2. Patient was non diabetic. No other co-morbidities were present. A clinical diagnosis of urinary tract infection was made in both the cases. The child was initially started with syrup Amoxycillin & syrup Metroglol keeping in mind the possibility of polymicrobial infections. The elderly male patient was started with Levofloxacin. In both the cases the patients did not show much improvement as a result of empirical treatment. Routine microscopic examination of urine was done for detection of pus cells in both uncentrifuged & centrifuged specimens. Plenty of pus cells were seen in both the cases. A loopfull of urine was inoculated onto Blood agar, MacConkey, CLED, & nutrient agar plate & incubated at 37^o C aerobically. Non-lactose fermenting colonies on MacConkey & CLED agar, & grey colonies on Blood agar were obtained after 24 hours of incubation. On Gram staining of the colonies, Gram negative bacilli were seen, which were motile in the hanging drop preparation at 25^oC. Biochemical reactions were negative for indole, MR, & urease. Citrate utilisation test was positive. Triple sugar iron agar showed an alkaline/ acid reaction without gas formation.

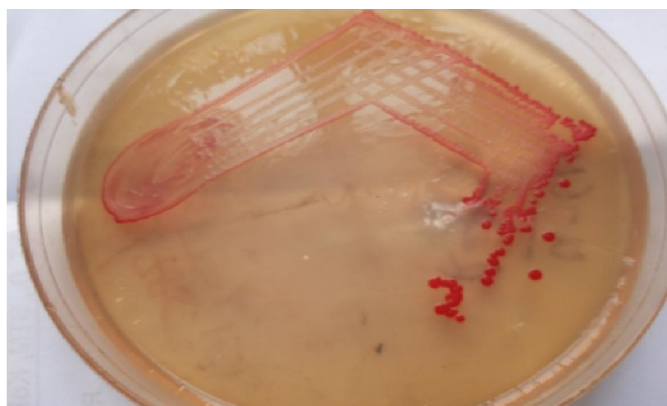


Fig. 1. Red coloured pigment of *Serratia marcescens* on Nutrient agar




Fig. 2. Left to right- Indole -ve, Triple sugar iron alkali/acid, Urease -ve, Citrate +ve

The following day, the primary culture plates showed the production of red coloured pigments when incubated at 25⁰ C, which is characteristic of 3 species of *Serratia*. *Serratia marcescens*, *Serratia plymuthica*, & *Serratia Rubidaea* (Patric R et,al 2005). For further speciation, L- arabinose & sucrose fermentation tests were carried out. The strains were negative for L arabinose which excludes the possibilities of the strains of being *S. plymuthica* or *S. rubidaea*. Sucrose fermentation was positive. Ornithine decarboxylase tests & Lysine decarboxylase tests were positive & Arginine decarboxylase tests were negative which further confirmed the species as *S. marcescens* excluding *S. plymuthica* & *S. rubidaea*. In both the cases organisms were sensitive to ceftazidime, amikacin, imipenem & were resistant to ampicillin, levofloxacin, Piperacillin- tazobactam & nitrofurantoin.




Fig 3. A. Ornithine positive, B. Lysine positive, C. Arginine negative, D. Moeller decarboxylase

Muller Hinton agar plates also showed the evidence of production of characteristic Red pigment of prodigiosin. Blood cultures were done to rule out septicaemia. After the sensitivity reports metronidazole & amoxycillin were omitted & intravenous ceftazidime & amikacin were given for 10 days. Under this therapy UTI subsided in both the cases & the patients were discharged.

DISCUSSION

S. marcescens is credited with a long history dating back to antiquity, when, because of its ability to produce a red pigment it was described as having 'masqueraded' as blood. Early in this century, this distinctive red pigmentation of *S. marcescens*, combined with an apparent low level of virulence, led to its use as a biological marker of infection. Consequently, *S. marcescens* was used in a number of classic bacterial transmission experiments, which led to improved understanding of the epidemiology of infection. Under more controversial settings, *S. marcescens* was also used by the US military in a series of biological warfare test experiments conducted on the general population (Yu, 1979). From 1960 onwards, however, non-pigmented isolates of *S. marcescens* predominated over pigmented strains in the clinical setting and were increasingly implicated in healthcare-associated infection

particularly among compromised patients (de Vries *et al.*, 2006). In 1958, 'red diaper syndrome' was observed in an infant at the University of Wisconsin Hospital. Since the "blue diaper syndrome" is caused by the abnormal metabolism of tryptophan, the father of the infant, a genetics professor, suspected an inborn error of metabolism. Eventually, these workers isolate *S. marcescens* from the infant's stool. Absorption spectrophotometry verified that the colouration in the diapers originated from the pigment produced by the bacterium. They subsequently discovered that a pigmented strain of *S. marcescens* was being used as a marker in a study of aerosol techniques in a nearby laboratory and that it was antigenically identical to the infant's strain. The infant was asymptomatic, but, despite sulfasuxidine therapy, his diapers continued to show red colouration for the next seven months. . Due to its abundant presence in the environment, and its preference for damp conditions, *S. marcescens* is commonly found growing in bathrooms (especially on tile grout, shower corners, toilet water line, and basin), where it manifests as a pink, pink-orange, or orange discoloration and slimy film feeding off phosphorus-containing materials or fatty substances such as soap and shampoo residue. Once established, complete eradication of the organism is often difficult, but can be accomplished by application of a bleach-based disinfectant. Rinsing and drying surfaces after use can also prevent the establishment of the bacterium by removing its food source and making the environment less hospitable. *S. marcescens* may also be found in environments such as dirt, supposedly "sterile" places, and the subgingival biofilm of teeth. *S. marcescens* is implicated in a wide range of serious infections including lower respiratory tract infection (Gaughran, 1969), urinary tract infection, (van der Vorm, Woldring-Zwaan, 2002), bloodstream infection, wound infection and meningitis (Merkier *et al.*, 2013).

The organism has also been described as an important cause of ocular infection with high incidence in contact lens-related keratitis (Atlee *et al.*, 1970). *S. marcescens* is also a rare cause of endocarditis (Mills, Drew, 1976). In the 1970s, *S. marcescens* was the most frequent cause of Gram-negative endocarditis among intravenous drug addicts in San Francisco. The frequency has since subsided, although sporadic cases of Serratia endocarditis still occasionally occur with two of the highest risk groups including intravenous drug users and patients undergoing prosthetic valve surgery (Sokalski *et al.*, 1992). Skin and soft tissue infections are also unusual although rare cases of invasive cellulitis and necrotizing fasciitis have been reported. Septic arthritis has also been reported following diagnostic and therapeutic intra-articular injections. Gastrointestinal carriage is very common for this infection (Byrne *et al.*, 2001) Once established, carriage is persistent and patients are likely to carry the organism at multiple sites, with the throat and nose identified as common sites in 59% and 31% of colonized patients, respectively. In keeping with its role as an agent of opportunistic infection, *S. marcescens* was traditionally associated with low intrinsic pathogenicity. Whilst almost all isolates produce extracellular products such as DNase, chitinase, lecithinase, lipase, gelatinase and siderophores, it appears that in *S. marcescens*, these products do not act as potent virulence factors (Aucken, Pitt, 1998). Nevertheless, ongoing studies indicate that *S. marcescens* may

produce other invasive factors. Almost all isolates of *S. marcescens* secrete a pore-forming haemolysin, ShIA that is associated with cell cytotoxicity and the release of inflammatory mediators (Hertle, 2005). This cytotoxin is thought to assist in tissue penetration and may be linked the expression of an extensive host invasive pathogenic pathway involving bacterial swarming and quorum sensing. *S. marcescens* isolates have also been shown to engage in cell signalling mechanisms involved in biofilm production (Shanks *et al.*, 2007). If future studies confirm the pathogenic role of biofilm in *S. marcescens*, this may correlate with other characteristics of this opportunistic pathogen including adherence, colonization and antimicrobial resistance. Until recent past a concept was there, that *S. marcescens* is rarely associated with primary invasive infection. It operates as a true opportunist producing infection whenever it gains access to a suitably compromised host. Patients most at risk include those debilitated or immunocompromised, those treated with broad-spectrum antibiotics and patients in ICU who are subjected to invasive instrumentation. Contradicting this idea, here we are reporting 2 cases of *S. marcescens* infection, none of which occurred in immunocompromised or debilitating patients or in persons admitted to hospitals. Very few case reports are there regarding community acquired *S. marcescens* infections involving immunocompetent hosts. *S. marcescens* has demonstrated an exceptional ability to acquire, transfer, and modify the expression of multiple antimicrobial resistance genes (Lockhart *et al.*, 2007).

Aminoglycoside resistance is most frequently attributed to the presence of plasmid-mediated aminoglycoside-modifying enzymes, which confer high levels of resistance to one or more aminoglycosides. Outside of enzyme inactivation, aminoglycoside resistance may also result from diminished uptake and efflux, which confer low-level resistance to all aminoglycosides. More recently aminoglycoside resistance has also been attributed to a rare mechanism involving 16S rRNA methylase-mediated ribosomal protection. Novel plasmid-mediated 16S rRNA methylase enzymes including RmtB, ArmA, RmtA, and RmtC have been identified in *S. marcescens*. These enzymes have been shown to mediate high-level resistance to several aminoglycosides, including kanamycin, tobramycin, amikacin, gentamicin, streptomycin. (Shimizu K *et al.*, 1985). Fluoroquinolone resistance in *S. marcescens* is attributable to a number of mechanisms. The main mechanism for resistance involves mutations in the *gyrA* gene which codes for the A subunit of the target enzyme, DNA gyrase. In addition to target modification, fluoroquinolone resistance may result from alterations in membrane proteins, primarily Omp1, and chromosomally-mediated resistance-nodulation-cell-division (NRD) efflux pumps (Fujimaki K *et al.*, 1989). With the widespread reliance on beta-lactam antibiotics, the frequency of resistance to these common agents has risen steadily. . This organism demonstrates most, if not all, common modes of beta-lactam resistance.

S. marcescens are inherently resistant to a range of narrow-spectrum penicillins including ampicillin, amoxicillin, amoxicillin-clavulanate, ampicillin-sulbactam and several narrow-spectrum cephalosporins. This resistance is

attributed to the presence of a chromosomal AmpC beta-lactamase enzyme. *S. marcescens* express class C, inducible AmpC beta-lactamase Jacoby GA. AmpC beta-lactamase. Expression of AmpC hampers cell wall synthesis. In wild-type isolates (uninduced state) transcription of the structural *ampC* beta-lactamase gene is repressed, thus only trace amounts of AmpC beta-lactamase enzyme are produced and resistance is restricted to narrow spectrum beta-lactam agents. In the presence of beta-lactam agents expression of AmpC is inducible and bacteria produce a transient increase in beta-lactamase production which returns to low-level when the inducer is removed. Induction per se is thus not associated with clinically significant resistance. The *ampC* gene is, however, also capable of undergoing mutation to produce a state of stable derepression or constitutive beta-lactamase overproduction. These stably-derepressed or hyperproducing mutants segregate spontaneously within the normal inducible population. Since this constitutive high-level beta-lactamase production occur independent of the presence of inducers, derepressed mutants demonstrate clinically significant cross-resistance to most beta-lactam agents including the beta-lactamase-stable broad-spectrum cephalosporins, monobactams and the beta-lactam/beta-lactamase inhibitor combinations. Broad-spectrum cephalosporins such as cefotaxime, ceftazidime, ceftriaxone and cefepime are weak inducers of the enzyme and thus remain stable against AmpC-inducible bacteria. However, this activity against inducible cells renders the drugs highly selective for the pre-existing resistant derepressed mutants that can survive and overgrow. Since the selective process occurs within days of treatment with these broad-spectrum agents, it is associated with a high rate of therapeutic failure. Once selected, these *ampC* mutants are stable & can be transferred from patient to patient.

Outside of the expression of chromosomal AmpC beta-lactamase, *S. marcescens* is also associated with production of class A plasmid-encoded beta-lactamases, such as TEM1 and SHV1, which hydrolyse penicillins and early generation cephalosporins. *S. marcescens* has also acquired a range of plasmid-mediated extended spectrum beta-lactamases (ESBLs). ESBLs are derived from mutation of classical plasmid-encoded beta-lactamases, which extend the hydrolytic spectrum of the enzymes to include broad-spectrum agents such as cefotaxime, ceftazidime and cefepime. *S. marcescens* is most frequently associated with the acquisition of CTX-M ESBLs, with studies reporting frequent production of CTX-M-3. Though other reports of *S. marcescens* carrying TEM- and SHV- type ESBLs and a novel ESBL derivative, BES-1, are also evident. One striking feature of ESBL production is that, it may show *in vitro* susceptibility concurrently with *in vivo* resistance & therapeutic failure, making it utmost important to evaluate ESBL production carefully. Until recent past, broad spectrum carbapenem beta-lactam antibiotics, such as imipenem and meropenem, resist inactivation by chromosomal AmpC and plasmid-mediated ESBL beta-lactamases. But now reports are revealing that we can't even prescribe these medications safely in case of *S. marcescens* infections as *Serratia* can express both class A chromosomal beta- carbapenemases (SEM-1, SEM-2&SEM-3) as well as class B plasmid mediated carbapenemases. This alarming situation can be attributed to injudicious use of

carbapenems. Outside of the expression of a diverse array of beta-lactamase enzymes, beta-lactam resistance in *S. marcescens* may also result from a decrease in the permeability of the outer membrane via porin mutations. Reports indicate that reduced permeability may be combined with AmpC beta-lactamase and carbapenemase production to achieve high-level cephalosporin and carbapenem resistance in *S. marcescens* (Suh B *et al*, 2010). The aim of this vivid discussion is not to create panic, but to remind ourselves that *S. marcescens* has already emerged as an important, multidrug resistant pathogen, creating a tangible cost in terms of patient morbidity and antibiotic usage. So it is essential that the clinician evaluates the antimicrobial susceptibility of clinical isolates on the basis of data supplied by the microbiology laboratory and on the clinical setting of the infection, prior to the selection of appropriate therapy, to avoid therapeutic failure.

REFERENCES

- Ananthanarayan and Paniker's Textbook of Microbiology, Enterobacteriaceae 1; 9th edition:281
- Atlee, W., Burns, R. and Oden, M. *Serratia marcescens* keratoconjunctivitis. 1970. *Am. J. Ophthalmol.*, 70: 31-33.
- Aucken, H. M. and Pitt, T. L. 1998. Antibiotic resistance and putative virulence factors of *Serratia marcescens* with respect to O and K serotypes. *J. Med Microbiol.*, 47: 1105-1113.
- Bhattacharyya, I., Konar, J., Chakraborty, A., Saha, S. and Maity, S. 2014. *Serratia marcescens* in the community : medical fraternity beware, *International journal of medical and applied sciences*,
- Byrne, A. H, Herra, C. M., Aucken, H. Keane, C. T. 2001. Rate of carriage of *Serratia marcescens* in patients with and without evidence of infection. *Scand J. Infect Dis.*, 33: 822-826.
- De Vries, J. J., Baas, W. H., Van der Ploeg, K., Heesink, A., Degener, J. E. and Arends, J. P. 2006. Outbreak of *Serratia marcescens* colonization and infection traced to a healthcare worker with long-term carriage on the hands. *Infect Control Hosp Epidemiol.*, 27: 1153-1158.
- Fujimaki, K., Fujii, T., Aoyama, H., Sato, K., Inoue, Y., Inoue, M. and Mitsuhashi, S. 1989. Quinolone resistance in clinical isolates of *Serratia marcescens*. *Antimicrob Agents Chemother*; 33: 785-787.
- Gaughran, E. R. 1969. From superstition to science: the history of a bacterium. *Trans. NY Acad. Sci.*, 31: 3-24.
- Hertle, R. 2005. The family of *Serratia* type pore forming toxins. *Curr. Protein Pept. Sci.*, 6: 313-325.
- Lockhart, S. R., Abramson, M. A., Beekmann, S. E., Gallagher, G, Riedel, S., Diekema, D. J., Quinn, J. P. and Doern, G. V. 2007. Antimicrobial resistance among Gram-negative bacilli causing infections in intensive care unit patients in the United States between 1993 and 2004. *J. Clin. Microbiol.*, 45: 3352-3359.
- Merkier, A. K., Rodríguez, M. C., Togneri, A., Brengi, S., Osuna, C., Pichel, M. and Cassini, M. H. 2013. Outbreak of a cluster with epidemic behavior due to *Serratia marcescens* after colistin administration in a hospital setting. *J. Clin. Microbiol.*, 51: 2295-2302.

- Mills, J. and Drew, D. 1976. *Serratia marcescens* endocarditis: a regional illness associated with intravenous drug abuse. *Ann Intern. Med.*, 84: 29-35.
- Patrick R. Murray, Barry Holmes, and Hazel M. Auken. *Citrobacter*, *Klebsiella*, *Enterobacter*, *Serratia* and other *Enterobacteriaceae*. Topley and Wilson's Microbiology and Microbial infections, Bacteriology Volume 2. 10th edition. 57:1487.
- Shanks, R. M., Stella, N. A., Kalivoda, E. J., Doe, M. R., O'Dee, D. M., Lathrop, K. L., Guo, F. L. and Nau, G. J. 2007. A *Serratia marcescens* OxyR homolog mediates surface attachment and biofilm formation. *J. Bacteriol.*, 189: 7262-7272.
- Shimizu, K., Kumada, T., Hsieh, W. C., Chung, H. Y., Chong, Y., Hare, R. S., Miller, G. H., Sabatelli, F. J. and Howard, J. 1985. Comparison of aminoglycoside resistance patterns in Japan, Formosa, and Korea, Chile, and the United States. *Antimicrob Agents Chemother.*, 28: 282-288.
- Sokalski, S. J., Jewell, M. A., Asmus-Shillington, A. C., Mulcahy, J. and Segreti, J. 1992. An outbreak of *Serratia marcescens* in 14 adult cardiac surgical patients associated with 12-lead electrocardiogram bulbs. *Arch. Intern. Med.*, 152:841-844.
- Suh, B., Bae, I. K., Kim, J., Jeong, S. H., Yong, D. and Lee, K. 2010. Outbreak of meropenem-resistant *Serratia marcescens* mediated by chromosomal AmpC beta-lactamase overproduction and outer membrane protein loss. *Antimicrob Agents Chemother.*, 54: 5057-5061.
- Van der Vorm, E.R. and Woldring-Zwaan, C. 2002. Source, carriers, and management of a *Serratia marcescens* outbreak on a pulmonary unit. *J. Hosp. Infect.*, 52:263-267.
- Yu, V. L. 1979. *Serratia marcescens*: historical perspective and clinical review. *N. Engl. J. Med.*, 300:887-893.
