



ISSN: 0975-833X

## RESEARCH ARTICLE

### IMAGING IN BRONCHOPULMONARY SEQUESTRATION

<sup>1</sup>Imran Nazir Salroo, <sup>2,\*</sup>Arsheed Iqbal, <sup>3</sup>Afroza Jan, <sup>4</sup>Waseem Ahmad Shah, <sup>5</sup>Fouzia Nazir and <sup>6</sup>Humaira Nazir

<sup>1</sup>Department of Radio Diagnosis & Imaging, Govt. Medical College Srinagar (J&K) India

<sup>2</sup>Scientist L-2, RRIUM/CCRUM Srinagar (J&K) India

<sup>3</sup>Kashmir Tibbya Collage (KTC) Srinagar J&k India

<sup>4</sup>Department of ENT, SKIMS Medical collage Srinagar J&K India

<sup>5</sup>Department of social and preventive medicine Govt. Medical collage Srinagar J&K India

<sup>6</sup>Senior Resident Govt Dental Collage Srinagar

#### ARTICLE INFO

##### Article History:

Received 21<sup>st</sup> July, 2015

Received in revised form

28<sup>th</sup> August, 2015

Accepted 25<sup>th</sup> September, 2015

Published online 20<sup>th</sup> October, 2015

##### Key words:

Bronchopulmonary,  
Dysplastic,  
Haemoptysis,  
Ultrasound.

#### ABSTRACT

Bronchopulmonary Sequestration is a rare congenital malformation of lower respiratory tract that lacks normal communication with the tracheobronchial tree. In 1977, Huber stated that aberrant arterial supply of sequestered lung could be encountered. The term pulmonary sequestration was first used in 1946 by Pryce. It was also termed as bronchoarterial malinosculation by Clements in 1987. It is a non functional mass composed of dysplastic lung parenchyma, embryologically detached from the tracheobronchial tree and receiving its own blood supply from a systemic artery, usually 75% from thoracic or abdominal aorta and 25% of sequestrations receive their blood flow from the subclavian, intercostals, pulmonary, pericardiophrenic, innominate, internal mammary, celiac, splenic or renal artery. The venous drainage is variable (1) computed Tomography, magnetic resonance angiography are able to demonstrate the aberrant arterial vessel feeding the sequestration. The blood supply of 75% of pulmonary sequestrations is derived from the thoracicabdominal aorta. The remaining 25% of sequestrations receive their blood flow from the subclavian, intercostal, pulmonary, pericardiophrenic, innominate, internal mammary, celiac, splenic, or renal arteries.

Copyright © 2015 Imran Nazir Salroo et al. This is an open access article distributed under the Creative Commons Attribution License, which permits unrestricted use, distribution, and reproduction in any medium, provided the original work is properly cited.

Citation: Imran Nazir Salroo, Arsheed Iqbal, Afroza Jan, Waseem Ahmad Shah, Fouzia Nazir and Humaira Nazir. 2015. "Imaging in bronchopulmonary sequestration", *International Journal of Current Research*, 7, (10), 21240-21244.

#### INTRODUCTION

Bronchopulmonary sequestration is a condition where in a piece of tissue that ultimately develops into lung tissue is not attached to the pulmonary arterial blood supply. This sequestered tissue is not connected to the normal bronchial airway. So it fails to contribute to respiration. The condition is thought to be congenital in nature and is usually diagnosed by ultrasound or prenatal ultrasound. Pulmonary sequestration is a rare congenital abnormality, with an overall incidence of 0.15 to 6.4% of all congenital pulmonary malformations. It is characterized by a mass of nonfunctioning, embryonic, cystic pulmonary tissue that receives its blood supply from the systemic circulation (Clements *et al.*, 1987) and has no connection with the bronchial tree. It preferentially affects the lower lobes, predominantly the left lower lobe. Both intralobar and extralobar sequestrations arise through the same

pathoembryologic mechanism as a remnant of a diverticular outgrowth of the foregut. Gastric or pancreatic tissue may be found within the sequestration (Zach *et al.*, 2002). The presentation is variable, ranging from no symptoms to hemoptysis. Clinically, pulmonary sequestration is latent until infection leads to symptoms. Recurrent pneumonitis of the sequestered segment, purulent sputum and haemoptysis are the prevailing symptoms (Franco *et al.*, 1998). Pulmonary sequestration can be present clinically at all ages, but most lesions tend to develop these infective complications at school age and adolescence. However, symptoms may also occur in infancy and preschool age group. A symptomatic adult has also been described (Saygi *et al.*, 2001). Many a times, it is discovered incidentally on a chest radiograph taken for another reason, as in this case. About two-thirds of all pulmonary sequestrations are found in the posterior basal segment of the left lower lobe (Halkic *et al.*, 1999). On radiograph, the initial impression is usually one of pneumonia, though the lesion may appear as air- or fluid-filled cysts, single or multiple. Till recently, aortography, with selective angiography, was usually necessary to diagnose sequestration and demonstrate its blood

\*Corresponding author: *Arsheed Iqbal*

Scientist L-2, RRIUM/CCRUM Srinagar (J&K) India

supply. CT scanning and recently spiral CT angiography offer less invasive means of demonstrating the anomalous vascular supply (Kang *et al.*, 2006). Surgical excision is usually curative; it should be conservative, sparing the normal lung parenchyma (Bonnard *et al.*, 2004). Some authors advocate embolisation of the aberrant systemic artery at the time of initial catheterisation, which may result in complete radiological resolution of mass (Walsh, 2005 and Saida *et al.*, 2006).

### Anatomical Classification

Intralobar sequestration (ILS) in which the lesion is located within a normal lobe and lacks its own visceral pleura. Extralobar sequestration (ELS) in which the mass is located outside the normal lung and has its own visceral pleura.

### Intralobar Sequestration

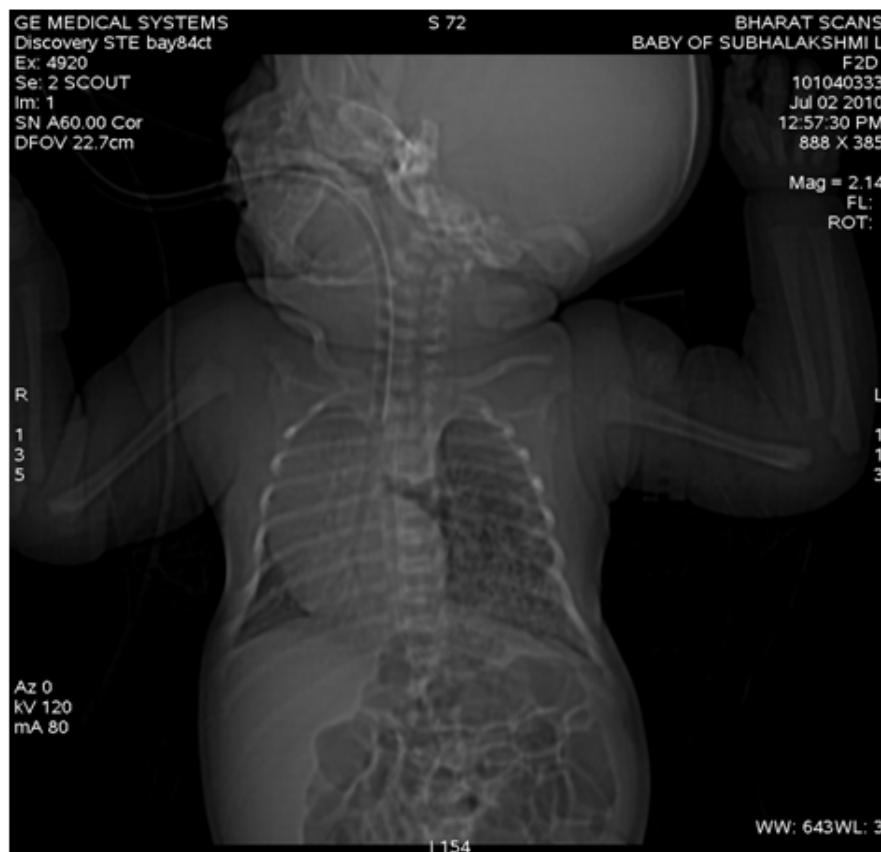- The intralobar variety accounts for 75 percent of all sequestrations.
- Usually presents in adolescence or adulthood as recurrent pneumonias.
- The lung tissue lies within the same visceral pleura as the lobe in which it occurs.
- Males and females are equally affected with ILS.
- In ILS, the arterial supply usually is derived from the lower thoracic or upper abdominal aorta.
- Venous drainage is usually to the left atrium via pulmonary veins establishing a right to left shunt.

- Abnormal connections to the vena cava, azygous vein, or right atrium may occur.
- Abnormal connections to the vena cava, azygous vein, or right atrium may occur.
- Two thirds of the time, the sequestration is located in the paravertebral gutter in the posterior segment of the left lower lobe.
- Unlike extralobar sequestration, it is rarely associated with other developmental abnormalities.
- Patients present with signs and symptoms of pulmonary infection of a lower lobe mass.
- It is believed that sequestrations become infected when bacteria migrate through the Pores of Kohn or if the sequestration is incomplete.

### Extralobar Sequestration

- The extralobar variety accounts for 25 percent of all sequestrations.
- ELS usually presents in infancy with respiratory compromise.
- Develops as an accessory lung contained within its own pleura.
- ELS has a male predominance (80%).
- Related to the left hemidiaphragm in 90% of cases.
- ELS may present as a subdiaphragmatic or retroperitoneal mass.
- In general, the arterial supply of ELS comes from an aberrant vessel c/c aorta.
- It usually drains via the systemic venous system to the right atrium, vena cava, or azygous systems.
- Congenital anomalies occur more frequently in patients with ELS than ILS.

2 months baby came with the history of cystic lesion in the left lung during routine antenatal ultra Sonography (USG)



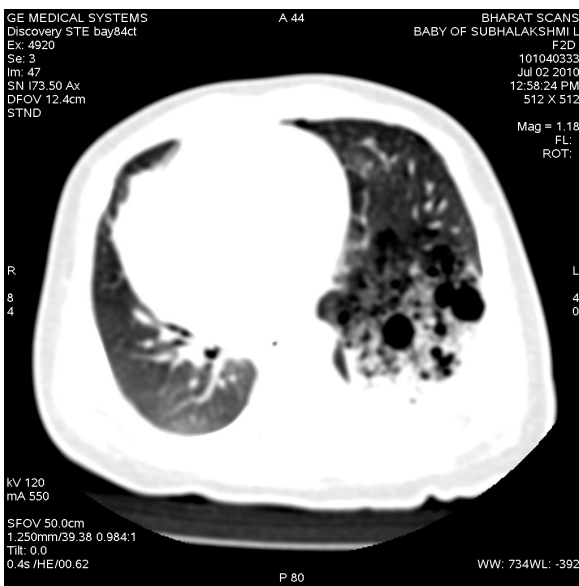
- Associated anomalies include Congenital cystic adenomatoid malformation (CCAM), congenital diaphragmatic hernia, vertebral anomalies, congenital heart disease, pulmonary hypoplasia, and colonic duplication
- Since it is enveloped in its own pleural sac, it rarely gets infected so almost always presents as a homogeneous soft tissue mass.
- The mass may be closely associated with the esophagus, and fistulae may develop.

**Case Report**

**Radiograph Chest and Abdomen AP View Showing**

- Nasogastric and tracheal tube seen in situ.
- Bronchiectatic change like appearance in left middle and lower zone.
- Cardiac shadow is not seen on the left side.
- Mediastinal shift to right.
- Tracheal shift to right.
- Thymus appears enlarged and displaced to right side and merging with right cardiac border.
- Left main bronchus appears dilated.
- Minimal pneumothorax noted on left side.
- Left dome of diaphragm appears flattened.

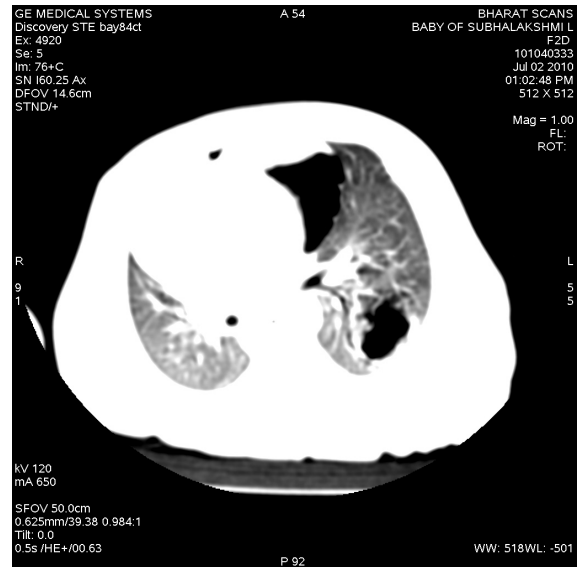**Non Contrast Enhanced CT**



Heterogeneous partially aerated mass in the posterior aspect of the left hemithorax, consisting of cyst like air spaces of varying sizes interspersed between solid tissue components with no communication with the bronchial tree.

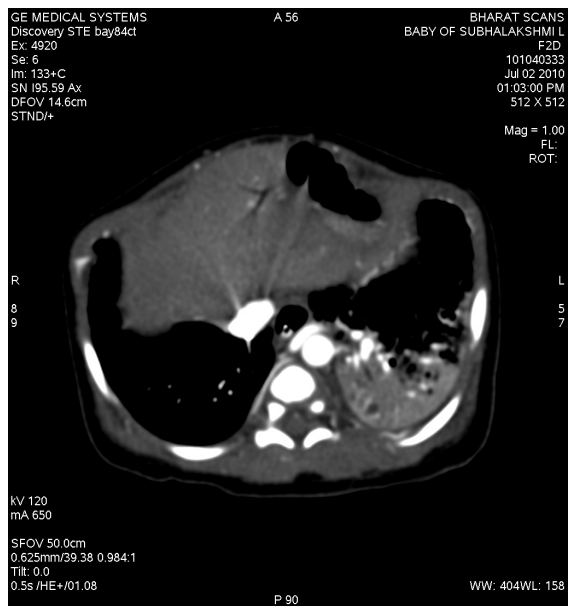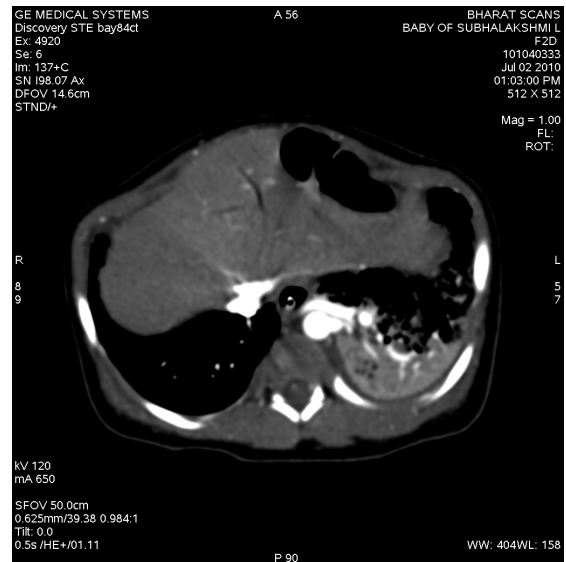
**Sonography**

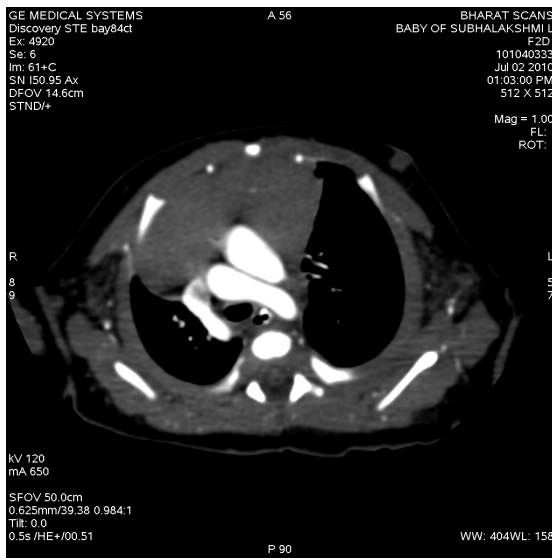Ultrasound evaluation is ideally suited for evaluation in the antenatal period or in neonates. (Thind *et al.*, 1985, May *et al.*, 1993) Sequestration should be considered in the differential diagnosis in any fetus with a lung mass. The lesion usually has a homogeneously echogenic appearance on ultrasound, but may show cystic changes (Felker *et al.*, 1990).



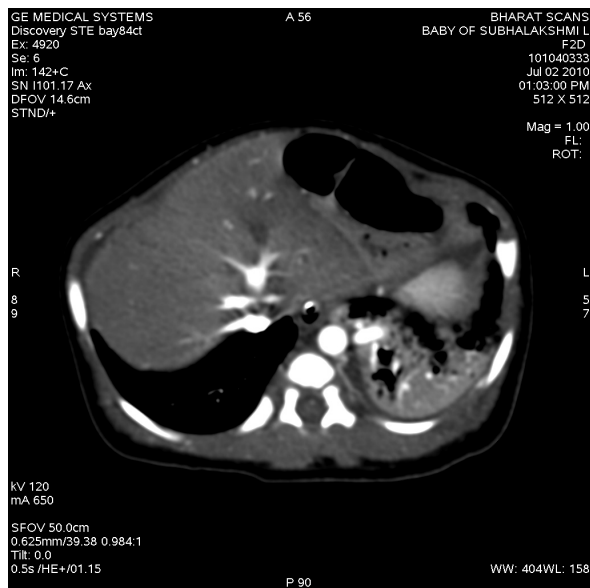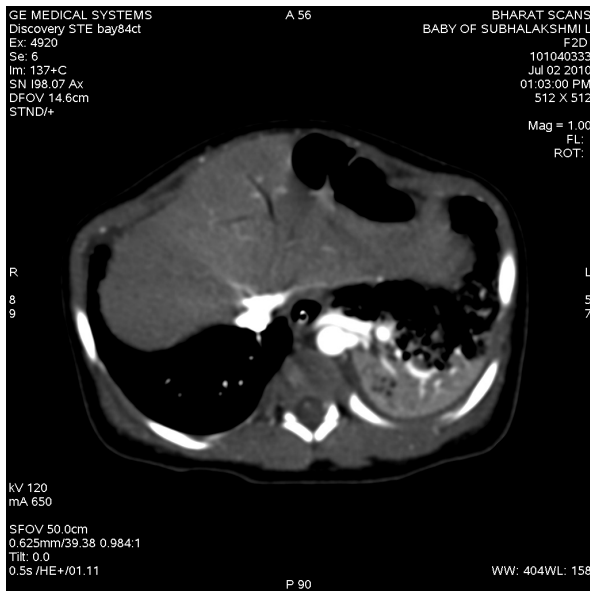Pneumo thorax noted along the anterior aspect of right middle lobe, anteromedial aspect of the left upper lobe

**Contrast Enhanced CT**



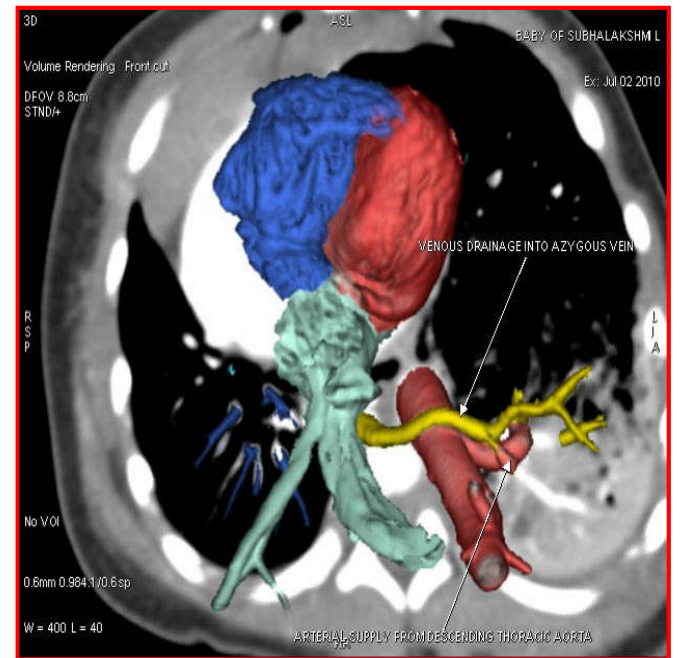
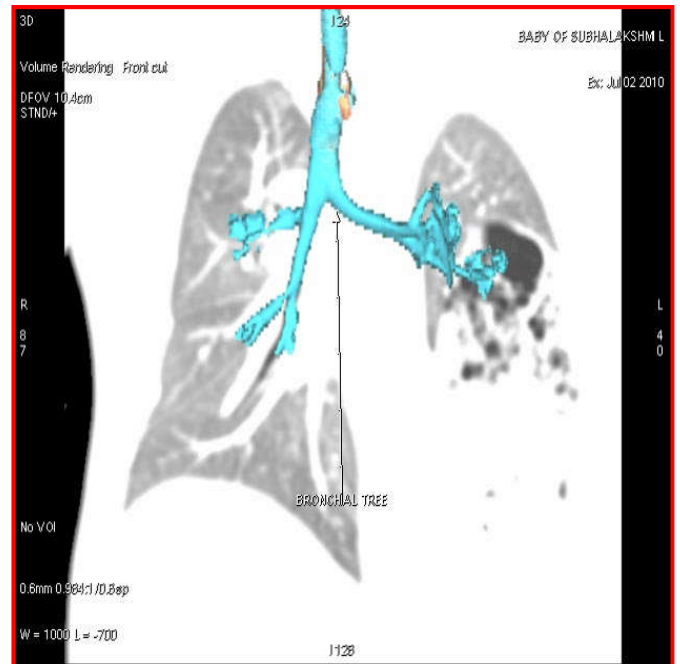


Venous drainage of heterogenous lung tissue via draining vein crossing anterior to the descending thoracic aorta into the azygous vein.



Arterial supply for heterogenous lung tissue derived from single branch arising from the descending aorta.

3D And MPV Reconstruction



Doppler ultrasound may be useful for evaluation of the supplying systemic artery. (Deeg *et al.*, 1992) However, a small aberrant systemic artery may not be identified and the acoustic window may be impaired by surrounding air-filled lung or the bony thorax.

DISCUSSION

The anomalous blood supply of a pulmonary sequestration is the clue to its diagnosis. Identification was traditionally made, as in case report 1, by intra-arterial DSA. Currently, minimally invasive angiographic techniques such as CT and MR

angiography are also able to demonstrate the aberrant arterial vessel feeding the pulmonary sequestration, as described in the second case. Three-dimensional reconstruction techniques such as maximum-intensity-projection (MIP) or more recently volume rendering (VR) are useful, with the last method having the advantage of displaying simultaneously several ranges of tissue densities. It is now accepted that intra-arterial angiography is no longer mandatory to achieve the diagnosis of these malformations (Pryce *et al.*, 1946) but instead should be reserved for the few cases in which embolization is contemplated (Clements *et al.*, 1987). The differential diagnosis of pulmonary sequestrations is extensive, and is modified by the age at presentation. In the newborn other entities should be ruled out, such as congenital diaphragmatic hernia, intrapulmonary bronchogenic cyst, cystic adenomatoid malformation or bronchial atresia. Later on life, several tumours and tumour-like conditions must be excluded including broncho pulmonary neoplasia, bronchiectasis or arteriovenous fistula (Rosado *et al.*, 1993)

### Treatment

Usually the sequestration is removed after birth via surgery. In most cases this surgery is safe and effective; the child will grow up to have normal lung function. In a few instances, fetuses with sequestrations develop problematic fluid collections in the chest cavity. In these situations a Harrison catheter shunt can be used to drain the chest fluid into the amniotic fluid. In rare instances where the fetus has a very large lesion, resuscitation after delivery can be dangerous. In these situations a specialized delivery for management of the airway compression can be planned called the EXIT procedure, or a fetal laser ablation procedure can be performed. During this minimally invasive fetal intervention, a small needle is inserted into the sequestration, and a laser fiber is targeted at the abnormal blood vessel going to the sequestration. The goal of the operation is to use laser energy to stop the blood flow to the sequestration, causing it to stop growing. Ideally, after the surgery, the sequestration steals less blood flow from the fetus, and the heart and lungs start growing more normally as the sequestration shrinks in size and the pleural effusion goes away.

### Conclusion

Pulmonary sequestration is a heterogeneous group of lesions with anomalous connections between the various components of the lung. The primary role of imaging in an individual patient is to depict the aberrant vascular anatomy for diagnosis and accurate surgical planning. A high index of suspicion is required, both by the clinician and the radiologist, in making a presumptive diagnosis. Any persistent intrapulmonary opacity in the lower lobes of a child or young adult, on a chest radiograph, should prompt further evaluation with cross-sectional imaging. Non-invasive CT and MR angiographic techniques are useful for depiction of vascular anatomy. Multi detector CT angiography, which allows simultaneous imaging of the aberrant vascular anatomy as well as the lung parenchyma, has now become the first-line examination in the preoperative assessment of pulmonary sequestration. Diagnostic catheter angiography is only required in select problematic cases.

### REFERENCES

- Felker, R.E. Tonkin, I.L. 1990. Imaging of pulmonary sequestration. *Am J Roentgenol* ;154:249.
- Clements, B.S., Warner, J.O. 1987. Pulmonary sequestration and related congenital bronchopulmonary vascular malformations: nomenclature and classification based on anatomical and embryological considerations. *Thorax*; 42:401–8.
- Zach, M.S., Eber, E. 2002. Adult outcome of congenital lower respiratory tract malformations. *Arch Dis Child* ;87:500–5.
- Franco, J., Aliaga, R., Domingo, M.L., *et al.* 1998. Diagnosis of pulmonary sequestration by spiral CT angiography. *Thorax* ;53:1089–92.
- Saygi, A., Lewis, M.M., Tsou, E. 2001. Intralobar pulmonary sequestration. *Chest* ;119:990–2. |
- Halkic, N., Cuenoud, P.F., Corthesy, M.E., *et al.* 1999. Pulmonary sequestration: a review of 26 cases. *Eur J Cardiothorac Surg* 1999;14:127–33.
- Kang, M., Khandelwal, N., Ojili, V., Rao, K.L., Rana, S.S. Multidetector, C.T. 2006. angiography in pulmonary | sequestration. *J Comput Assist Tomogr*;30(6):926–
- Bonnard, A., Malbezin, S., Ferkdadjji, L., Luton, D., Aigrain, Y, de Lagauise, P. 2004. Pulmonary sequestration children: is the thoracoscopic approach a good option? *Surg Endosc* ;18(9):1364–7.
- Walsh, K.P. 2005. Advanced embolization techniques. *Pediatr Cardiol* 2005;26(3):275–88.
- Saida, T., Ninomiya, H., Hojo, F., Nakayama, M., Yamauchi, T., Saida, Y. Systemic arterial supply to the normal basal segments of the left lower lobe treated by coil embolization, with long-term follow-up. *Radiat Med* 2006;24(5):365–8.
- Thind, C.R., Pilling, D.W.1985. Pulmonary sequestration: the value of ultrasound. *Clin Radiol* 1985; 36: 437–9.
- May, D.A., Barth, R.A., Yeager, S., Nussbaum-Blask, A., Bulas,D.I. 1993. Perinatal and postnatal chest sonography. *Radiol Clin North Am* 1993; 72: 465–7.
- Deeg, K.H., Hofbeck, M., Singer, H. 1992. Diagnosis of intralobar lung sequestration by colour-coded Doppler sonography. *Eur J Pediatr* ; 151: 710–12.
- Pryce, D.M. 1946. Lower accessory pulmonary with intralobar sequestration of lung: report of seven cases. *J Pathol*; 58: 457–67.
- Clements, B.S., Wamer, J.O. 1987. Pulmonary sequestration and related congenital bronchopulmonary-vascular malformations: nomenclature and classification based on anatomical and embryologic considerations. *Thorax*1987; 42: 401–8.
- Rosado de Christenson, M.L., Frazier, A.A., Stocker, J.T., Templeton, P.A. 1993. Extralobar sequestration: radiologic-pathologic correlation. *Radiographics.*, 13:425–41.

\*\*\*\*\*