



ISSN: 0975-833X

CASE REPORT

MODIFIED COMPLETE DENTURE FOR ACQUIRED MAXILLARY DEFECT: A CASE REPORT

¹Dr. Dolanchanpa Dasgupta, ²Dr. Saibal Kumar Sen, ³Dr. Sneh Nidhi and ^{*4}Dr. Md Rabiul Islam

¹Department of Prosthodontics, Guru Nanak Institute of Dental Science & Research (GNIDSR), West Bengal, India

²Department of Prosthodontics, Guru Nanak Institute of Dental Science & Research, West Bengal, India

³Department of Periodontics, ITS Dental College, Hospital and Research Centre, Greater Noida, India

⁴Department of Prosthodontics, Hazaribag College of dental sciences and hospital, Jharkhand, India

ARTICLE INFO

Article History:

Received 11th August, 2015

Received in revised form

23rd September, 2015

Accepted 10th October, 2015

Published online 30th November, 2015

ABSTRACT

Primary resection and radiotherapy for oral carcinoma present a myriad of challenges during prosthetic rehabilitation. A 65 years old lady developed microstomia, post-radiation xerostomia, altered muscle attachments following subtotal maxillectomy involving the entire premaxilla. Here, standard procedure for rehabilitation was tried with hollow complete denture. The final outcome of the functional prosthesis proves that simple prosthetic rehabilitation modified in harmony to her post-morbid condition can provide the best option for treating such elderly patients.

Key words:

Hollow complete denture,
Maxillectomy, Implant overdenture,
Elderly patient.

Copyright © 2015 Dr. Dolanchanpa Dasgupta et al. This is an open access article distributed under the Creative Commons Attribution License, which permits unrestricted use, distribution, and reproduction in any medium, provided the original work is properly cited.

Citation: Dr. Dolanchanpa Dasgupta, Dr. Saibal Kumar Sen, Dr. Sneh Nidhi and Dr. Md Rabiul Islam, 2015. "Modified complete denture for acquired maxillary defect : a case report." *International Journal of Current Research*, 7, (11), 23323-23326.

INTRODUCTION

Primary resection for oral squamous cell carcinoma presents a myriad of challenges during rehabilitation of oral function in the post-morbid state. Maxillectomy leaves the patient with an anatomical defect of palate which usually results in severe limitations on speech, mastication, and swallowing. The loss of supporting structures may also cause considerable facial collapse. (Ansgar C. Cheng et al., 2008) The functional and esthetic problem directly affect the psychological well being of the patient. Restricted mouth opening, muscle fibrosis, xerostomia etc are often caused by surgically-treated head and neck tumors and radiation therapy. (Ansgar C. Cheng et al., 2008) The prime objective of treatment is immediate and effective rehabilitation that facilitates physical and psychological recovery and can restore some function and esthetics.

Clinical Report

A 65 yrs old lady reported with a history of squamous cell carcinoma of the premaxillary region for which she had subtotal maxillectomy six months ago.

***Corresponding author: Dr. Md Rabiul Islam,**

Department of Prosthodontics, Hazaribag College of dental sciences and hospital, Jharkhand, India.

She had extensive radiotherapy, three months back as a part of her treatment. Extraoral examination revealed facial deformity resulting from depressed premaxillary region, lack of lip support. She had restricted mouth opening (22 mm interalveolar distance measured in the incisor region) (Cristoph Runte et al., 2001), and deviation of mandible toward left while closing from maximum opening. Tone of muscles of mastication and facial expression was maintained. She also presented limitation of eccentric mandibular movements, and overall jaw immobility as a result of microstomia and fibrosis of muscles of mastication. Intraoral examination revealed fully edentulous upper and lower ridge, absence of bone and labial sulcus in the upper anterior region, altered cicatrized muscle attachments affecting the anterior sulcus area of the upper arch and also causing hypomobility of the upper lip.

Available bone was the remaining residual ridge extending from second premolar to maxillary tuberosity bilaterally and a portion of hard palate with presence of sulcus area in the posterior upper arch. She was also suffering from post-radiation xerostomia. Anatomic deformity as well as altered intraoral physiology presented a challenge to the prosthetic rehabilitation. Success of the prosthesis was related directly to the amount of the remaining bone and soft tissue architecture which imparts poor retention to the prosthesis.

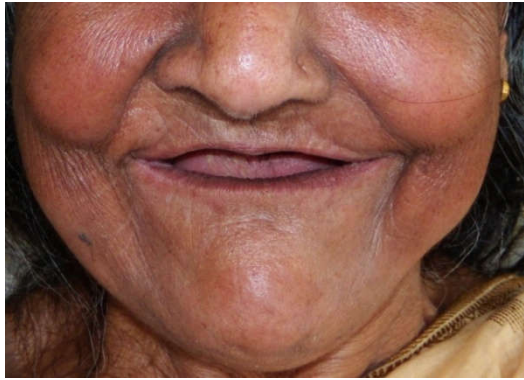


Fig. 1. The edentulous patient

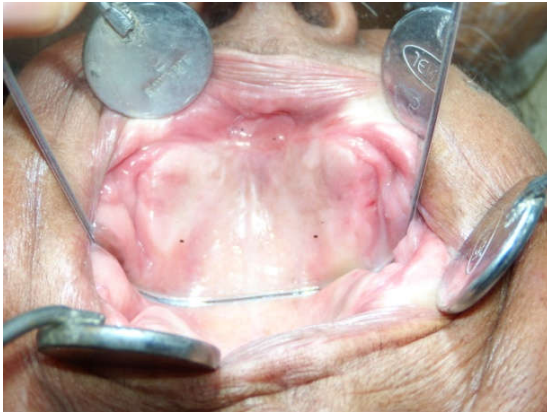


Fig. 2. Maxillary edentulous ridge

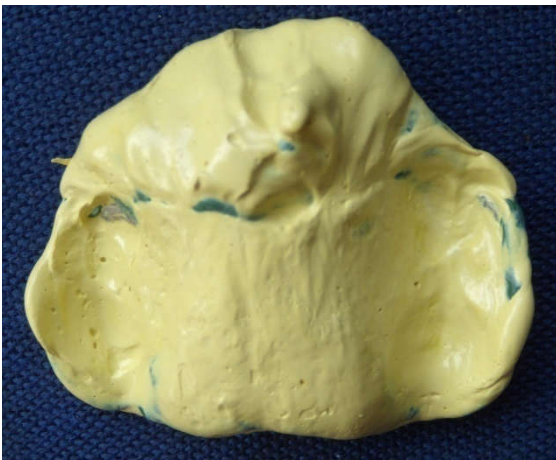

Fig. 3. Maxillary final impression



Fig. 4. Model of upper arch

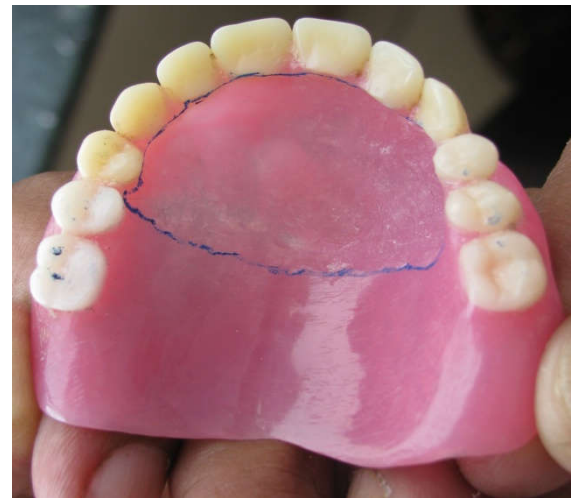

Fig. 5. Denture with Hollow Area

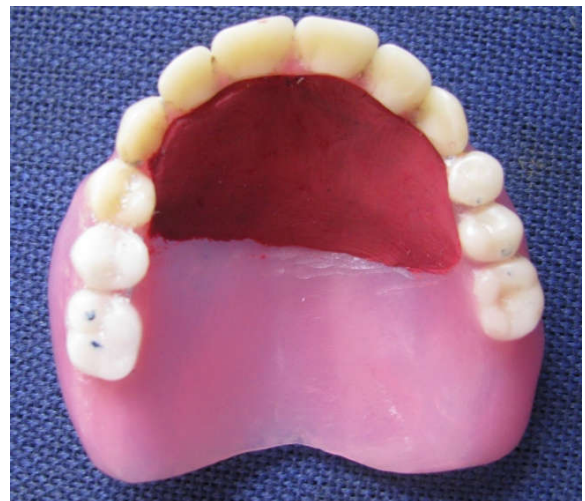

Fig. 6. Hollow area covered with modelling clay

Tissue molding was critical as well as difficult in the affected labial-buccal sulcus area. The treatment of an edentulous ridge using an implant-supported overdenture is a well accepted treatment modality, having the advantage of osseointegration which can enhance retention and stability of the denture. (Jeffrey Bennett and Thomas D. Taylor, 1998) But here implant could only be placed posteriorly, bilaterally. There was dearth of bony foundation in the premaxillary region where the nearest bone was the nasal floor making it difficult for implant placement. The interarch distance and the vertical dimension of the patient was not enough to accommodate implant supported overdenture. Moreover the existing bone was irradiated only about 3 months back.

It has been shown that not all endosseous implants placed in irradiated tissues have a high success rate. Head and neck radiation therapy has been associated with delayed healing and development of osseoradionecrosis. (Ansgar C. Cheng *et al.*, 2008; Jeffrey Bennett and Thomas D. Taylor, 1998)

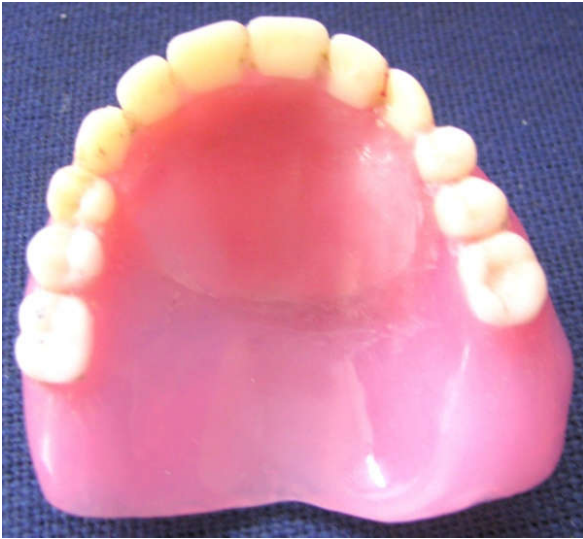

Fig. 7. Denture with Lip

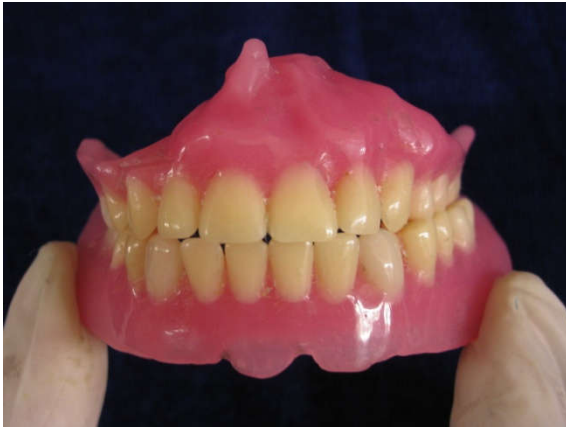

Fig. 8. Complete denture

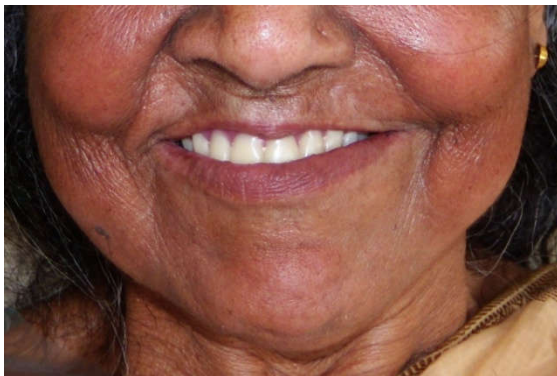


Fig. 9. Post Denture insertion

It is an established fact that the maxilla is less radioresistant than mandible. (Jeffrey Bennett and Thomas D. Taylor, 1998) She had received a dose of 55 Gy radiation in 30 consecutive sessions which was on the higher side and predisposed the jaw bones to, hypocellularity, hypovascularity and hypoxia. (Jeffrey Bennett and Thomas D. Taylor, 1998) This tissue alteration can be amplified by any surgical intervention which can lead to development of osteoradionecrosis. (Ansgar C. Cheng *et al.*, 2008; Ansgar C. Cheng *et al.*, 2008; Jeffrey

Bennett and Thomas D. Taylor, 1998), Also the waiting period, length of delay between irradiation and implantation is necessary so that the vascularization can be partly recovered and neo-osteogenesis appears. (Jeffrey Bennett and Thomas D. Taylor, 1998)

The accepted waiting period suggested by different literatures is minimum 6 months to 2 yrs with a higher preference for 2yrs. (Jeffrey Bennett and Thomas D. Taylor, 1998) Implants can be placed in a setting of irradiation if radiation is given 5-6 weeks after placing implants or the patient is subjected to intensity modulated radiation therapy or provided proper prophylactic hyperbaric oxygen therapy. (Ansgar C. Cheng *et al.*, 2008; Jeffrey Bennett and Thomas D. Taylor, 1998) It has been found that the endosseous implants have a low degree of predictability in maxilla even if adjunctive HBO is used. HBO can enhance the vascularity of irradiated bone but it does not improve their capacity for remodelling. (Ansgar C. Cheng *et al.*, 2008; Jeffrey Bennett and Thomas D. Taylor, 1998) However, in this case the patient was not treated with those safeguards. Finally the financial affordability was an important parameter in considering the choice of prosthesis. Considering the above, it was decided to discard implant retained prosthesis in favour of a complete denture with modified premaxillary area.

Complete Denture has the advantage of the stabilizing potential of existing muscle conditions and serve to structurally redefine true spaces and potential spaces within the oral cavity. In this patient a complete denture with a modified premaxillary area provides a proper prosthesis that is maintained by the associated neuromusculature for optimum function. The cicatrized muscles created problem during fabrication of the denture and exerted pressure on the polished labial surface. Again the same factor helped because of the lesser movement of the local muscles. The protocol and method of fabrication of denture was approved by the ethical review board of the institution. The impression was recorded with impression compound and a prefabricated special tray after removing the anterior portion of the tray. Border moulding was performed meticulously in function as recording the activity of lip muscles or capturing the altered muscle pattern was crucial in the case of difficult denture retention conditions. Centric relation was recorded at a reduced vertical dimension of occlusion to improve food entry at the anterior area. (Ansgar C. Cheng *et al.*, 2008)

It is well established that when the oral opening is small, the mandible primarily functions in a hinge manner, with limited translatory, protrusive, and lateral movements. Therefore, in this situation, eccentric interocclusal records and programming of the condylar elements of the articulator are not required. A simple free-plane articulator was selected for mounting the casts. (Ansgar C. Cheng *et al.*, 2008) Arrangement of the teeth was done in accordance to the residual ridge and the neutral zone. Patient had a deviated path of mandibular closure more to the left that demanded a selective arrangement of teeth in Class III on the left side, Class I on the right and Edge - to - edge or Class III in the front since the premaxilla was missing. Final adjustments were made at the try-in stage and the finished prosthesis was remounted for occlusal adjustments.

Utmost care was taken to produce highly polished surface of the denture to utilize the stabilizing potential of existing muscle conditions.

After insertion of the denture, speech problem, especially with the palatal phonemes were noticed. At this stage significant reduction of weight of the upper denture was done by making the denture base hollow in the premaxillary area. After necessary trimming the hollow area was filled up with modeling clay and wax pattern for the lid of the bulb was prepared covering the defect. Then the wax lid was arcylized using heat polymerizing acrylic resin. After cleaning the modeling clay, the lid was joined with the denture using autopolymerizing acrylic resin. (el Mahdy, 1969) There was immediate improvement of speech. The post-insertion esthetics and occlusion on the whole was very satisfactory. Patient was instructed to use artificial saliva. She was advised a periodic follow up after twenty four hrs then after forty eight hours followed by four times in the first year. (Beumer et al., 1996) She has been followed up for one year since the insertion of the denture. It was obvious that the esthetics and functions are well established with the rehabilitation.

DISCUSSION

Oral conditions of treated cancer patients are often severely compromised causing difficulties for prosthetic rehabilitation. Financial constraint of these patient sometimes play pivotal role in the treatment plan, specially while treating patient with a low socio-economic background. Moreover general medical condition of the patient and also oral condition of such patient may go against any complex treatment procedure like implant supported prosthesis. Simple treatment modalities like conventional dentures with little modifications can rehabilitate the defect physically and functionally as well as add positively to their quality of life, mental health and social rehabilitation.

The autopolymerizing acrylic resin used for joining the lid with the hollow denture may be a concern from the point of view of possible potential irritation, toxic and allergic reaction. The denture was soaked in water for 3 days before delivering to patients to reduce the amount of released free monomers. (Rose et al., 2000)

REFERENCES

- Ansgar C. Cheng, Tapan N. Koticha, Neo Tee-Khin and Alvin G. Wee, 2008. Prosthodontic management of an irradiated maxillectomy patient with severe trismus using implant-supported prostheses: A clinical report, *J. Prosthet. Dent.*, 99:344-350
- Beumer, J. 3rd, Curtis, T.A. and Marunick, M.T. 1996. Maxillofacial rehabilitation: prosthodontic and surgical considerations. 1st ed. St Louis (MO): Ishiyaku EuroAmerica, Inc; p87
- Cristoph Runte, Bettina Runte, Dieter Driksen, Friedhelm Bollmann, Oliver Micke, Ulrich Schafer and Normann Willich, 2001. A Pivoting Appliance for intracavitary Brachytherapy in Patients with Reduced Mouth Opening, *Int. J. Prosthodont.*, 14:178-182
- El Mahdy, A.S. 1969. Processing a hollow obturator. *J. Prosthet. Dent.*, 22: 682-6.
- Jeffrey Bennett, Thomas D. Taylor, 1998. Dental Implants, *The Dental Clinics of North America*, 42(1) : 41-42,177-194,
- Rose, E.C., Bumann, J., Jonas, I.E., et al. 2000. Contribution to the biological assessment of orthodontic acrylic materials. Measurement of their residual monomer output and cytotoxicity. *J. Orofac. Orthop.*, 61:246-257
