



## RESEARCH ARTICLE

### ACCESSORY RENAL ARTERIES AND ASSOCIATED VARIATIONS IN THE ARRANGEMENT OF STRUCTURES AT THE HILUM OF THE KIDNEY – A CADAVERIC STUDY

<sup>1</sup>Shamima Banoo, <sup>2</sup>Gh. Mohd Bhat, <sup>2,\*</sup>Mohd.Saleem Itoo, <sup>3</sup>ShaheenShahddad, <sup>1</sup>Zahid Bashir, <sup>1</sup>Parveen Akhter, <sup>4</sup>PanditTafiq Johan and <sup>5</sup>Gosia Nissa

<sup>1</sup>Lecturer, Department of Anatomy Government Medical College Srinagar, J&K, India

<sup>2</sup>Associate Professor, Department of Anatomy Government Medical College Srinagar, J&K, India

<sup>3</sup>Professor and Head, Department of Anatomy Government Medical College Srinagar, J&K, India

<sup>4</sup>Senior Resident at, Department of Medicine at Government Medical College Srinagar, India

<sup>5</sup>Postgraduate Scholar, Department of Medicine at Government Medical College Srinagar, India

#### ARTICLE INFO

##### Article History:

Received 25<sup>th</sup> October, 2015

Received in revised form

16<sup>th</sup> November, 2015

Accepted 11<sup>th</sup> December, 2015

Published online 31<sup>st</sup> January, 2016

##### Key words:

Abdominal aorta,  
Accessory renal artery,  
Coeliac trunk,  
Interventional Radiology,  
Renalartery,  
Renal pelvis.

#### ABSTRACT

The present study was done in the department of Anatomy at Government Medical College Srinagar to study the variations in the arrangement of structures at the hilum of kidney and their clinical significance. 30 kidneys (n:2) from 15(n:1) formalin preserved cadavers were taken for this study and anatomical variations of renal arteries and arrangement of structures at the hilum of each kidney was studied. It was observed that in one of the cadavers with supernumerary renal arteries arrangement of structures in the hilum of right kidney was arteries, vein and renal pelvis from anterior to posterior in contrast to the usual arrangement of vein, artery and renal pelvis. In this cadaver we found that renal right renal artery after originating from abdominal aorta at the level of first Lumbar vertebra divided into three branches. The superior branch (S) entered the upper pole of kidney, middle (M) and inferior branch (I) made their entry through the hilum but anterior to renal Vein. The inferior suprarenal artery (ISA) originated from superior the superior branch common renal artery (S). The origin and course and branching pattern of renal vessels on the left side of this cadaver was normal. In this series we do not found any accessory renal artery originating from coeliac trunk, superior mesenteric artery or common iliac artery. Though anomalies of renal artery are very common but usually the arrangement of structures at the hilum remains unchanged. The knowledge of this rare anomaly with change in pattern of structures at the renal hilum is very useful in Interventional Radiology/ Cardiology, planning laparoscopic renal transplants and urological surgeries with better prognosis.

Copyright © 2016 Shamima Banoo et al. This is an open access article distributed under the Creative Commons Attribution License, which permits unrestricted use, distribution, and reproduction in any medium, provided the original work is properly cited.

**Citation:** Shamima Banoo, Gh. Mohd Bhat, Mohd.Saleem Itoo, ShaheenShahddad, Zahid Bashir, Parveen Akhter, PanditTafiq Johan and Gosia Nissa, 2016. "Accessory renal arteries and associated variations in the arrangement of structures at the hilum of the kidney – A cadaveric study", *International Journal of Current Research*, 8, (01), 25644-25647.

## INTRODUCTION

Classically arterial supply of each kidney comes from single renal artery from (Beregi et al., 1999; Özkan et al., 2006) in only 25 percent of individuals (Awojobi et al., 1983; Çiçekcibaşı et al., 2005). Variations in arterial supply of kidney are very common. Usually variations are in the form its origin; number and unusual branching pattern

(Dhar and Lal, 2005; Gray's Anatomy, 2008; Rusu, 2006; Shoja et al., 2008; Krishnasamy et al., 2010; Sampaio and Passos, 1992). Various terms like supplementary, accessory, aberrant are used in the literature for these variations. A sound anatomical knowledge of these anatomical variations is essential for surgeons for planning renal transplantation, repair of abdominal aortic aneurysm and also may prove very useful for urologists and radiologists to plan urological and interventional procedures (Nathan and Glezer, 1984; Satyapal et al., 2001; Anson et al., 1936) A Single renal artery to each kidney is present in about 70 percent of individuals (Gray's Anatomy, 2008). The renal arteries are paired lateral

\*Corresponding author: Mohd.Saleem Itoo,

Associate Professor, Department of Anatomy Government Medical College Srinagar, J&K, India.

branches from abdominal aorta given just below the origin of superior mesenteric artery. The right renal artery is longer and given at a higher level than the left. After its origin the right renal artery passes posterior to inferior vena cava, right renal vein, head of pancreas and descending part of the duodenum. The left renal artery passes behind the left renal vein. However the level of origin, caliber and obliquity and relation may vary. Besides kidney renal arteries also supply surrounding structures and give following branches in their extra renal course. One or more inferior suprarenal arteries, a branch to upper third of ureter and small branches to supply perinephric tissue, the renal capsule and pelvis. Near the hilum each renal artery divides into an anterior and posterior division and these into segmental arteries supplying the renal vascular segments (Gray's Anatomy, 2008). Accessory renal arteries are present in 30% of individuals. They usually originate from abdominal aorta either above or below the main renal artery and follow it to main renal hilum. These accessory renal vessels are regarded as persistent embryonic lateral splanchnic arteries. Accessory inferior polar vessels usually cross anterior to the ureter, obstruct it and lead to hydroureter and hydronephrosis. Rare sites for origin of accessory renal arteries include celiac trunk, superior mesenteric artery, near aortic bifurcation or from common iliac arteries. Each kidney is drained by renal vein which lies posterior to renal artery. The tributaries of left renal vein are left gonadal and left inferior suprarenal veins and on the right side right gonadal vein opens into inferior vena cava.

## MATERIALS AND METHODS

The present study was carried out in the department of Anatomy at Government Medical College Srinagar J & K, India. Thirty kidneys (n=2) from 15 formalin preserved cadavers (n=1) were taken for this study. The study was aimed to observe the accessory renal arteries and variations in the arrangement of vascular structures at the hilum of kidney and their relation with renal pelvis. Abdominal dissection was done following instructions given in the Cunningham's manual of Practical Anatomy, during routine dissection for teaching undergraduate and postgraduate medical students. Other abdominal viscera were taken out and preserved in formalin. Special attention was given to origin, course and branching pattern renal arteries and their relation with renal vein and pelvis at the hilum. Appropriate photographs of variations were taken and labeled.

## Observations

Renal artery is known for its variations. In our present study we found that Supernumerary renal arteries are present 30% of cases. They usually originate from abdominal aorta and also from renal arteries. As shown in Fig, (1), in one of the cadavers we observed that right common renal artery originated from abdominal aorta just below the superior mesenteric artery as usual. This vessel then divided into 3 major branches, we labeled them as Superior (S) for upper pole of right kidney. This vessel gave a small branch to the right suprarenal gland (inferior supra renal artery). The other two major branches labeled as middle (M) and inferior branch (I) from common renal artery entered the hilum of right kidney but in front of renal pelvis with renal vein in between these two structure as

shown in Fig, (1). This is in contrast to the usual pattern where relation is vein, artery and renal pelvis from anterior to posterior.

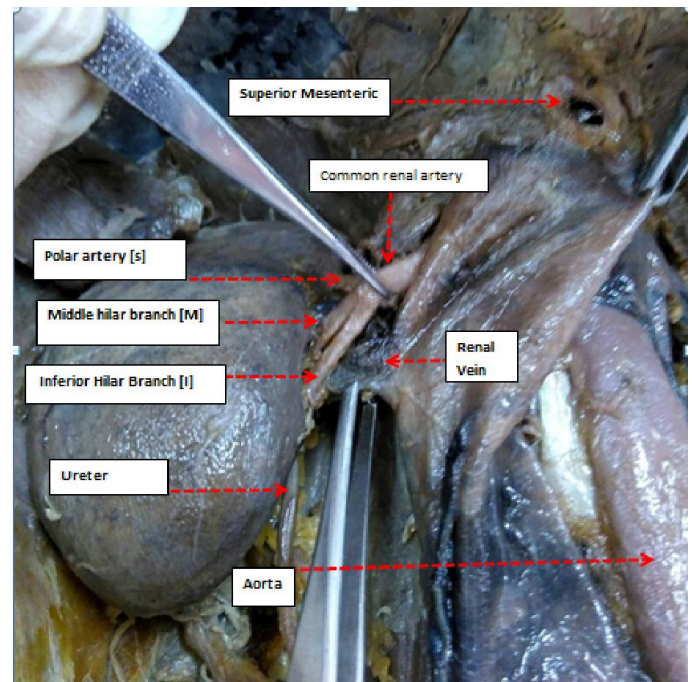


Fig. 1. Common renal artery originating from aorta just below the superior mesenteric artery, it divides into 3 major branches. Superior [S] for upper pole, middle [M] and inferior [I] enter kidney at hilum. Arrangement of structures from anterior to posterior is accessory renal arteries, vein and renal pelvis

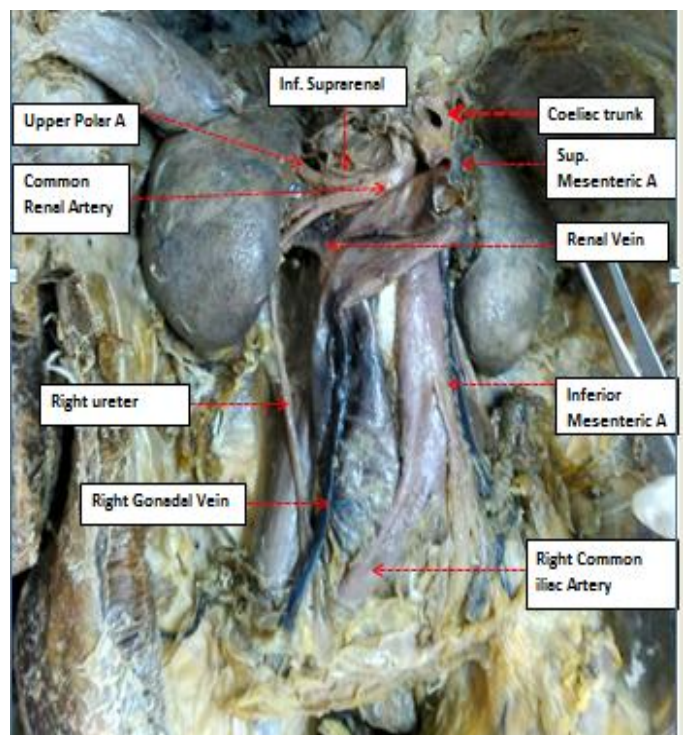


Fig. 2. Origin of inferior suprarenal artery from the upper polar branch of the Common renal artery and altered arrangement of structures at renal hilum (accessory renal arteries, Renal Vein and Renal Pelvis) from anterior to posterior

We did not find any supernumerary renal artery arising from coeliac trunk, superior mesenteric artery or common iliac artery in our present study. The origin, course and relations of renal artery on the left side of this cadaver was normal.

## DISCUSSION

Renal artery is notorious for variations which are present in 30% of cases (Gray's Anatomy, 2008). There is variation not only in origin, branching pattern and course of anomalous (aberrant, supplementary, accessory) renal artery but also in their nomenclature and terminology used to describe them (Sykes, 1963; Singh *et al.*, 1998). Their relation with renal vein and pelvis have been studied and documented by many workers (Singh *et al.*, 1998; Merklin and Michels, 1958). These variations are not only important academically but have tremendous scope in the present era of interventional radiology and Laparoscopic urological, renal transplant surgery. There is no uniform terminology for these additional renal arteries (Sykes, 1963; Singh *et al.*, 1998). Merklin and Michels (1958) classifies these supernumerary renal arteries depending upon their origin into supernumerary renal arteries originating from aorta, main renal artery and from other sources. But in their study (Merklin and Michels, 1958) none of the hilar supernumerary renal artery originated from main renal artery. Talovic *et al.* (2007) reports that 30.76 % of supernumerary renal arteries originate from aorta and 12.86% originated from renal arteries. Virendra Budhiraja *et al.* (2013) observed that the supernumerary renal arteries originated from abdominal aorta in 47.30% of cases, from the main renal artery in 12.2% of cases and from renal artery in 8.1% of cases. None of the earlier studies (Merklin and Michels, 1958; Talovic *et al.*, 2007; Budhiraja *et al.*, 2013) have documented the origin of supernumerary renal arteries from coeliac trunk, superior mesenteric artery or from common iliac arteries. In our present study we found that supernumerary renal artery commonly arises either directly from abdominal aorta or from a common renal artery. But in our series we never found a supernumerary artery originating from coeliac trunk, superior mesenteric artery or from common iliac artery. Thus the observations made in our present study are very similar but not the same as made by earlier workers (Merklin and Michels, 1958; Talovic *et al.*, 2007; Budhiraja *et al.*, 2013). None of the reports the separate origin of inferior suprarenal artery and superior polar artery from superior branch (S) of common renal artery which originates from abdominal aorta and then divides into three branches, superior polar artery from which inferior suprarenal artery takes origin. Middle (M) and inferior (I) branches enter hilum of right kidney. Also we report a change in arrangement of structures at renal hilum associated with this anomaly (artery, vein, renal pelvis from anterior to posterior). Such observations were not made by earlier workers. These variations were studied and explained by Flex (1912) on the embryological basis. He observed that in a 18mm fetus, the developing mesonephros, metanephros, suprarenal glands and gonads are supplied by nine pairs of lateral mesonephric arteries which originate from dorsal aorta. He divided these vessels into three groups, cranial (1<sup>st</sup> and second), middle (3<sup>rd</sup> to 5<sup>th</sup>) and caudal (6<sup>th</sup> to 9<sup>th</sup>). Only one vessel in the middle groups persists and continues as renal artery, others get obliterated. Persistence of more than one artery results in

accessory or supernumerary renal arteries (Felix, 1912). In this era of laparoscopic surgery and interventional radiology/cardiology these additional vessels become more important clinically. Polar arteries arising from renal arteries have a vertical trajectory as compared to polar arteries from aorta. These vessels are more likely to be damaged during surgical mobilization as compared to those which originate directly from aorta (Sampaio and Passos, 1992). Also vertical trajectory makes poles more susceptible to infarction (Beyer and Daily, 2004). Lower polar arteries are causes of ureteropelvic junction obstruction leading to hydronephrosis (Shoja *et al.*, 2008) and in neglected cases renal failure. A sound anatomical knowledge of additional renal arteries is vital in planning and performing renal transplant surgeries where micro vascular techniques (Brannen *et al.*, 1982) are used for reconstruction of renal arteries. A prior knowledge of accessory renal arteries by using interventional radiological techniques may decrease the chances of transplant rejection as theoretically speaking a kidney with accessory arteries has more chances of acute tubular necrosis, rejection and decreased graft function (Sampaio and Passos, 1992). Thus in present era of laparoscopic urological & renal transplant surgery, interventional radiology and cardiothoracic surgery for management of aortic aneurysms variations in the arterial supply of kidney becomes more important for academic purposes and better surgical prognosis.

## Summary and Conclusion

Anatomical variations in origin, course and branching pattern of renal arteries are quite common, present in 30% of cases. Our present study was aimed to observe the possible origin, course, branching pattern and any change in arrangement of structures at the renal hilum. We found that these aberrant vessels are quite common present in about 20% of cases in our series. In 5 out of six cases we found that supernumerary renal artery originated from abdominal aorta. Only in one of the cadavers as shown in Fig. (1), aberrant renal arteries took origin from common renal artery. In this case we also found change in the arrangement of structures at the renal hilum with arteries placed anteriorly, vein in the middle and renal pelvis located posteriorly. We did not find anomalous renal arteries originating from superior mesenteric artery, coeliac trunk or common iliac arteries as reported in the available literature.

## REFERENCES

- Anson B. J., G. A. Richardson, and W. L. Minear, "Variations in the number and arrangements of the renal blood vessels, a study of the blood supply of four hundred kidneys," *Journal of Urology*, vol. 36, pp. 211–219, 1936.
- Awojobi O. A., O. A. Ogunbiyi, and E. O. Nkposong, "Unusual relationship of multiple renal arteries," *Urology*, vol. 21, no. 2, pp. 205–206, 1983.
- Beregi J. P., B. Mauroy, S. Willoteaux, C. Mounier-Vehier, M. Rémy-Jardin, and J. P. Francke, "Anatomic variation in the origin of the main renal arteries: spiral CTA evaluation," *European Journal of Radiology*, vol. 9, no. 7, pp. 1330–1334, 1999.
- Beyer R. W. and P. O. Daily, "Renal Artery Dissection Associated with Gz Acceleration," *Aviation Space and*

- Environmental Medicine*, vol. 75, no. 3, pp. 284–287, 2004.
- Brannen G. E., W. H. Bush, and R. J. Correa, “Microvascular management of multiple renal arteries in transplantation,” *Journal of Urology*, vol. 128, no. 1, pp. 112–115, 1982.
- Budhiraja B. *et al.* Supernumerary Renal Arteries and Their Embryological and Clinical Correlation: A Cadaveric study from North India A Cadaveric Study from North India, *ISRN Anatomy*, Volume 2013(2013) Article ID 405712, 4 pages.
- Çiçekcibaşı A. E., T. Ziylan, A. Salbacak, M. Şeker, M. Büyükmumcu, and I. Tuncer, “An investigation of the origin, location and variations of the renal arteries in human fetuses and their clinical relevance,” *Annals of Anatomy*, vol. 187, no. 4, pp. 421–427, 2005.
- Dhar P. and K. Lal, “Main and accessory renal arteries—a morphological study,” *Italian Journal of Anatomy and Embryology*, vol. 110, no. 2, pp. 101–110, 2005.
- Felix, W. “Mesonephric arteries (aa. mesonephrica),” in *Manual of Human* W. Felix, “Mesonephric arteries (aa. mesonephrica),” in *Manual of Human Embryology*, F. Keibel and F. P. Mall, Eds., vol. 22, pp. 820–825, Lippincott, Philadelphia, Pa, USA, 1912.
- Gray’s Anatomy, *The Anatomical Basis of Clinical Practice*, 40<sup>th</sup> edition, *Elsevier Churchill Livingstone*, 2008; page 1231.
- Krishnasamy N., M. Rao, S. N. Somayaji, S. Koshy, and V. Rodrigues, “An unusual case of unilateral additional right renal artery and vein,” *International Journal of Anatomical Variations*, vol. 3, pp. 9–11, 2010.
- Merklin R. J. and N. A. Michels, “The variant renal and suprarenal blood supply with data on the inferior phrenic, ureteral and gonadal arteries: a statistical analysis based on 185 dissections and review of the literature,” *The Journal of the International College of Surgeons*, vol. 29, no. 1, pp. 41–76, 1958.
- Nathan H. and I. Glezer, “Right and left accessory renal arteries arising from a common trunk associated with unrotated kidneys,” *Journal of Urology*, vol. 132, no. 1, pp. 7–9, 1984.
- Özkan U., L. Oğuzkurt, F. Tercan, O. Kizilkiliç, Z. Koç, and N. Koca, “Renal artery origins and variations: angiographic evaluation of 855 consecutive patients,” *Diagnostic and Interventional Radiology*, vol. 12, no. 4, pp. 183–186, 2006.
- Rusu, M. C. “Human bilateral doubled renal and testicular arteries with a left testicular arterial arch around the left renal vein,” *Romanian Journal of Morphology and Embryology*, vol. 47, no. 2, pp. 197–200, 2006.
- Sampaio F. J. B. and M. A. R. F. Passos, “Renal arteries: anatomic study for surgical and radiological practice,” *Surgical and Radiologic Anatomy*, vol. 14, no. 2, pp. 113–117, 1992. O. Olsson and M. Wholey, “Vascular abnormalities in gross anomalies of kidneys,” *Acta Radiologica*, vol. 2, pp. 420–432, 1964.
- Satyapal K. S., A. A. Haffjee, B. Singh, L. Ramsarop, J. V. Robbs, and J. M. Kalideen, “Additional renal arteries: incidence and morphometry,” *Surgical and Radiologic Anatomy*, vol. 23, no. 1, pp. 33–38, 2001.
- Shoja M. M., R. S. Tubbs, A. Shakeri *et al.* “Peri-hilar branching patterns and morphologies of the renal artery: a review and anatomical study,” *Surgical and Radiologic Anatomy*, vol. 30, no. 5, pp. 375–382, 2008.
- Shoja M. M., R. S. Tubbs, A. Shakeri, M. R. Ardalan, B. Rahimi-Ardabili, and K. Ghabili, “Asymptomatic bilateral ureteropelvic junction obstruction due to supernumerary renal arteries,” *Saudi Journal of Kidney Disease and Transplantation*, vol. 19, no. 5, pp. 806–808, 2008.
- Singh G., Y. K. Ng, and B. H. Bay, “Bilateral accessory renal arteries associated with some anomalies of the ovarian arteries: a case study,” *Clinical Anatomy*, vol. 11, no. 6, pp. 417–420, 1998.
- Sykes, “The arterial supply of the human kidney with special reference to accessory renal arteries,” *The British Journal of Surgery*, vol. 50, pp. 368–374, 1963.
- Talovic E., A. Kulenovic, A. Voljevic, and E. Kapur, “Review of supernumerary renal arteries by dissection method,” *Acta Medica Academica*, vol. 36, pp. 59–69, 2007.

\*\*\*\*\*