



RESEARCH ARTICLE

THE MORPHOLOGY AND LOCATION OF THE MANDIBULAR LINGULA IN SOUTH INDIAN POPULATION USING CONE-BEAM COMPUTED TOMOGRAPHY-A RETRO-SECTIONAL STUDY

*¹Dr. ArunKumar, G., ²Dr. Mahantesh Chinagudi, ³Dr. Bhagyashree M Patil and ⁴Dr. Sidra Iqbal

¹Department of Oral Medicine and Radiology, Dr. Syamala Reddy Dental College Hospital and Research Center, No111/1, S.G.R College main road, Marathalli post, Bangalore-560037, Karnataka

²Assistant Professor, Department of Orthodontics, M.S Ramiah University of Applied Sciences, Bangalore

³Rural Dental College and Hospital, Kalaburgi, Karnataka

⁴Loma Linda Dental School, California USA, MHA, Fairleigh Dickinson University, Canada BDS, Dr.Syamala Reddy Dental College Hospital and Research Centre, India

ARTICLE INFO

Article History:

Received 18th December, 2015
Received in revised form
25th January, 2016
Accepted 29th February, 2016
Published online 31st March, 2016

Key words:

Adult Mandible Cone-Beam Computed tomography Foramen Lingula Morphology Shape.

ABSTRACT

Objectives: The precise anatomical of the lingula of the mandible is clinically significant because it is more susceptible to injury during a variety of oral and maxillofacial surgical procedures. This is the first study to identify, classify and measure the mandibular lingula using cone-beam computed tomography in South Indian population.

Materials and methods: A retrospective study was done to measure the shape, height, and location of the lingula in relation to surrounding structures using cone-beam computed tomographic images. The shape of the lingula was classified according to the method given by Tuly *et al.* (2000) The location was determined by five distances from the lingular tip according to the method given by Ahmet *et al.*

Results: The most common shape of the lingual is truncated, followed by triangular [32 % (264)]. The mean height of the lingula was 7.97 ± 1.84 mm. The average distance of lingula to the mandibular ramus (anterior and posterior borders) was found to be 16.7 ± 2.7 and 13.0 ± 2.3 mm, respectively. The lingula was located at 11.4 ± 2.5 mm from the mandibular notch, 14.10 ± 4.74 mm from the mandibular base and 16.21 ± 4.54 mm from the distal side of mandibular second molar tooth.

Conclusion: The study provides a new insight to the morphology, height and location of the lingula in the South Indian population. These findings would assist the Oral surgeons to localize the lingula and would avoid intraoperative complications to the patient.

Copyright © 2016, Dr. ArunKumar *et al.* This is an open access article distributed under the Creative Commons Attribution License, which permits unrestricted use, distribution, and reproduction in any medium, provided the original work is properly cited.

Citation: Dr. ArunKumar, G., Dr. Mahantesh Chinagudi, Dr. Bhagyashree M Patil and Dr. Sidra Iqbal, 2016. "The morphology and location of the Mandibular lingula in south Indian population using cone-beam computed tomography-a retro-sectional study", *International Journal of Current Research*, 8, (03), 28466-28469.

INTRODUCTION

The lingula is a bony projection which is tongue shaped on the medial surface of the ramus adjacent to the posterior part of the mandibular foramen. It is an important anatomical landmark to identify the site for injection of local anesthetics and also for nerve excision procedures done for facial neuralgia (Bremer, 1952). It is considered as a reliable reference for the inferior alveolar nerve block techniques. It was described in the past by Johannes-Baptist Spix in 1815 and was named as "Spix'sossicle or spine" (Devi *et al.*, 2003). The relationship of lingula to the inferior alveolar nerve is important to the orodental surgeons because the inferior alveolar nerve enters the mandibular foramen to innervate the mandible (Epker, 1977). The study of the lingula using CBCT provides significant

information related to the Oral and maxillofacial surgeons for procedures like orthognathic surgery, trauma assessment of the lower jaw, osteotomies, eradication of benign and malignant lesions, pre-prosthetic surgery and injury to the inferior alveolar nerve (Bremer, 1952). Variations in the shape of the lingula have been reported by various authors. Tuli *et al.* (2000) did a study on dry skulls and identified four different shapes of the mandibular lingula as triangular, nodular, truncated and assimilated types. The present study was done to locate and classify the mandibular lingula according to its morphology and to locate the lingula in relation to the mandibular ramus and mandibular second molar in South Indian population using cone-beam computed tomography (CBCT), differences of the parameters were also evaluated among sex-side groups.

MATERIALS AND METHODS

A descriptive analytical cross-sectional study was conducted on 100 CBCT scans of mandible (50 males and 50 females)

*Corresponding author: Dr. Mahantesh Chinagundi,

Department of Orthodontics and Dent facial Orthopaedics, M. S. Ramaiah Dental College and Hospital, M. S. Ramaiah University of Applied Sciences, Faculty of Dental Sciences, Bangalore, India.

from patients, who visited a diagnostic centre were randomly selected after considering the following criteria. The inclusion criteria included: presence of all lower erupted anterior dentition; male/female aged 18 years or older, and absence of any pathological conditions or deformities in the jaws. The exclusion criteria were: inadequate CBCT image quality (patient movement, operator errors etc., CBCT scans that did not include mandible, history of trauma or orthognathic surgery, Absence of any pathologic lesions in the posterior mandible, Absence of severe atrophy of the lower jaw, At least a premolar and second molar on the same side for the distance measurement. presence of pathologic bone disease or unerupted teeth in related region and syndromic patients.

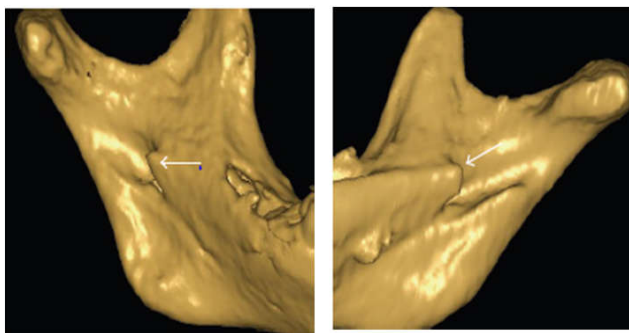
All patients had their CBCT scans taken for other purposes and they had informed consent for participation in this study. The selected scans had paraxial slices with slice thickness of 0.3 mm. The lingula foramina region was in the CBCT scans. The CBCT examinations were carried out for every patient with Carestream 9300 3D imaging system. Full rotation scan was performed with 70-90 kVp, 5-10 mA and voxel size of 90-180 μ m. the size of field of view will be 10*5 cm (using high contrast and high resolution options). The effect of anatomical variations of lingula region on patient's gender were evaluated using 8 different parameters.

Anatomical position of lingula in relation to occlusal plane (right and left sides separately).

- At the level of occlusal plane
- Above the occlusal plane
- Below the occlusal plane

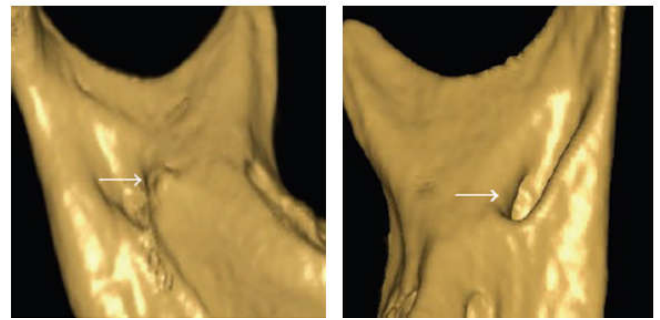
Variations in the shape of lingula (right and left sides separately, according to the classification proposed by Tuli *et al.*)

- Triangular (with a wide base and a narrow rounded or pointed apex, rounded or pointed apex)
- Truncated (lingula with somewhat quadrangular bony projection on its top)
- Nodular (lingula is nodular and of variable size, almost the entire lingula except for its apex which was merged into the ramus)
- Assimilated (lingula is completely incorporated into the ramus)



a. Triangular

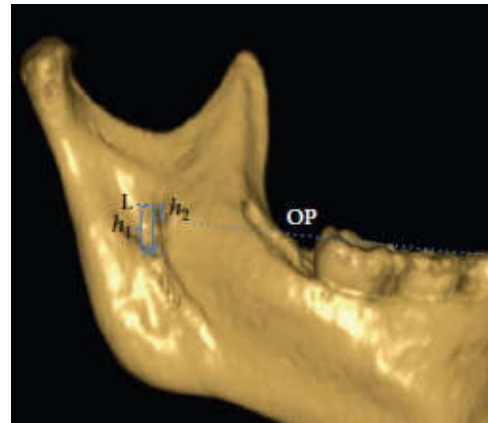
b. Truncated



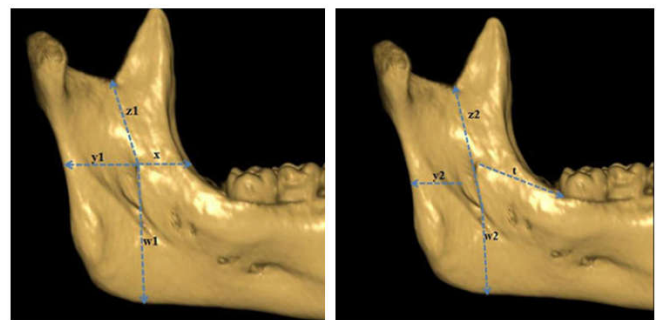
c. Nodular

d. Assimilated

Anatomical height of the lingula (h_1) (right and left sides separately).



- Distance of lingula from anterior border of the mandible (x) (right and left sides separately).
- Distance of lingula from posterior border of the mandible (y) (right and left sides separately).
- Distance from mandibular notch (z) (right and left sides separately).
- Distance from mandibular base (w) (right and left sides separately).
- Distance from the distal aspect of second molar tooth (t) (right and left sides separately).



Statistical Analysis

The analysis was conducted using the distance measuring tool of CS 3 D software and the images were saved as JPEG. The measurements were repeated after 2 months and intra-examiner consensus was performed (Dahlberg's error and paired T test). All data were evaluated using SPSS software version 19 package.

A paired T test (P 0.05) was conducted to compare the measurements from the right and left side, and a T test was conducted to compare the values between the sexes. One way ANOVA test was used to compare the measurements between the two study populations. In order to identify the harmony between the LH on the right and left sides, an intra-class correlation coefficient (ICC) was used. The degree of symmetry between the right and left pathways in the sagittal and coronal planes was measured using the Kappa co-efficient. A kappa values were considered as follows < 0.20 poor, 0.21-0.40 fair, 0.41-0.60 moderate, 0.61-0.80 good and 0.81-1.00 very good. A P-value less than the 0.05 level of significance was considered statistically significant. Further Discriminant analysis (ROC analysis) was used to assess the validity of linear measurements used in this study in differentiation of male gender from female according to method given by Sorlie (1995) (Sura, 2011).

RESULTS

The study subjects consisted of 100 patients, 50 males and 50 females. The mean age of the patients was 32.18 (SD: 1.87) in a range of 18 to 60 years.

Table 1. Position of lingula on Right side of the mandible

Gender	1	2	3	Total
MALE	17	16	17	50
FEMALE	15	22	13	50
Total	32	38	30	100

Table 2. Position of lingula on Left side of the mandible

Gender	1	2	3	Total
MALE	12	23	15	50
FEMALE	19	16	15	50
Total	31	39	30	100

The lingulae were 31.5% (63) at the same level with the occlusal plane, 35.5% (71) above the occlusal plane, and 33% (66) below the plane (Table1 and Table2). The most common shape was the truncated shape of the ML (32.5%, n=65), followed by triangular (23.2%, n=57), nodular (13%, n=51), and assimilated (1.9%, n=27) (Figures 3(a)–3(d)). A bilateral shape (65.7%) were observed more frequently than an unilateral shape (34.3%).

The MLs were found truncated on both sides in 65 sides (32.5%), triangular in 57 sides (23.2%), nodular in 51 sides (13.0%), and assimilated in a few cases (27 sides, 1.9%). The morphology of the mandibular lingula was also compared between males and females (Table2); there was a statistical difference between gender in triangular and nodular shape.

The distance of ML from landmarks near the mandibular ramus and distal side of the mandibular permanent first molar tooth and ML ratio are shown in Table3. The ML was observed to be at a distance of 14.05 ± 6.68 mm from the anterior border of mandibular ramus, 12.91 ± 3.73 mm, from the posterior border of the ramus, 11.4 ± 2.5 mm from the mandibular notch and 14.10 ± 4.74 mm from the mandibular base. The average distance of the ML from the distal surface of the mandibular permanent second molar tooth was 16.21 ± 4.85 mm. The mean height (h1) of the ML was on right side, 10.92 ± 2.88 mm and left side, 10.05 ± 2.69 mm with statistically significant difference between gender on right side (Table3).

DISCUSSION

Lingula, 'meaning little tongue', has been described in relation to the mandibular foramen as a bony elevation partially covering it (Smrity, 2014). Lingula is an important clinical landmark for oral-maxillofacial surgeons. It needs to be identified before performing surgeries to minimize intra-operative and post-operative complications. The Location of lingula varies among the different ethnic and racial groups. The distance of the lingula to the lower border of the mandible were shorter in female than males as results of present study. This observation is consistent with the previous study done by Ahmet *et al.* In the present study, the lingula is most commonly located above the level of occlusal plane which is comparable to the results in Brazil population.

According to Nirmale *et al.* (2012) triangular shape was most common. According to Lopes *et al.* (2010) triangular shape is the most common and assimilated type is the least common variety of shape of lingula in the Southern Brazil population. In the Samanta and Kharb study, the most prevalent shape of lingula was triangular and the least prevalent shape was assimilated type (Samanta and Kharb, 2012). In present study, truncated lingula was most frequently found (32.5 %) and most appeared to be bilateral (79.4 %).

Table 3. The distance of lingula from various anatomical landmarks

		Sum of Squares	df	Mean Square	F	Sig.
Distance x (mm)	Between Groups	37.357	1	37.357	4.063	.047
	Within Groups	901.127	98	9.195		
	Total	938.483	99			
Distance y (mm)	Between Groups	1.402	1	1.402	.100	.752
	Within Groups	1371.537	98	13.995		
	Total	1372.939	99			
Distance z (mm)	Between Groups	93.974	1	93.974	7.750	.006
	Within Groups	1188.338	98	12.126		
	Total	1282.312	99			
Distance w (mm)	Between Groups	1647.297	99			
	Between Groups	248.977	1	248.977	13.893	.000
	Within Groups	1756.310	98	17.922		
Distance t (mm)	Total	2005.287	99			
	Between Groups	318.130	1	318.130	15.615	.000
	Within Groups	1813.241	89	20.373		
Total	2131.371	90				

Tuli *et al.* (2000) observed variation of the lingula shapes among genders. In their study, the triangular and assimilated types were the most common and the less common types in both males (67.9 and 5 %) and in females (70.6 and 4.4 %), respectively. They observed truncated type twice as common in males (17.6 %) than females (8.8 %), the nodular type was a little less than double in females (16.2 %) as compared with males (9.6 %). In our study, there was no different gender wise variation observed. The triangular and truncated types were the most and the least prevalent types in males and females, respectively.

The height of lingula varies among different population. A study done on mandibles of Thailand population showed that the height of lingula to be 8.2 ± 2.3 mm (Devi *et al.*, 2003). In a study reported by Woo *et al.* (2002) on the Korean population, the height of lingula was found to be more, i.e., 10.51 ± 3.84 mm. In present study, height of lingula on right side, 10.92 ± 2.88 mm and left side, 10.05 ± 2.69 mm with statistically significant difference between gender on right side. The mean distance from the lingula to the anterior border of the mandibular ramus in our study was 14.05 ± 6.67 mm (range 14.1–34.9 mm), which was shorter than the suggested 18 mm, 18.6 ± 2.5 mm studied by Yu and Wong *et al.* (2008) and 20.6 ± 3.5 mm (range 14.1–34.9 mm). Present study suggests that the length of horizontal osteotomy in bilateral sagittal split ramus osteotomy should be between 13 and 21 mm in most cases. The distance of lingula to the posterior border of the ramus was found to be 12.91 ± 3.72 mm, which was similar to previous study done by Ahmet *et al.* In present study, the distance from the lingula to the mandibular notch, which also helps surgeons to localize the lingula (mean 14.75 ± 3.59 mm; range 11.0–21.1 mm) was similar to previous studies. The mean distance of lingula to base of the mandible was found to be 14.10 ± 4.74 mm, which was similar to previous studies. The average distance of lingula from the distal aspect of first molar tooth was found to be 16.21 ± 4.86 mm, which was similar to previous studies.

Jansisyanont *et al.* (2009) reported that the mandibles with and without molars showed no significant difference in all studied parameters. This suggests that in cases without molars, other landmarks that are easy to identify such as the inferior border of the mandible and its perpendicular line may be used. Thus, it is not possible to use the parameters solely as a guide line for the clinical application in patients with mandibular deformities. Preoperative examination with appropriate tomographic images is strongly recommended. A limiting factor in the present study was smaller sample size and we suggest that further studies to be performed on a larger group of subjects of different age and ethnicity. It is also suggested that lingula should be analyzed in adults and children as well as in subjects with craniofacial diseases and syndromes.

Conclusion

In conclusion, this study provides radiographic location of lingula in South Indian population observed using CBCT to the literature.

The bilateral truncated shape of the lingula was most commonly observed in the South Indian Population. The mean height of the lingula of the mandible was 8.2 mm. The lingula was located at an average of 14.06 mm from the anterior border of the mandibular ramus, 12.92 mm from the posterior border of the ramus, 14.75 mm from the mandibular notch, 14.70 mm from the lower border of the mandible, and 16.21 mm away from the distal surface of the mandibular second molar. The findings of present study could be utilized in oral and maxillofacial surgical procedures to locate the lingula and avoid intraoperative complications.

REFERENCES

- Ahmet, E. *et al.* Cone-beam computed tomography analysis of the shape, height and location of the mandibular lingula. *SurgRadiolAnat* DOI 10.1007/s00276-013-1150-0.
- Bremer, G. 1952. Measurements of special significance in connection with anesthesia of the inferior alveolar nerve. *Oral Surg Oral Med Oral Pathol* 5:966–988
- Devi, N.K. Manjunath, Y. and Balasubramanyam, B. 2003. "Incidence of morphological variants of mandibular lingula," *Indian Journal of Dental Research*, vol. 14, no. 4, pp. 210–213.
- Devi, R., Arna, N., Manjunath, K.Y., Balasubramanyam, 2003. Incidence of morphological variants of mandibular lingula. *Indian J Dent Res* 14(4):210–213
- Epker, B.N. 1977. Modifications in the sagittal osteotomy of the mandible. *J. Oral. Surg.*, 35:157–159
- Jansisyanont, P., Apinhasmit, W. and Chompoopong, S. 2009. Shape, height and location of the lingula for sagittal ramus osteotomy in Thais. *Clin Anat.*, 22:787-93.
- Lopes, P.T., Pereira, G.A. and Santos, A.M. 2010. Morphological analysis of the lingula in dry mandibles of individuals on Southern Brazil. *J MorpholSci* 27:136–138.
- Nirmale, V.K., Mane, U.W. and Sukre, S.B. *et al.* 2012. Morphological features of human mandible. *Int J Recent Trends SciAechnol* 3:33–43.
- Samanta, P.P. and Kharb, P. 2012. Morphological analysis of the lingula in dry adult human mandibles of north Indian population. *J Cranio Max Dis.*, 1:7-11.
- Smrity, G. *et al.* 2014. Morphological analysis of the lingula in dry mandibles of individuals in North India. *IOSR* 13(1):04-06.
- SuraA *et al.* Sex determination using linear measurements related to the mental and mandibular foramina vertical positions on digital panoramic images *Rashid J Bagh College Dentistry* 23:2011.
- Tuli, A. *et al.* 2000. Variation in shape of the lingula in the adult human mandible. *J. Anat.*, 197:313-317.
- Woo, S.S., Cho, J.Y., Park, W.H., Yoo, I.H., Lee, Y.S. and Shim, K.S. 2002. A study of mandibular anatomy for orthognathic surgery in Koreans. *J. Korean Assoc. Oral. Maxillofac Surg.*, 28:126-31.
- Yu, I.H. and Wong, Y.K. 2008. Evaluation of mandibular anatomy related to sagittal split ramus osteotomy using 3-dimensional computed tomography scan images. *Int. J. Oral. Maxillofac. Surg.*, 37:521–528.
