



CASE STUDY

ECTODERMAL DYSPLASIA – 2 CASE REPORTS AND REVIEW OF LITERATURE

Dr. Saraswathi Gopal, M.D.S. and Dr. P. Sai Archana, M.D.S.

¹Head of Department, Oral Medicine and Radiology, Meenakshi Ammal Dental College and Hospital, Maduravoyal, Chennai

²Senior Lecturer in Oral Medicine and Radiology, Chettinad Dental College and Research, Institute, Kelambakkam, Chennai

ARTICLE INFO

Article History:

Received 15th November, 2016
Received in revised form
24th December, 2016
Accepted 15th January, 2017
Published online 28th February, 2017

Key words:

Hypodontia,
Ectodermal Dysplasia,
Christ Siemens Syndrome, Hypohidrosis,
Zygomatic Implants

ABSTRACT

Ectodermal dysplasias (EDs) are a heterogeneous group of disorders characterized by developmental dystrophies of ectodermal structures. The X-linked recessive ED (Christ-Siemens-Touraine syndrome) is the most common disorder affects mostly males and is inherited through female and they become carriers. It is characterized by the triad of signs of sparse hair (atrachosis or hypotrichosis), abnormal or missing teeth (anodontia or hypodontia) and inability to sweat due to lack of sweat glands (anhidrosis or hypohidrosis). The lack of teeth and the special appearance were reported to be major concerns. Thus an early diagnosis is important. Families suffering from this disorder should therefore be offered genetic counselling. Currently the genes and gene products are defined, hence identification of the genes and taking necessary precautions before starting a family will be beneficial. For the patients as well as the dentists, tooth agenesis and its secondary effects on growth and development of the jaws is often the most significant clinical and therapeutical problem. The course of the treatment is to restore the function and the aesthetics of the teeth, normalise the vertical dimension and support the facial soft tissues. We report two cases of ectodermal dysplasia with review in this article for better understanding of this disorder.

Copyright©2017, Dr. Saraswathi Gopal and Sai Archana Padmanabhan. This is an open access article distributed under the Creative Commons Attribution License, which permits unrestricted use, distribution, and reproduction in any medium, provided the original work is properly cited.

Citation: Dr. Saraswathi Gopal and Sai Archana Padmanabhan, 2017. "Ectodermal dysplasia - Report of 2 cases and review of literature", *International Journal of Current Research*, 9, (02), 47073-47077.

INTRODUCTION

The ectodermal dysplasia is a large heterogeneous group of inherited disorders characterised by primary defects in the development of structures derived from embryonic ectoderm. Tissues primarily involved are teeth, skin and its appendages (nails, hair, sebaceous glands and sweat glands) In this article we are discussing 2 case reports of hypohidrotic ectodermal dysplasia represents a group of ectodermal dysplasias that are characterized by sparse eccrine glands as well as by hypotrichosis and oligodontia with peg-shaped teeth.

CASE REPORT 1

A 14 year old boy presented to our department with a chief complaint of missing teeth in her upper and lower jaw. Patient also gave a history of hypodontia of teeth since childhood. History of turning hyper thermic when exposed to heat and drinks lot of water and takes bath often to reduce and regulate

temperature. No significant medical and surgical history was given and his vital signs were within normal limits. Previous dental history revealed patient received removable partial denture 8 years back which he didn't wear as it was ill fitting. General examination revealed presence of mild frontal bossing, flat nasal bridge, sparse and greyish brown hair and absence of eyelashes. Other manifestations included hyper pigmentation and fine wrinkling seen in midfacial region (Fig. 1). Midfacial hypoplasia is observed with prognathic mandible with thick protuberant lips giving an elderly man look. The intraoral examination revealed complete edentulous in the lower jaw, 2 peg shaped anterior teeth (13, 23) in the maxilla, thin knife edged alveolar ridge and reduced vertical bone height (Fig. 2). An OPG was taken (Fig. 3) which revealed deviated nasal septum. Presence of two peg shaped canine teeth in hypoplastic maxilla and the roof of the mandibular canal is visibly exposed and not appreciable. The treatment planned for the patient is placement of zygomatic implants in maxilla and over dentures in mandible for esthetic and functional rehabilitation.

*Corresponding author: Sai Archana Padmanabhan,

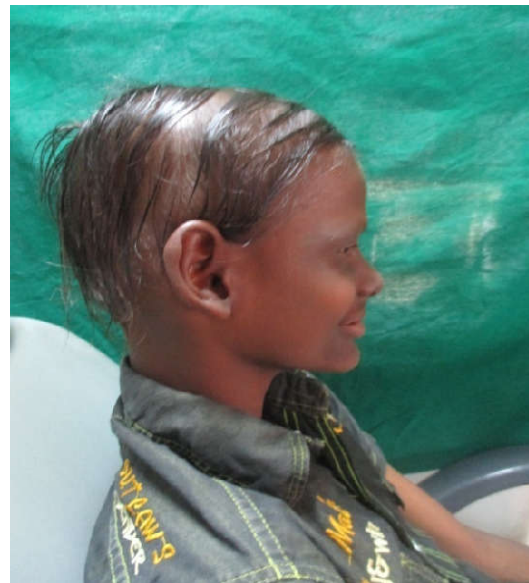


Figure 1: Hyper pigmentation of skin in facial region along with fine wrinkling seen in midfacial region

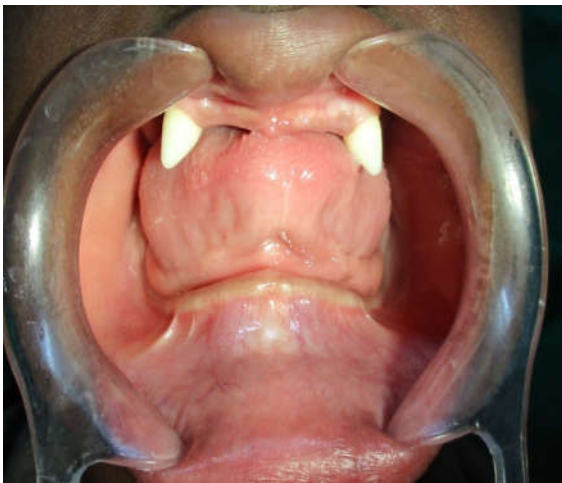

Figure 2: Peg shaped anterior teeth (13, 23) in the maxilla, thin knife edged alveolar ridge

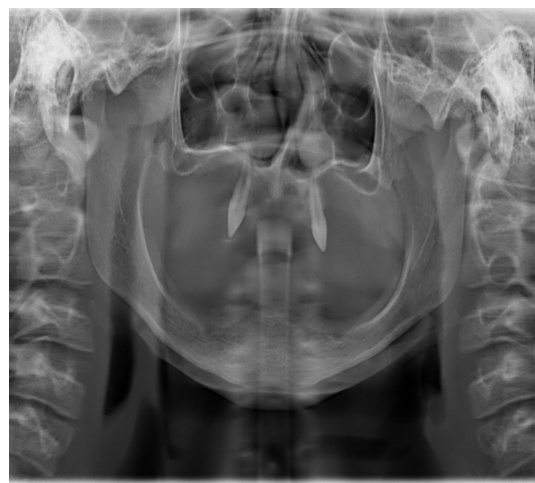

Figure 3: Hypoplastic maxilla and the roof of the mandibular canal is visibly exposed



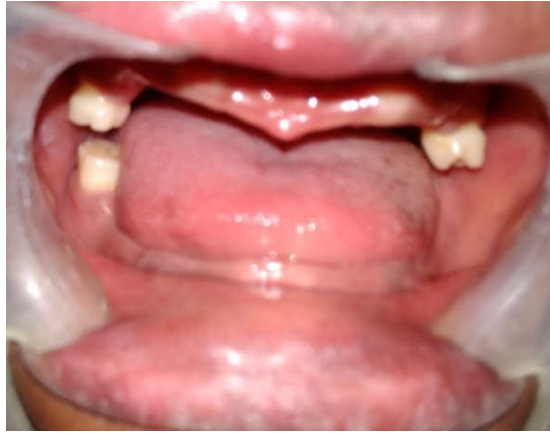



Fig 5. Alteration in morphology of teeth is seen

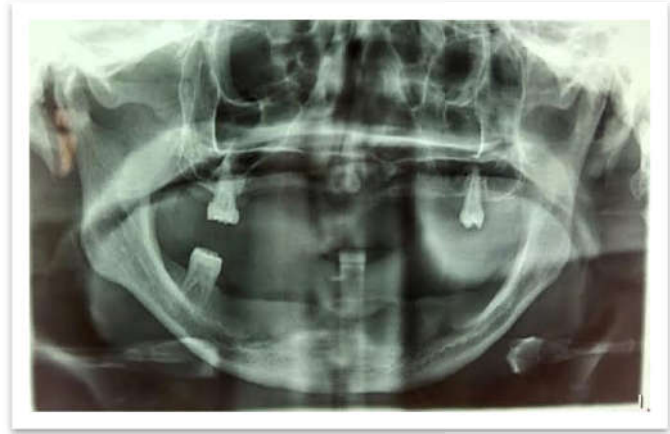


Fig 6: OPG revealed Hypoplastic maxilla and the roof of the mandibular canal is visibly exposed

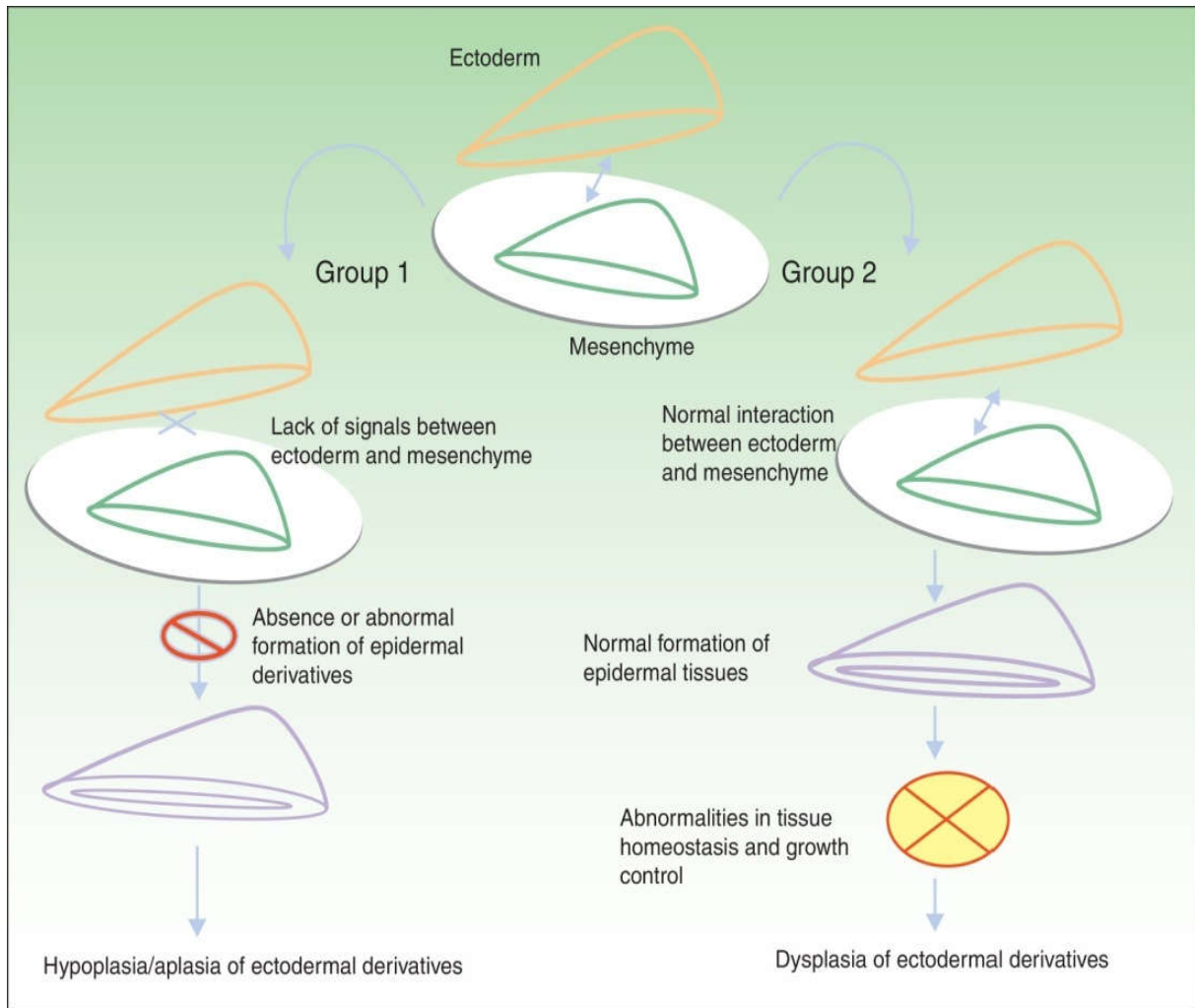


Fig. 7. Pictorial representation of ectodermal pathway

CASE REPORT 2

A 24 year old male patient came to our department complaining of missing teeth in his upper and lower jaw since childhood. Patient gave a history of hypodontia of teeth since childhood. History of turning hyper pyrexia when exposed to heat and was unable to tolerate heat, hence he drinks lot of water to reduce and regulate hot temperature. No significant medical and surgical history was given and his vital signs were within normal limits. General examination revealed patient was conscious, cooperative, responding well to questions and was moderately nourished and built. Sparse hair (black) and eyelashes was noticed (Fig 4). Other manifestations included hyper pigmentation and fine wrinkling seen in midfacial region. Midfacial hypoplasia is observed with prognathic mandible with thick protuberant lips giving an elderly man look. The intraoral examination revealed, presence of posterior teeth. (17,27) in the maxilla and 47 in mandible (Fig. 5). Thin knife edged alveolar ridge, shallow palate and reduced vertical bone height is also observed. An OPG (Fig. 6) was for treatment planning for the prosthetic rehabilitation of patient. OPG revealed presence of 3 teeth 17, 27, 47 and hypoplastic maxilla. The treatment planning suggested for this patient was placement of zygomatic implants in maxilla and placement of implant supported overdentures for the lower jaw as it has considerably good amount of bone compared to maxilla. Pictorial representation of ectodermal pathway (Fig. 7).

DISCUSSION

Hereditary ectodermal dysplasia represents a large group of conditions in which two or more ectodermally-derived anatomic structures fail to develop (Neville *et al.*, 2009). Ectodermal dysplasia (ED) might be inherited in any form of several genetic patterns including autosomal-dominant, autosomal-recessive, and X-linked modes (Burke 11th edition) and mutations in only 4 genes (EDA1, EDAR, EDARADD and WNT10A) are responsible for most cases of Ectodermal dysplasia. Although more than 170 different subtypes of ectodermal dysplasia have been identified, these disorders are considered to be relatively rare with an estimated incidence of 1 case per 100,000 (Shawky and Gamal, 2015). Ectodermal dysplasia is divided into two groups, hypohidrotic or anhidrotic, based on the degree of sweat gland function. The most common condition among the syndromes is hypohidrotic ectodermal dysplasia. The females are the carriers of this disease and males are often affected (Ajaz Shah and Suhail Latoo, 2011). Hereditary ectodermal hypoplasia is more severe form associated with hypodontia or anodontia, hypotrichosis (fine, sparse blond hair, including a decreased density in both eyebrows and eyelashes), and hypohidrosis or anhidrosis. Dental defects represent a core clinical feature of many EDs: anodontia, polyodontia, dysplastic teeth, retained primary teeth, deficient enamel development (amelogenesis imperfecta), dentine deficiency (dentinogenesis imperfecta), and underdevelopment of the alveolar ridge. In many number of cases, the number of erupted teeth is reduced, the spacing of the teeth disrupted, and the periodontium affected (Neville *et al.*, 2009; Burke 11th edition; Priolo, 2009). Disturbance of the enamel matrix may occur, making the teeth more susceptible to caries, and altering the shape of the teeth, leading to a pegged appearance and or additional accessory

cusps. The HEDs are caused by genetic defects in ectodysplasin signal transduction pathways.

1. In *group 1*, there is an abnormal interaction between the ectoderm and the mesenchyme, thereby impeding correct differentiation of the epidermal derivatives, which are hypoplastic or aplastic.
2. In *group 2*, the interaction between the ectoderm and mesenchyme is normal, and the epidermal derivatives differentiate normally, but tissue homeostasis and growth are abnormal, so dysplasia is present in the ectodermal derivatives (Priolo, 2009).

Epithelial cells in developing tooth, hair follicle use this pathway during morphogenesis, and genetic defects occur if there is defect in the pathway resulting in aplasia, hypoplasia or dysplasia. The pathway is activated at a critical time (Jean bologna, 2012) during development in a specific group of epithelial cells. With activation, a transcription factor, NF- κ B, is translocated into the nucleus of these cells and alters the expression of an unknown number of target genes. The change in gene expression likely has an affect on both cellular proliferation and survival. The nails are usually normal. Abnormalities in the development of tooth buds result in hypodontia and peg-shaped or pointed teeth. The hypodontia varies in each case, but usually only 5 to 6 permanent teeth are present, the teeth are smaller than average, and the eruption of teeth is often delayed. The extent of hypodontia may be useful in assessing the severity of the disease, and is best done with dental radiographs (Imirzalioglu *et al.*, 2002).

Types of ectodermal dysplasia

- (i) *X-linked hypohidrotic ED* (Christ-SiemensTouraine syndrome) is the most frequent form was first described in 1848 by Thurnam and later in the 19th century by Darwin. Both autosomal dominant and autosomal recessive inheritance forms were presented and their molecular presentations are explained (Neville *et al.*, 2009; Shawky and Gamal, 2015; Ajaz Shah and Suhail Latoo, 2011).
- (ii) *Cleft lip/ palate syndrome*; the inheritance of this syndrome is probably determined by an autosomal recessive gene. Hypohidrosis accompanies slight frontal bossing and some depression of the nasal bridge. The scalp hair is often fine, dry, sparse and light in colour; the nails are dystrophic and teeth are few and small. Other features are cleft lip and palate, syndactyly and defects of the external genitalia. Lacrimal gland abnormalities are frequently encountered. The disorder was assigned to chromosome 11q23 by linkage mapping.
- (iii) *Tooth and nail syndrome (Witkop syndrome)* is another type of autosomal-dominant Ectodermal dysplasia associated with specific dental findings. The primary dentition is usually unaffected, although the teeth may be small or peg-shaped, whereas the secondary dentition is often partially or completely absent (Michael J Aldred *et al.*, 2013).
- (iv) *Oculodentodigital dysplasia* is a rare autosomal dominant subtype of Ectodermal dysplasia, characterized by bilateral microphthalmos, nose malformations,

hypotrichosis, syndactyly, and dental abnormalities particularly enamel hypoplasia.

Dental treatment is mostly needed in patients with Ectodermal dysplasia and children may need dentures as early as 2 years (Imirzalioglu *et al.*, 2002) of age to 11 yrs of age. It is important to seek dental advice early as maintenance of the alveolar ridge is important for later dental intervention. Esthetic rehabilitation is done via implants placed in maxilla, in the form of mini implants for children and zygomatic implants in adults. This not only helps in mastication and speech but also with the development of a positive self-image and overall good oral health. Hence we conclude that early identification and intervention to the problems caused due to this disease should be done to help the sufferers improve their quality of life and ease their psychological fears. They can also be advised to undergo genetic counseling to prevent the disease from passing on to future generations by educating the family and their descendants.

REFERENCES

- Ajaz Shah and Suhail Lato, 2011. Anhidrotic ectodermal dysplasia: report of two cases and review of literature, *Indian Journal of Dental Sciences*, June, Issue:2, Vol.:3
- Burkeet, Textbook of oral medicine, 11th edition.
- Gokcen Balci *et al.* 2008. Ectodermal Dysplasia: Report of Four Cases and Review of Literature, *International Dental and Medical Disorders*, Vol 1.
- Imirzalioglu P, Uckan S, Haydar SG. 2002. Surgical and prosthodontic treatment alternatives for children and adolescents with ectodermal dysplasia: a clinical report. *J Prosthet Dent*, 88:569-72
- Jean Bologna *et al.* 2012. Text book for Dermatology, third edition, volume one.
- Michael J Aldred, Angus C Cameron, Nigel M King, Richard P Widmer, 2013. Dental anomalies, Handbook of Pediatric Dentistry, (Fourth Edition).
- Neville BW, Damm DD, Allen CM, Bouquot JE. 2009. Dermatologic diseases. Oral and Maxillofacial pathology, 3rd ed. Noida: Elsevier Publications; p. 741-3
- Pravin Gaikwad, Santhosh Kumar S. Hiremath *et al.* 2012. Hypohidrotic Ectodermal Dysplasia: A Case Report & Literature Review, *Journal of Dental Sciences & Oral Rehabilitation*, Oct-Dec.
- Priolo M. 2009. Ectodermal dysplasias: an overview and update of clinical and molecular-functional mechanism, *Am J Med Genet A*, 149A, pp. 2003-2013
- Shawky RM. and Gamal R. 2015. Christ-Siemens-Touraine syndrome with cleft palate, absent nipples, gallstones and mild mental retardation in an Egyptian child, *Egypt J Med Hum Genet*.
