



RESEARCH ARTICLE

COMPARATIVE EVALUATION OF AN AUTOGENOUS BONE GRAFT AND AN ALLOPLASTIC BONE GRAFT IN THE TREATMENT OF PERIODONTAL INTRABONY DEFECTS: A CLINICO-RADIOGRAPHIC STUDY

*Yashbir Singh Raghav, Yashpaul Dev, Preetinder Singh, Rajeshwar Digra, Gaurav Chowdhary and Dinesh Duhan

Lecturer, Swami Devi Dyal Hospital and Dental College, India

ARTICLE INFO

Article History:

Received 24th March, 2016
Received in revised form
17th April, 2016
Accepted 05th May, 2016
Published online 30th June, 2016

Key words:

TCP- Tricalcium phosphate,
RAL- Relative attachment level.

ABSTRACT

Aim: To comparatively evaluate the regeneration potential of Hydroxyapatite β - tricalcium phosphate and autogenous bone graft in the treatment of periodontal intrabony defects.

Material and Methods: A total of 20 sites were selected from those attending the Out Patient Department (OPD) of Department of Periodontology and oral implantology at Swami Devi Dyal Dental College and Hospital, Barwala, Panchkula. Subjects for the study were selected randomly with no discrimination on the basis of sex, caste, religion or socioeconomic status. Complete medical and dental history was obtained. A complete clinical and radiographic evaluation was performed. Patients who were diagnosed as suffering from moderate to advanced periodontitis along with radiographic evidence of periodontal osseous defects were selected for the study.

Results: The results were compiled and statistically analysed using paired T- test. The data was normally distributed and it was analysed by paired T-test. Analysis of the data was done in two parts: inter group and intra group analysis. Intra group comparison shows significant differences at 3 months and 6months ($p > 0.001$) but intergroup comparison shows non significant comparison. ($p < 0.001$)

Conclusions: The results of the present study showed that all the graft material resulted in increased bone levels, increased attachment level, reduced probing depth, significant bone resolution.

Copyright©2016, Yashbir Singh Raghav. This is an open access article distributed under the Creative Commons Attribution License, which permits unrestricted use, distribution, and reproduction in any medium, provided the original work is properly cited.

Citation: Yashbir Singh Raghav, Yashpaul Dev, Preetinder Singh, Rajeshwar Digra, Gaurav Chowdhary and Dinesh Duhan. 2016. "Comparative evaluation of an autogenous bone graft and an alloplastic bone graft in the treatment of periodontal intrabony defects: a clinico-radiographic study", International Journal of Current Research, 8, (06), 33546-33552.

INTRODUCTION

Periodontitis is a multi- factorial diseases resulting in inflammation with in supporting tissue of the teeth, progressive attachment loss and bone loss (Newman). The extension of inflammation to the supporting structures of a tooth may be modified by the pathogenic potential of plaque or the resistance of the host. Chronic periodontitis does not progress at an equal rate in all effected sites throughout mouth. Some involved areas may retain static for long period whereas other may progress rapidly (Lindhe *et al.*, 1986). Complete and predictable regeneration of tissue lost as a result of infection or trauma is the ultimate goal of periodontal therapy. Regenerative procedures may restore lost supporting structures of the dentition such as cementum, periodontal ligament and bone to a previously diseased root surface (Gurinsky *et al.*, 2004).

Various graft materials have been successfully used in the treatment of intrabony defects. The materials most commonly used have been autografts and allografts (Nasr, 2000). The bone replacement grafts may aid in providing a scaffold for the host's resident cells or provide factors that aid in stimulating regeneration via osteoinductive or osteoconductive pathways (Mellonig, 1981). Bone grafts also have the ability to act as a barrier for epithelial exclusion and prevent soft tissue collapse into the defect site. Such grafts generally have been recommended for use in intra-osseous defects not amenable to other methods of treatment (Bowers *et al.*, 1989). Autogenous bone has been successfully used by several investigators. By the clinical and histological results of implantation of osseous autograft in humans, most clinicians and investigators conclude that autogenous bone graft is "gold standard" among all bone graft because it is only graft that provide osteo-conduction, osteo-induction and osteogenesis (Nabers *et al.*, 1965). It avoids any risk of rejection or disease transmission as human's own bone is scraped which later used as a

*Corresponding author: Yashbir Singh Raghav
Lecturer, Swami Devi Dyal Hospital and Dental College, India

regenerative material (Soltan, 2005). Recently porous hydroxyapatite, a synthetic tricalciumphosphate biomaterial is commonly used as a bone tissue substitute because of its biocompatibility and osteo-conductibility properties (Alliot-Lich *et al.*, 1997). Nanocrystalline hydroxyapatite bind to bone and stimulate bone healing by stimulation of osteoblast activity. These crystals (Tricalcium phosphate) has a calcium to phosphate ratio of 1.5, is mineralogically β -whitelockite. This porous form has the potential to stimulate development of osseous tissue within the pore structure and also it is slowly broken down by the tissue within it.

MATERIALS AND METHOD

A total of 20 sites were selected from those attending the Out Patient Department (OPD) of Department. of Periodontology and oral implantology at Swami Devi Dyal Dental College and Hospital, Barwala, Panchkula. Patients who were diagnosed as suffering from moderate to advanced periodontitis along with radiographic evidence of periodontal osseous defects were selected for the study.

Inclusion criterion (Lekovic *et al.*, 2012)

- Patients in the age group of 20 to 65 years.
- Patients previously treated only by oral hygiene instructions and scaling and root planing.
- Clinical probing depth of at least 6 mm.
- Radiographic Presence of interproximal deep intraosseous defect of ≥ 3 mm from CEJ.

Exclusion criteria (Lekovic *et al.*, 2012)

- Subjects with a history of severe acute or chronic systemic diseases.
- Pregnant or lactating patients.
- Smokers.
- Subjects taking medication known to affect the gingival status.
- Endodontically treated teeth.
- Teeth with grade III mobility or with hopeless prognosis was not included.

Study Design

The subjects were clearly explained the study protocol and procedure in detail and a signed written consent was taken from them. A total of twenty sites having intra-bony defects as checked clinically and confirmed radiographically were selected and divided into two groups randomly, Group I and Group II.

Group I: Ten sites were treated with autogenous bone graft alone.

Group II: Ten sites were treated with nanocrystalline hydroxyapatite - β TCP crystal alone. (Sybograf-plus)

CLINICAL PARAMETERS

The following clinical parameters were recorded at baseline, at 3 months and 6 months post- operatively.

- Plaque index (PI) (SILNESS P AND LOE H,1964)¹¹
- Gingival index (GI) (LOE H AND SILNESS P, 1963)¹²
- Probing Pocket depth (PPD)
- Relative attachment level (RAL)

Radiographic Assessment

The intraoral periapical radiograph of each defect site was taken pre-operatively and post- operatively at 3 and 6 months using millimeter grid (X-Ray Mesh). (Figure 4) Radiographic evaluation was done at baseline, 3 months and 6 months.

Methodology

After evaluation of preclinical records (Fig 9, 24) and obtaining an adequate anesthesia, intra-sulcular incisions (Fig 1(a) , 2(a) with reflections of full thickness flap were utilized to retain as much soft tissue as possible in order to obtain primary closure. (Fig 1(b), 2(b) Debridement and root planing was accomplished with hand instruments in both groups. (Fig 1(c) , 2(c)

GROUP I: In group I, after through debridement, the surgical sites were irrigated with sterile saline, the osseous coagulum (mixture of bone shavings and blood) was collected with the help of bone scraper from the alveolar crest of adjacent teeth. (Fig 14) Then from the collecting chamber of bone scraper, coagulum was emptied into dampen dish (Fig (f) and then it was adapted to the defect site to reshape the alveolar crest profile with the help of plastic filling instrument.(Fig 1(g, h) The surgical sites was sutured. (Fig 1(i) Postoperative instructions and medications prescription was given after surgery.

GROUP II: In group II, Instead of coagulum, small increments of Alloplastic graft material (hydroxyapatite β -TCP mixed with saline) were added,(Fig 2(e,f) starting from the bottom of the defect. (Fig 2(g) The surgical site was sutured. (Fig 2(h) Postoperative instructions and medication prescription was given after surgery. After 7 to 10 days, sutures were removed. Any visible debris or plaque present in the area was also cleaned. The recall appointments were scheduled at 3 months and 6 months post surgically for soft tissue evaluation, plaque control, radiographic evaluation and for recording of clinical parameters.

RESULTS

Intra Group Analysis

The mean plaque index at baseline was $1.3 \pm .12$ whereas after 3 months and 6 months post operatively it was $1.03 \pm .08$ and $.84 \pm .03$ respectively for group I. In group II the mean plaque index at baseline was $1.43 \pm .34$ whereas the mean value after 3 months was $1.06 \pm .19$ and it was $.84 \pm .03$ at six months post operatively. For both groups, the mean difference of plaque index at 3 months and 6 months from baseline was highly significant. ($p < 0.001$). The mean gingival index at baseline was $1.38 \pm .11$ whereas the mean values after 3 months and 6 months postoperatively were $.94 \pm .075$ and $.74 \pm .038$ respectively for group I.

Intra- Group Comparison

Table 1. Showing Intragroup comparison of all parameters at baseline, 3 months and 6 months

S.N	Parameter	Group I			Group II			p-value
		Baseline	3 Months	6 Months	Baseline	3 Months	6 Months	
1	Plaque Index	1.3±.12	1.03±.08	.84±.03	1.43±.34	1.06±.19	.84±.03	P<0.001
2	Gingival Index	1.38±.11	.94±.075	.74±.038	1.44±.10	.99±.082	.73±.05	P<0.001
3	Probing Depth	7.5±.84	4.1±.99	2.5±.52	7.4±1.17	3.5±.52	2.3±.48	P<0.001
4	Relative Attachment Level	11.3±.94	8.0±1.15	6.3±.82	11.7±1.41	7.8±1.03	6.6±.84	P<0.001
5	Bone Fill	----	2.8±.58	2.8±.67	----	2.6±.57	2.9±.83	P<0.001
6	Bone Fill Percentage	----	34.5±10.7	33.9±16.6	----	35.1±9.6	27.9±16.1	P<0.001
7	Bone Resolution	----	2.4±.56	1.8±.91	----	2.2±.53	2.05±.43	P<0.001
8	Bone Resolution Percentage	----	31.0±13.07	47.3±25.4	----	33.7±10.4	37.9±8.8	P<0.001

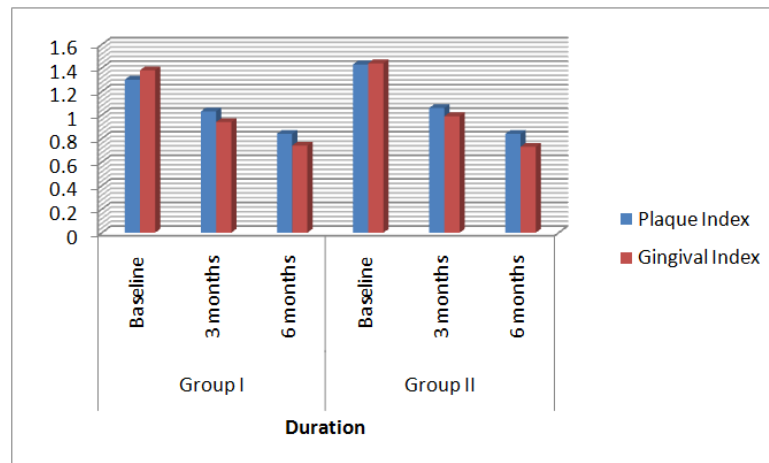
P<0.001 – Highly Significant

Inter Group Comparison

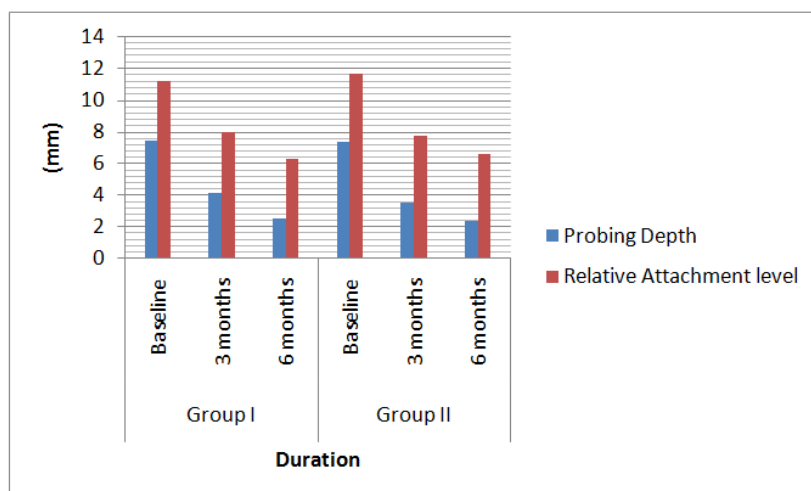
Table 2. Showing intergroup comparison of all parameters at baseline, 3 months and 6 months

S.N	Parameter	Group I vs Group II					
		Basement	“p”			“p”	
			3 Months	6 Months	Basement	3 Months	6 Months
1	Plaque Index	-.406	-.323	.000	.690 (NS)	.750(NS)	1.00(NS)
2	Gingival Index	-.122	-.560	-.922	.904 (NS)	.582(NS)	.369(NS)
3	Probing Depth	.218	1.68	.885	.830(NS)	.109(NS)	.388(NS)
4	Relative Attachment Level	-.741	.408	-.805	.468(NS)	.688(NS)	.431(NS)
5	Bone Fill	----	.575	-.443	----	.572(NS)	.663(NS)
6	Bone Fill Percentage	----	-.127	.817	----	.900(NS)	.424(NS)
7	Bone Resolution	----	.809	-.777	----	.429(NS)	.447(NS)
8	Bone Resolution percentage	----	-.502	1.10	----	.622(NS)	.284(NS)

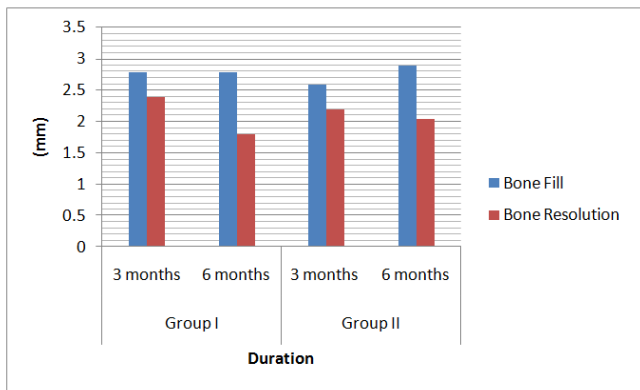
NS – Non Significant



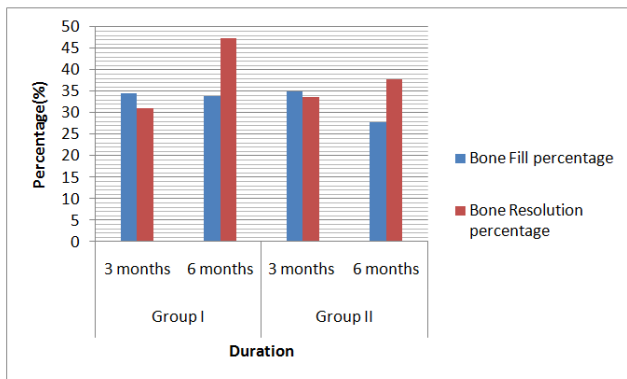
Graph 1. Showing graphical presentation of plaque index and gingival index at baseline, 3 months and 6 months



Graph 2. Showing graphical presentation of probing depth and relative attachment level at baseline, 3 months and 6 months



Graph 3. Showing graphical presentation of bone fill and bone resolution 3 months and 6 months



Graph 4. Showing graphical presentation of bone fill percentage and bone resolution percentage at 3 months and 6 months

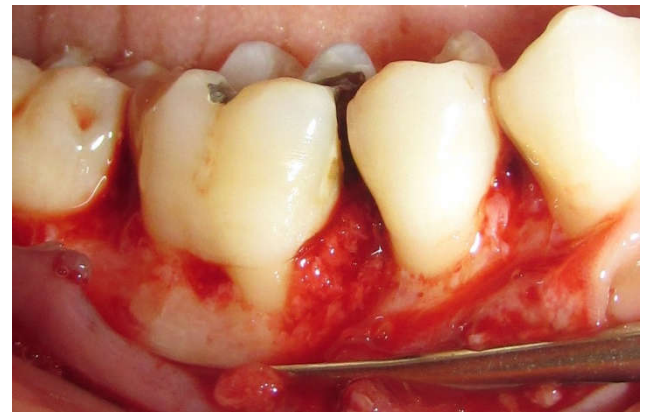


Fig. 1 (c). Placement of Autogenous bone into the defect

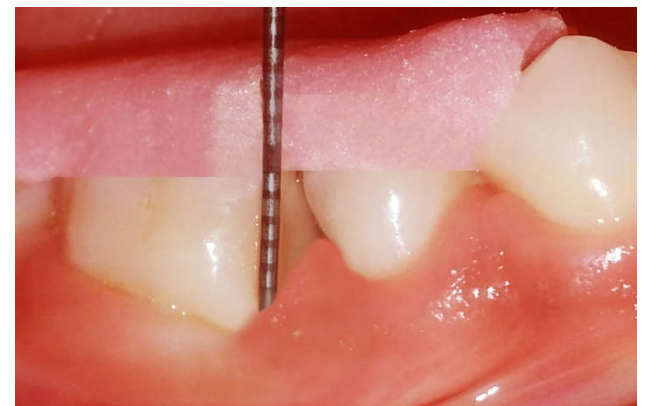

Fig. 1(d). Probing depth at 6 months

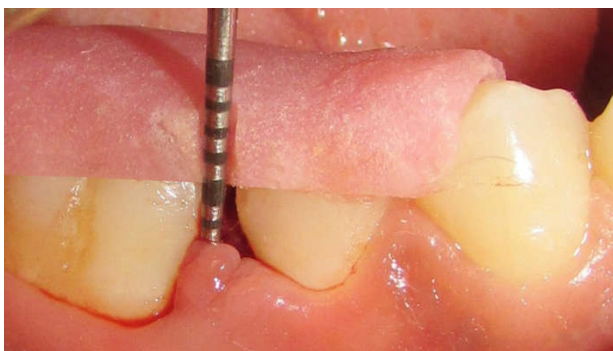

Fig. 1(a). Probing depth using acrylic stent & UNC-15 Probe at baseline

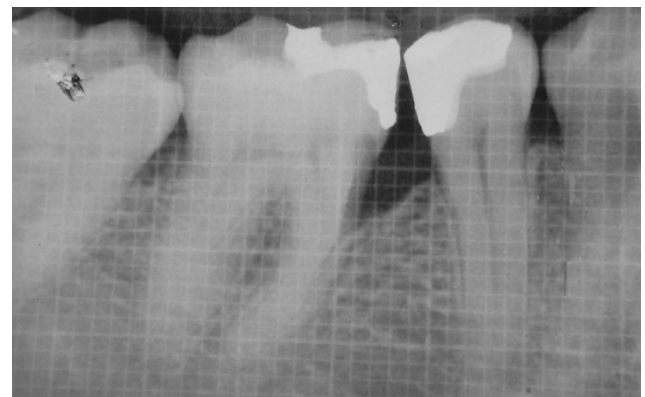


Fig. 1(e). X-Ray with Grid at baseline

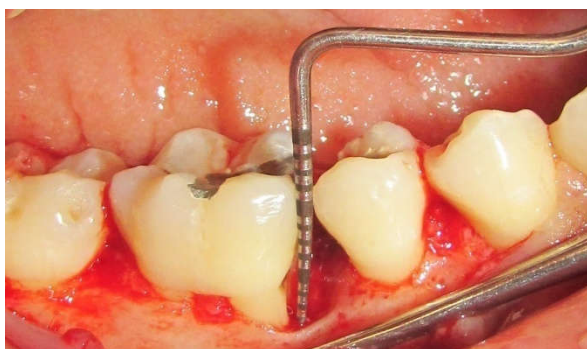


Fig. 1 (b). Reflection of full thickness mucoperiosteal flap along with defect depth with UNC- 15 after debridement

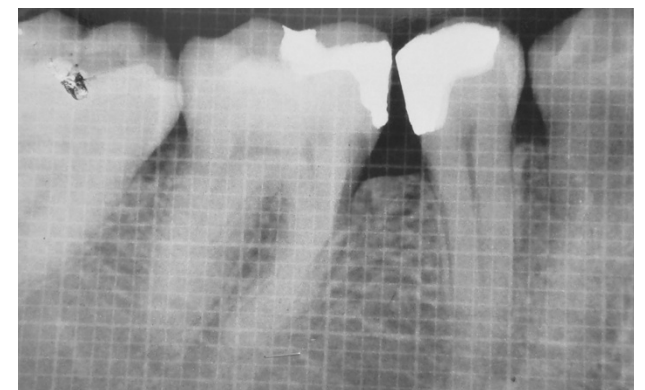


Fig. 1(f). X-Ray with Grid at 6 months

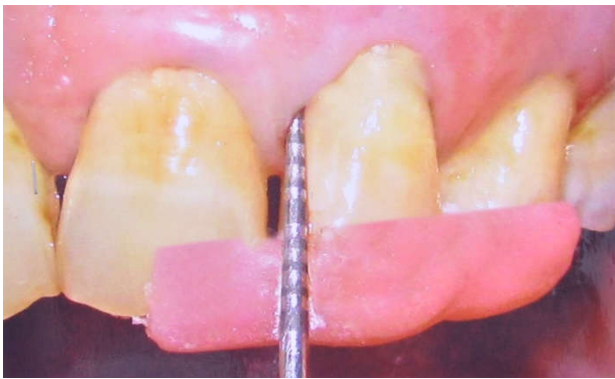


Fig. 2 (a). Probing depth using acrylic stent & UNC-15 Probe at baseline

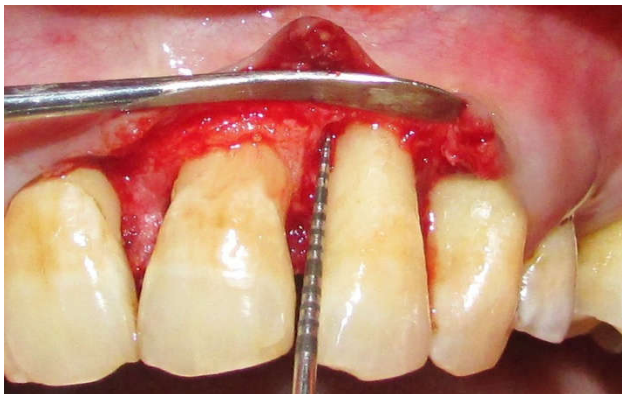


Fig. 2(b). Defect depth with stent after complete debridement

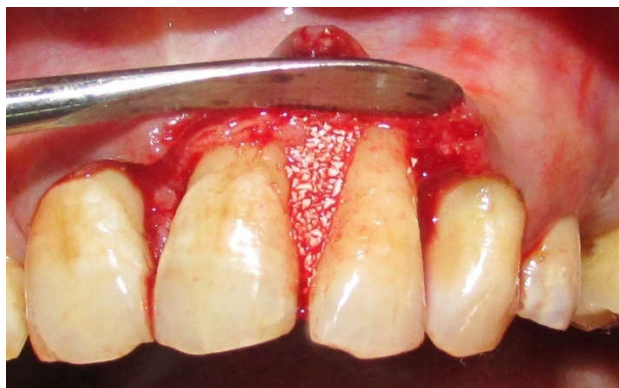

Fig. 2 (c). Placement of Alloplastic bone graft into the defect

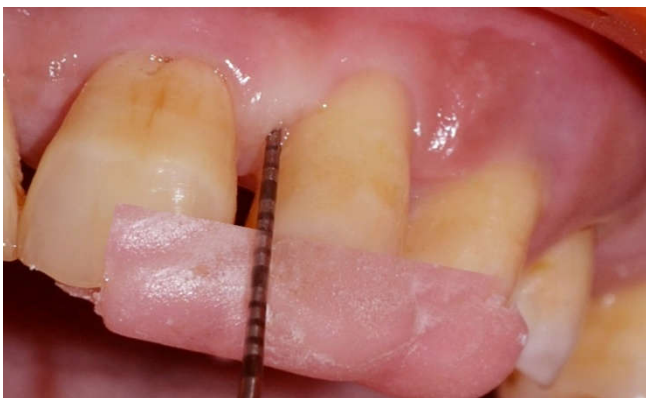

Fig. 2 (d). Probing depth at 6 months

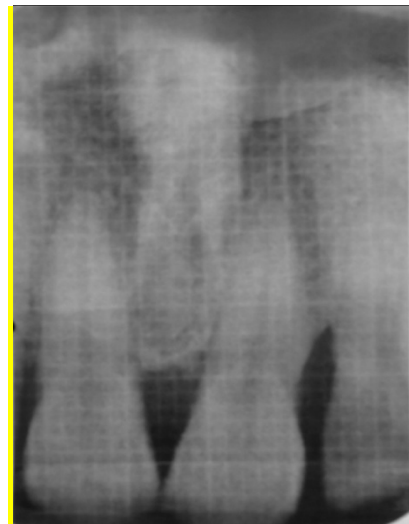

Fig. 2 (e). X-Ray with Grid showing intra-bony defect between 21 & 22 at baseline

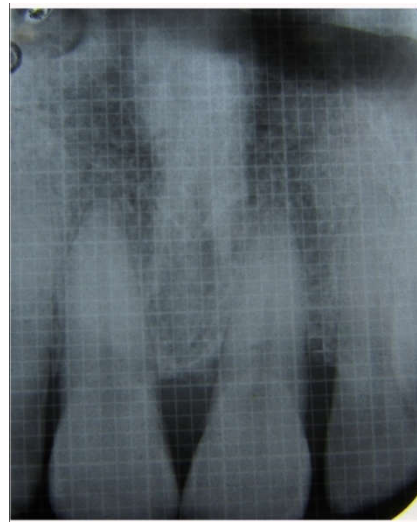

Fig. 2 (f). X-Ray with Grid showing intra-bony defect between 21 & 22 at 3 months interval

Group II presented mean gingival index $1.44 \pm .10$ at baseline whereas the mean values after 3 months and 6 months post operatively were $.99 \pm .082$ and $.73 \pm .05$ respectively. For both the groups, the mean difference of gingival index at 3 months and 6 months from baseline was highly significant ($p < 0.001$). The mean pocket depth recorded at baseline was $7.5 \pm .84$ mm whereas it was $4.1 \pm .99$ mm and $2.5 \pm .52$ mm at 3 months and 6 months respectively for group I. In group II, the mean pocket depth at baseline was 7.4 ± 1.17 mm and $3.5 \pm .52$ mm at 3 months. At 6 months $2.3 \pm .48$ mm was observed. For both the groups, the mean difference of pocket depth at 3 months and 6 months from baseline was highly significant ($p < 0.001$).

Group I had RAL $11.3 \pm .94$ mm at baseline, 8.0 ± 1.15 mm at 3 months and $6.3 \pm .82$ mm at 6 months. The mean RAL at baseline was 11.7 ± 1.41 mm whereas the mean values after 3 months and 6 months postoperatively were 7.8 ± 1.03 mm and $6.6 \pm .84$ mm respectively for group II. For both groups, there was highly significant ($p < 0.001$) mean difference of CAL at 3 months and 6 months postoperatively. The amount of defect

fill at 3 months and 6 months post operatively was $2.8 \pm .58$ mm and $2.8 \pm .67$ respectively for group I. In group II the amount of defect fill was $2.6 \pm .57$ mm at 3 months and $2.9 \pm .83$ mm at 6 months. The mean difference of amount of defect fill at baseline and 3 months was highly significant ($p < 0.001$) for both groups. Group I had amount of defect resolution $2.4 \pm .56$ mm and $1.8 \pm .91$ mm at 3 months and 6 months respectively. The amount of defect resolution at 3 and 6 months postoperatively was $2.2 \pm .53$ mm respectively for group II. The mean difference of amount resolution at 3 months and 6 months from baseline was highly significant ($p < 0.001$) for both the groups.

Inter group analysis

Group I and Group II has "t-value" $-.406$, $-.323$ and $.000$ at baseline, 3 months and 6 months respectively. No significant intergroup difference was observed for plaque index at baseline, 3 months and 6 months.

Group I and Group II has "t-value" $-.122$, $-.560$ and $-.922$ at baseline, 3 months and 6 months respectively. There was no significant intergroup difference in gingival index scores at baseline, 3 months and 6 months.

Group I and Group II has "t-value" $.218$, 1.68 and $.885$ at baseline, 3 months and 6 months respectively. There was no significant intergroup difference in mean pocket depth at baseline, 3 months and 6 months.

Group I and Group II has "t-value" $-.741$, $.408$ and $-.805$ at baseline, 3 months and 6 months respectively. No significantly intergroup difference was observed for RAL at baseline, 3 months and 6 months.

Group I and Group II has "t-value" $.575$ and $-.443$ at 3 months and 6 months respectively. Inter group comparisons at baseline, 3 months and 6 months for defect fill measurement were found to be non- significant.

Group I and Group II has "t-value" $.809$ and $-.777$ at 3 months and 6 months respectively. None of the between group comparisons were found to be significant statistically ($p > 0.05$) both at 3 and 6 months.

DISCUSSION

Intragroup Analysis

In our study, Plaque Index (Loe and Silness, 1963) and Gingival Index (Silness and Loe, 1964) showed statistically significant improvements from baseline to 3 and 6 months for both the groups ($p < 0.001$). These results were in contrast to those obtained by Lekovic V *et al* (2012), where there was no significant difference in these scores at baseline and at 6 months. The reduction of plaque and gingival scores could be attributed to the patient compliance and proper oral hygiene maintenance. In the present study, for both the groups, the mean difference of pocket depth reduction at 3 months and 6 months from baseline was highly significant ($p < 0.001$). Similar results were obtained by Ostby N *et al* (2008) in their

study wherein a significant pocket depth reduction was observed at 3 months, 6 months and 9 months.

The Relative Attachment Level (RAL) gain was highly significant for both the groups from baseline to 3 months and 6 months ($p < 0.001$). Similar results were obtained by Orsini M *et al* (2001) in their study wherein a significant gain in CAL/RAL occurred at 3 months and 6 months. Various studies have shown that if the selection of defect, smoking, plaque control and proper surgical protocols are followed it lead to high percentage of RAL gain, with different types of bone substitute graft and even with open flap debridement. In the present study, the mean amount of defect fill was statistically significant at 3 months from baseline among the both groups, the mean values being 2.8 mm for group I and 2.6 mm for group II ($P < 0.001$). At 6 month interval it was non-significant for group I as well as group II ($p > 0.001$). These results were similar to those obtained by Lekovic V *et al* (2012) where there was significantly defect fill occurs at 3 months and at 6 months ($p < 0.001$).

In the present study, the mean percentage of defect fill at 3 months and 6 months in group I sites was 34.5% and 33.9% and in group II was 35.1 % and 27.9% respectively which was statistically significant ($p < 0.001$). These results were similar to those obtained by Bowen JA *et al* (1989)¹⁵ where there was significantly defect fill percentage occurs at 3 months and at 6 months ($p < 0.001$). In the present study, the mean amount of defect resolution and defect resolution percentage was statistically significant at 3 months and 6 months for both the groups ($p < 0.001$). These results were similar to those obtained by Lekovic V *et al* (2012)¹⁰ where there was significantly mean amount of defect resolution and defect resolution percentage occurs at 3 months and at 6 months.

Intergroup Analysis

In the present study, the difference between the two groups for Plaque Index (Loe and Silness, 1963) and Gingival Index (Silness and Loe, 1964) were non-significant at all time intervals ($p > 0.001$). These results were similar to those obtained by Lekovic V *et al* (2012) where there was not significantly difference in indices score between two groups at baseline and at 6 months. In the present study, the intergroup comparison for pocket depth revealed statistically non-significant difference at baseline, 3 months and 6 months ($p > 0.001$). These results were similar to those obtained by Scabbia A *et al* (2004)¹⁶ where the results demonstrated that no statistically significant differences were detected between the groups. Similarly, the intergroup comparison of RAL gain was non-significant at all time intervals ($p > 0.001$). These results were similar to those obtained by Scabbia A *et al* (2004)¹⁶ where there was non- significant CAL gain between the groups at 3 months and at 6 months.

There was no statistically significant difference in defect fill amount and defect fill percentage amongst the groups at 3 months and 6 months ($p > 0.001$). However group II has better defect fill mean value (2.9 mm) compare to defect fill mean value (2.8 mm) of group I due to fact that the resistance of HA to resorption and degradation may be advantages for

maintaining the initial dimension, also it is osteoconductive and act primarily as inert biocompatible filler thereby conceding more defect fill in Autogenous than HA group. These results were similar to those obtained in a study conducted by Bowen JA *et al* (1989) where the intergroup bone fill values were not significantly different for both graft preparations. In the present study, on intergroup comparison of defect resolution and defect resolution percentage there was no significant statistically difference among the both groups ($p>0.001$). These results were similar to those obtained by Lekovic V *et al* (2012) where there was non- significantly difference in defect resolution between the two groups at 3 months and at 6 months

Conclusion

Autogenous bone obtained with a bone scraper can be considered as an advantageous technique, since the instrument is easily available, reasonably priced, not time consuming and not very technique sensitive. Furthermore, the bone material obtained by the means of this bone scraper is already in a particulate state, thus reducing operating time. Porous HA used can be considered a biocompatible filling material resulting in a significant defect fill. The study further supports the hypothesis that the autogenous bone graft has the potential disadvantage of involving a higher degree of resorption of the graft material as it obtains mainly bone from the outer cortical plates and relatively lesser amount of bone from the cancellous portion.

REFERENCES

- Alliot-Lich, B, De Lange, D.L, Gregorie, M. 1997. Effects of hydroxyapatite particles on periodontal ligament fibroblast-like cell behavior. *J Periodontol*, 68:158-65
- Blay, A., Tunchel, S., Sendyk, W.R. 2003. Viability of Autogenous bone grafts obtained by using bone collectors: histological and microbiological study. *Pesqui odontol Bras*, 17:234-40
- Bowers, G.M. 1989. Histologic Evaluation of New Attachment Apparatus Formation in Humans. *J Periodontol*, 60 : 675-682
- Callan, D.P. and Rohrer, M.D. 1993. Use of bovine-dried hydroxyapatite in the treatment of edentulous ridge defects: A human clinical and histologic case report. *J Periodontol*, June:575-582
- Callan, D.P. and Rohrer, M.D. 1993. Use of bovine-dried hydroxyapatite in the treatment of edentulous ridge defects: A human clinical and histologic case report. *J Periodontol*, June:575-582
- Gurinsky, B.S., Mills, M.P., and Mellonig, J.T. 2004. Clinical Evaluation of Demineralized Freeze- Dried Bone Allograft and Enamel Matrix Derivative Versus Enamel Matrix Derivative Alone for the treatment of Periodontal Osseous Defects in Humans. *J Periodontol*, 75 : 1309-1318
- Hanna, R, Trejo, PM, and Weltman, RL. 2004. Treatment of Intrabony Defects with Bovine-Derived Xenograft Alone and in Combination with Platelet-Rich Plasma: A Randomized Clinical Trial. *J Periodontol*, 75:1668-1677
- Lekovic, V, Milinkovic, I, Aleksic, Z, Jankovic, S, Stankovic, P, Kenney, E.B, Camargo, P.M. 2012. Platelet-rich fibrin and bovine porous bone mineral vs. platelet-rich fibrin in the treatment of intrabony periodontal defects. *J Perio Res Dent.*, 47:409-417
- Lindhe, J, Okamoto, H, Yoneyama, T, Haffajee, A and Socransky, SS. 1989. Periodontal laser sites in untreated adult subjects. *J Clin Periodontol.*, 16 : 671-690
- Loe, H, Sinless, J. 1963. Periodontal disease in pregnancy I. Prevalance and Severity. *Acta Odont Scand.*, 21: 533-51
- Mellonig, J.T., Bowers, G.M., Bailey, C. 1981. Comparison of bone graft materials. *J Periodontol.*, 52 : 291-296
- Nabers, C.L, O'Leary, T.J. 1965. Autogenous bone transplants in the treatment of osseous defects. *J Periodontol.*, 36:5.
- Nasr, HF, Aichelmann-Reidy, ME and Yukuna, RA.1999. Bone and bone substitutes. *Perio* 19 : 74-86
- Newman MG, Takei HH, Klokkevold PR, Carranza FA. Clinical Periodontology. 10th Edition: WB Saunders Company.
- Silness J, and Løe H. 1964. Periodontal Disease in Pregnancy II. Correlation Between Oral Hygiene and Periodontal Condition', *Acta Odontologica Scandinavica*, 22: 1, 121 — 135
- Soltan, M., Smiler, D.G., Gailani, F. 2005. A new "Platinum" standard for bone grafting: Autogenous stem cells. *Implant Dentistry*, 14: 322-327
- Yamamiya, K, Okuda, K, Kawase, T, Hata K, Wolf, LF, Yoshie, H. 2008. Tissue-Engineered Cultured Periosteum Used With Platelet-Rich Plasma and Hydroxyapatite in Treating Human Osseous Defects. *J Periodontol.*, 79 : 811-818
