



## RESEARCH ARTICLE

### DIFFERENT TYPES OF RADIATION PROSTHESES TO MINIMIZE RADIATION SIDE-EFFECTS

<sup>1</sup>Dr. Jayant Palaskar, <sup>\*</sup><sup>1</sup>Dr. Zankhana S. Mody, <sup>2</sup>Dr. Shreyas S. Mohile, <sup>1</sup>Dr. Jyoti H. Wankhade,  
<sup>1</sup>Dr. Sayali R. Korde and <sup>1</sup>Dr. Nikita M. Virdiya

<sup>1</sup>Department of Prosthodontics and Crown & Bridge, Sinhgad Dental College and Hospital, Pune

<sup>2</sup>Department of Oral and Maxillofacial Surgery, Dr. D.Y PatilVidyapeeth's, Dr. D.Y Patil Dental College and Hospital, Pimpri, Pune

#### ARTICLE INFO

##### Article History:

Received 24<sup>th</sup> March, 2016

Received in revised form

06<sup>th</sup> April, 2016

Accepted 05<sup>th</sup> May, 2016

Published online 30<sup>th</sup> June, 2016

##### Key words:

Radiation prostheses, Radiation stents,  
Head and Neck cancer, Cerrobond,  
Radiotherapy.

#### ABSTRACT

Radiation prosthesis is an artificially fabricated device that aids in the efficient administration of radiotherapy to the affected areas and thereby helps in limiting post radiotherapy complications. Radiotherapy is being used as an adjunctive form of treatment in the management of head and neck cancer. Adverse tissue reactions are associated with the use of radiotherapy in the management of patients with head and neck cancer. These reactions are painful and they diminish the quality of life, often discouraging the patient from taking treatment. A prosthodontist can help the Radiotherapist in radiotherapy of the patient by fabrication of certain devices. These devices are shielding devices, positioning stents and radiation source carriers. Radiation shielding devices minimize exposure of the surrounding healthy tissues, positioning devices help in delivering radiation to desired area, while radiation source carrier is used for radiation of intraoral localized area. This article aims at displaying the various prostheses that can be given to oral cancer patients to provide better treatment and decrease post radiation complications. The use of these devices is individualized and close collaboration between the radiotherapist and the prosthodontist is essential. Use of these devices minimizes severity of the problems, improves the prognosis and provides comfort to the patient. Radiation therapy is employed by many institutions and the dentist must be aware of the appliances that can be fabricated to prevent the undesirable side effects of radiation.

Copyright©2016, Dr. Jayant Palaskar et al. This is an open access article distributed under the Creative Commons Attribution License, which permits unrestricted use, distribution, and reproduction in any medium, provided the original work is properly cited.

Citation: Dr. Jayant Palaskar, Dr. Zankhana S. Mody, Dr. Shreyas S. Mohile, Dr. Jyoti H. Wankhade, Dr. Sayali R. Korde and Dr. Nikita M. Virdiya, 2016. "Different types of Radiation Prostheses to minimize radiation side-effects", International Journal of Current Research, 8, (06), 33575-33578.

## INTRODUCTION

The use of radiation energy has steadily increased since the discovery of X-rays by Roentgen in 1895 and of radium by Curie in 1898. In the past, lack of knowledge in this type of radiation too frequently resulted in radiation damage to the patient and to all involved in giving the treatment (Santiago, 1973). Therapeutic responses to intraoral carcinoma include surgery, radiation and chemotherapy. Radiation is divided into extraoral and intraoral therapy (Kabacnel, 1980). The radiotherapist should consult the dentist before starting the radiation therapy in the region of the oral cavity. Complications may develop in the tongue, teeth, salivary glands, mucosa, maxilla and mandible. A large number of patients have been reported with radiation caries and radionecrosis following treatment. Furthermore, the sense of taste may be impaired, the amount and consistency of saliva may be altered and ulcers may be produced in the mucosa (Santiago, 1973). Prosthesis used in radiotherapy in the oral and paraoral region have been classified by Drane and Rahm as locators, carriers and stents (Rahn and Drane, 1967).

The prosthodontist can actively help in the rehabilitation of cancer patients by fabricating the whole array of possible prosthesis that can be custom made and decrease or prevent the complications following radiotherapy (Goswami et al., 2013).

### Pretreatment of Oral Malignancies

The radiotherapist should consult the dentist before starting radiation therapy in the oral cavity. Complications may develop in the tongue, teeth, salivary glands, mucosa, maxillae and mandible. A large number of patients have reported with radiation caries and radionecrosis following the treatment. Furthermore, the sense of taste may be impaired, the amount and consistency of the saliva may be altered and ulcers may be produced in the mucosa (Santiago, 1965). Rahm and Drane recommended that the teeth in the field of radiation, those periodontally involved, those with extensive carious lesions and otherwise questionable teeth be extracted with least possible trauma. They also believed that the teeth needing restorations should be treated before radiation therapy and such treatment should be accompanied by topical application of fluoride before, during and after radiation therapy (Rahn and Drane, 1967).

\*Corresponding author: Zankhana Mody, Department of Prosthodontics and Crown & Bridge, Sinhgad Dental College and Hospital, Pune.

## Radiation therapy in Oral Malignancies

Radiation therapy must be directed to the smallest possible area of the tissue. Dentist can help radiotherapist in treating patients with oral and paraoral lesions. The dentist can make a prosthesis that will enable the radiotherapist to provide a better treatment to the patient. Most important the prostheses are comfortable and immobile while treatment is in process (Delclous, 1965).

## Post treatment of Oral Malignancies

Following radiotherapy treatment, dentist should be consulted regarding oral problems that may develop. Teeth that become carious need to be restored. Extractions may produce complications like radionecrosis (Santiago, 1965). Patients having reduced salivation may be given salivary reservoir prosthesis by the prosthodontist.

## Prosthesis in Radiotherapy

A number of prosthesis made by the dentist help the radiotherapist in treating patients with malignancies of oral and paraoral tissues (Santiago, 1965). They can be divided into the following types:

### 1. The carrier prosthesis

These prosthesis hold radium or cesium-137 securely in a planned site during every treatment (Santiago, 1965). These prosthesis administer radiation to a confined region by means of capsules, beads or needles of radiation emitting materials. These carriers are of two types, preloaded carriers and after loaded carriers. The after loaded carriers are usually advantageous compared to preloaded carriers as the radioactive sources are placed after the carrier is in position. Thus minimizing the radiation exposure to the personnel handling, positioning and securing such devices. These devices can also be classified as intracavity devices and interstitial devices. Intracavity devices deliver high doses of radiation to tumours that are located within 6cm of the skin surface. The doses are 6500-7500 rads for 6-7 weeks. The interstitial devices (brachytherapy) deliver high doses of radiation for a short period of time, i.e. 10-15 hours (Goswami *et al.*, 2013). Interstitial devices place the encapsulated radiation source (needles, narrow tubes or seeds containing radioactive cesium, cobalt, gold or iridium) within the tumour or very close to the surface (Kasat *et al.*, 2010).

- Two-piece radiation carrier (Figure 1): Once the radiotherapist gives the position of the lesion and the desired field of radiation on the maxillary cast, the prosthodontist fabricates a two-piece radiation carrier device which consists of radium needles. The first stent is constructed on the cast. Grooves are made on this stent to provide space for the radium needles. Another stent is made over the first stent and attaches via snap attachment (magnets, buttons, etc.) The advantage of this prosthesis is that the radium needles are held securely between the two stents and can be comfortably worn by the patient for the required time without dislodgement of the needles (Kabcenell, 1980).

- Radiation carrier device for edentulous mandible (Figure 2): In this prosthesis, a denture base consisting of radium needles at the required sites was fabricated by the dentist.
- Afterload radiation carrier device (Figure 3): In this prosthesis, the dentist provides hollow catheters in predetermined locations. Once the carrier is in position, radioactive isotopes are threaded into the hollow tubing, allowing for quick and radiation. The advantages of afterload over preload technique (the above two prostheses), is that, in preload carrier, the radioactive source is positioned within the prosthesis before the carrier is inserted. This method creates urgency of placement of the prosthesis because the staff members are exposed to potentially hazardous radiations while performing the procedure (Derhei *et al.*, 2003).

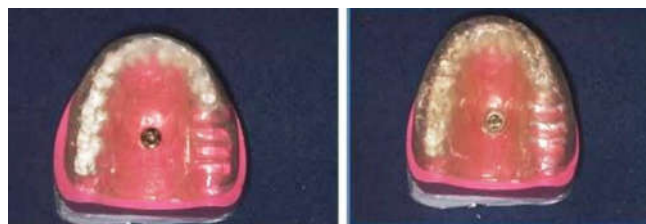

Figure 1.

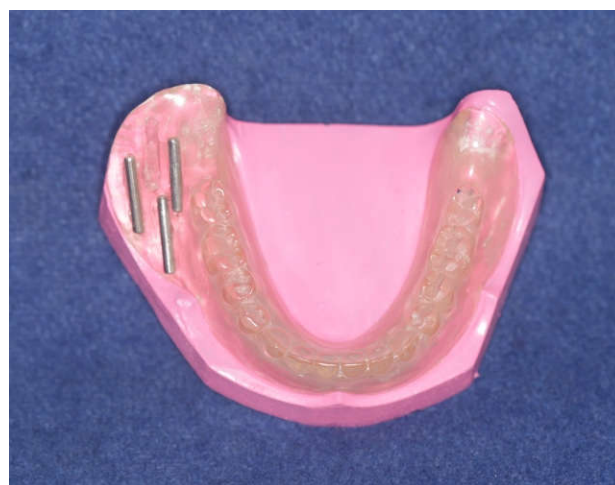


Figure 2.

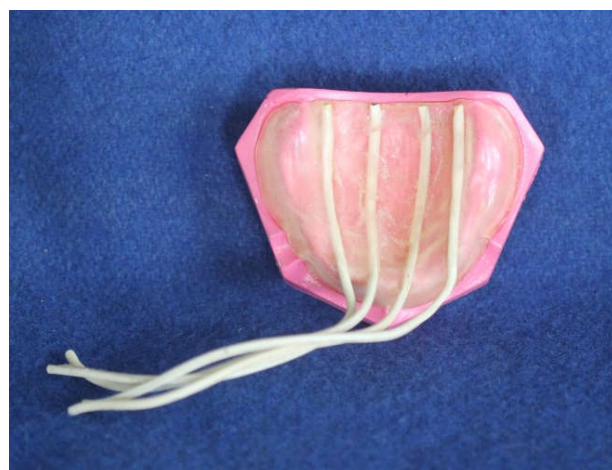

Figure 3.

## 2. Positioning devices (Figure 4)

Prostheses that displace the movable tissues away from or towards the source of radiation. Example: the lips, tongue, cheeks and soft palate may need to be directed away from the source of radiation to prevent their damage or maybe directed towards the source when indicated (Santiago, 1965)

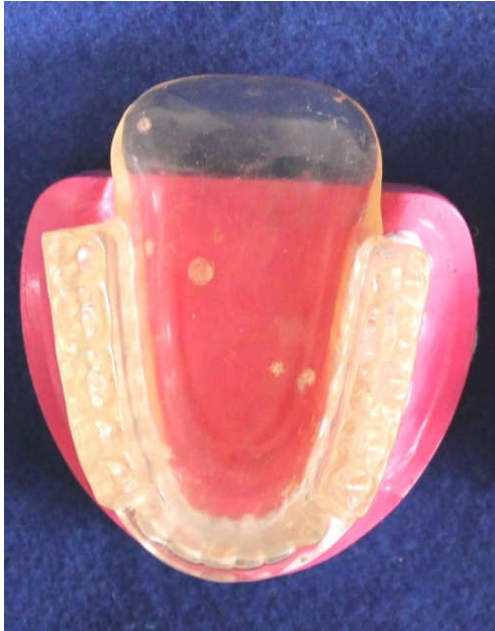

Figure 4.

## 3. Perioral cone positioning stent (Figure 5, 6)

This prosthesis holds the intraoral cone in a definite position and also places the tongue away from the field of irradiation (Goswami *et al.*, 2013; Santiago, 1965) Most intraoral cones in radiation therapy range from 3-4cm. For treating oral lesions, it is important that the cone be in contact with the oral mucosa within the entire perimeter of the treatment field. This is seldom possible due to varied topography of the mouth (Parel and Drane, 1975). Whenever there is a space between the mucosa and the radiation cone, two things may occur: First, normal tissue outside the radiation field may be irradiated. Second, the desired dose to the tumour field is diminished by an amount proportional to the square of the distance between the end of the metal extension and the tissue (inverse square rule) (Beder, 1959). Some authors advocated the use of lead cylinders around the radiation cone to prevent irradiation of surrounding normal tissues. However, due to hazards associated with the use of lead, mostly related to its high melting point and potential toxicity, several alloys that melt at lower temperatures have been used in place of pure lead for intraoral shielding. For example, Cerrobend (a bismuth-tin-lead alloy) is used. Perioral cone positioning stent consists of three parts: the first part is a cylindrical cone in which the radiation cone will fit. It is made up of acrylic resin and is 5-6cm long. The second part consists of a maxillary record base (edentulous patient) or occlusal indices (dentulous patient). The third part consists of another small ring made of cerrobend alloy which joints the acrylic cone to the denture base (Santiago, 1975).



Figure 5.

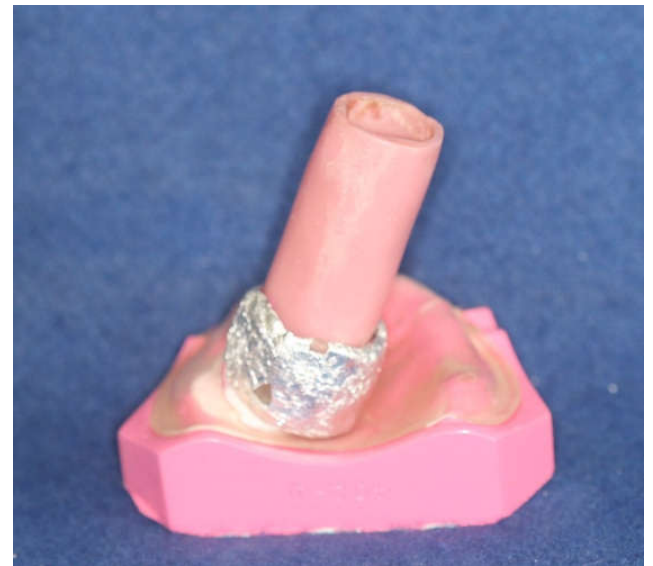

Figure 6.

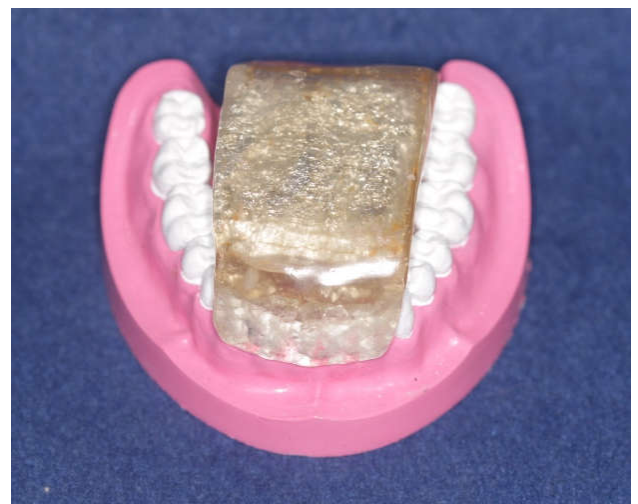


Figure 7.

## 4. Shielding stent / Protection stent (Figure 7)

A shielding stent of specific thickness of acrylic and containing lead or cerrobend can be used to protect structures

which are adjacent to the radiation therapy sites. This prevents radiation to the surrounding normal tissues and prevents any side effects. Eg: tongue shielding devices, lip shielding devices (Goswami *et al.*, 2013; Santiago, 1965). When the radiation is directed at the buccal mucosa, the skin, mucosa and alveolar bone adjacent to it undergo irradiation too. A cheek shielding device containing cerrobend can be placed intraorally in the buccal vestibule, thus protecting the intraoral tissues (Aramany and Drane, 1972).

#### 5. Radiation measuring stent / Dosimeter positioning stents:

These prostheses contain lithium fluoride capsules that enable the radiotherapist to measure radiation received by tissues in contact with the capsule (Santiago, 1973).

#### 6. Tissue recon touring stents

These stents are useful when the beam is adjusted for midlines for treating skin lesions associated with lips. Due to curvature of lip, low doses of radiation are delivered at the corner of the mouth whereas higher doses are delivered at the midline. These stents flatten the lips and the corner of the mouth thereby placing the entire lip in the same plane and providing equal and exact radiation dose (Goswami *et al.*, 2013).

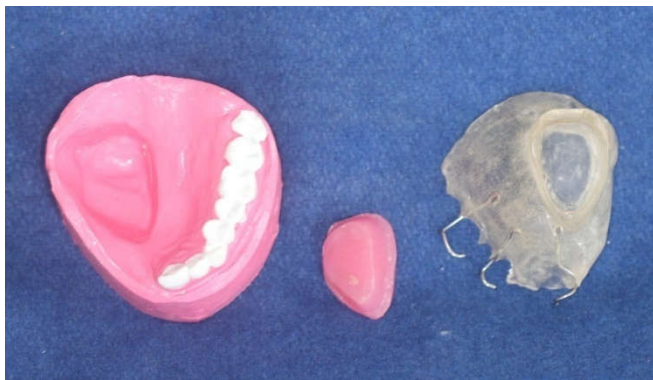

Figure 8.

#### 7. Tissue bolus compensators / Balloon bolus supporting stents (Figure 8)

These prostheses help in treatment of superficial lesions of face with irregular contours. Due to irregularities in the lesion, some areas within the field maybe untreated while others may develop isolated hotspots (Mantri and Bhasin, 2010). Bolus is a tissue equivalent material which is placed directly onto the irregularities that helps in converting irregular tissue contours into flat surfaces which are perpendicular to the central access of the ionizing beam, to thereby more accurately aid in the homogenous distribution of the radiation (Brosky *et al.*, 2000).

#### Conclusion

Generally patients who have oral cancers have to undergo surgical resection of the malignant tumour which affects patient's quality of life. Radiotherapy plays a significant role in the treatment modalities of oral cancer. Due to radiation

procedures, irradiation of the nearby normal tissues including the salivary glands can occur, leading to severe consequences. Prosthodontist can provide radiation prostheses which reduce or eliminate many oral complications associated with radiotherapy. These prostheses reduce the irradiation to the surrounding normal tissues and thus prevent the adverse consequences of irradiation. It is thus recommended that a multidisciplinary approach be considered while treating a patient with head and neck cancer wherein a surgeon, a radiotherapist and a prosthodontist must be on the team for consultation before planning the treatment. These measures will help provide better treatment and improve the quality of life of the patient.

#### REFERENCES

- Aramany, M. A. and Drane, J. B. 1972. Radiation protection prosthesis for edentulous patients. *J Prosthet Dent.*, 27(3):292-296.
- Beder, O. E. 1959. Surgical and maxillofacial prosthesis, Seattle, The University of Washington Press, P. 25.
- Brosky, M., Lee, C., Barlett, T., Lo, S. 2000. Fabrication of radiation bolus prosthesis for the maxillectomy patient. *J Prosthet Dent.*, 83(1):119-120.
- Delclous L. Radiotherapy for head and neck cancer teamwork: Problems common to physician and dentist. *J Prosthet Dent* 1965;15:157-167.
- Derhei, P. M., Lim, W. C., Timmerman, R. D. and Andres, C. J. 2003. Use of computed tomography for fabrication of a custom brachytherapy carrier: A clinical report. *J Prosthet Dent.*, 89(1):15-18.
- Goswami, R., Agarwal, K. and Gaba, N. 2013. Prosthetic Carriers for Radiation Therapy of Head and Neck. *British Biomedical Bulletin*, 1(2):136-146.
- Kabcenell, J. L. 1980. A two piece radiation therapy surface mold. *J Prosthet Dent.*, 43(1):86-88.
- Kasat, V., Sahuji, S. and Joshi, M. 2010. Radiotherapy: An update. *JIAOMR*, 22(4):26-30.
- Mantri, S. S. and Bhasin, A. S. 2010. Preventive Prosthodontics for Head and Neck Radiotherapy. *J ClinDiagn Res.*, 4:2958-2962.
- Miyamoto, R. H., Fleming, T. J., Davis, M. G. 1992. Radiotherapeutic management of an orocutaneous defect with a balloon retaining stent. *J Prosthet Dent.*, 68(1):115-117.
- Parel, S. M. and Drane, J. B. 1975. A modified intraoral prosthesis for directing a radiation beam. *J Prosthet Dent.*, 33(6):666-671.
- Rahn, A. O. and Drane, J. B. 1967. Dental aspects of the Problems, Care and Treatment of Irradiated Oral Cancer Patient. *J Am Dent Assoc.*, 74:957-966.
- Santiago, A. 1965. An intraoral stent for the direction of radiation beam therapy. *J Prosthet Dent.*, 15(5):938-944.
- Santiago, A. 1965. Use of intraoral prosthesis in radiotherapy. *Med Rec Ann.*, 58:3-11.
- Santiago, A. 1973. The role of the dentist in radiotherapy. *J Prosthet Dent.*, 30(2):196-201.
- Santiago, A. 1975. Fabrication of intraoral radiotherapy prostheses. *J Prosthet Dent.*, 34(2):212-215.