



## CASE STUDY

# HYPONATREMIC ENCEPHALOPATHY - AN UNCOMMON PRESENTATION OF SHEEHAN'S SYNDROME

Harris P, Feroz P Jenner, S. Vijayalekshmi and Shazam Aboobacker

Clinical Assistant Professor, Department of Internal Medicine, MES Medical College and Hospital, Perinthalmanna

### ARTICLE INFO

#### Article History:

Received 22<sup>nd</sup> June, 2016  
Received in revised form  
25<sup>th</sup> July, 2016  
Accepted 17<sup>th</sup> August, 2016  
Published online 30<sup>th</sup> September, 2016

#### Key words:

Sheehan's syndrome, Postpartum hypopituitarism, Postpartum pituitary necrosis.

Copyright©2016, Harris et al. This is an open access article distributed under the Creative Commons Attribution License, which permits unrestricted use, distribution, and reproduction in any medium, provided the original work is properly cited.

Citation: Harris P, Feroz P Jenner, S. Vijayalekshmi and Shazam Aboobacker, 2016. "Hyponatremic encephalopathy - An uncommon presentation of sheehan's", *International Journal of Current Research*, 8, (09), 38825-38827.

### ABSTRACT

Sheehan's syndrome also known as postpartum hypopituitarism or postpartum pituitary necrosis is a condition in which hypopituitarism develops after severe bleeding during or immediately after childbirth. Here we report the case of a lady who presented with hyponatremic encephalopathy, and was diagnosed to have Sheehan's syndrome after detailed evaluation.

## INTRODUCTION

Sheehan's syndrome is a rare complication of postpartum hemorrhage first described in 1937 (Sheehan, 1937). The anterior pituitary is more susceptible to damage than the posterior pituitary. Failure to lactate or difficulties with lactation are the common initial symptoms of Sheehan's syndrome. Hyponatremia, anemia, and low bone mass are frequently seen in patients with Sheehan's syndrome. Its diagnosis is based on the clinical features of associated hormone deficiency, a suggestive obstetric history, laboratory finding of low levels of trophic hormones in the setting of low levels of target hormones, and related radiological features. Treatment requires lifelong replacement of deficient hormones.

### Case report

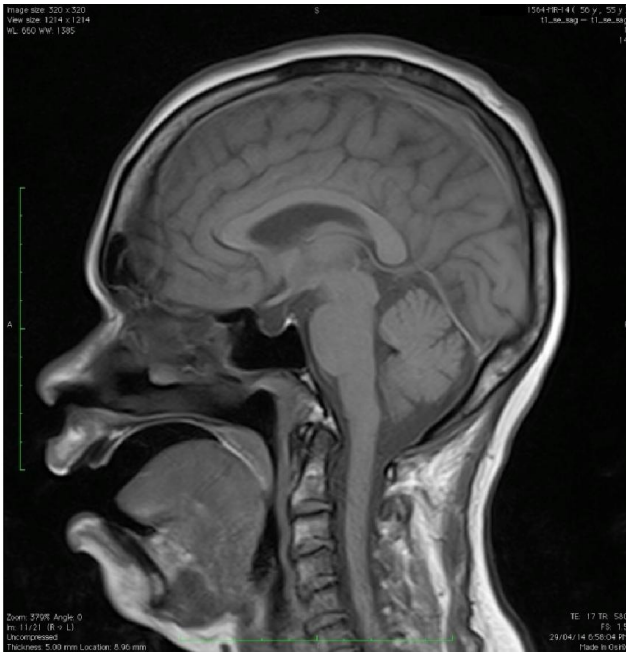A 55 year old lady presented with history of generalized tiredness and altered sensorium of two weeks duration. Clinical examination showed blood pressure 100/60 mm of Hg, Glasgow Coma Scale score of 10/15. Pupils were normal in size with normal light reflex. There were no signs of meningeal irritation or any localizing neurological signs. Other systemic

examination was unremarkable. Blood investigations revealed Hemoglobin 10.7 gm/dl, Total Leucocyte count 4600 cells/cmm, Platelet count 240000/cmm, ESR 20 mm at the end of first hour. Peripheral blood smear was suggestive of normocytic normochromic anemia. Random blood sugar was 98 mg/dl, Serum Sodium 109 mEq/L, Serum Potassium 4.8 mEq/L, Serum Calcium 8.5, Serum Magnesium 1.5, Serum Osmolality - 233 mOsmol/kg, Urine Osmolality - 258.8 mOsmol/kg, Spot urine sodium - 113 mEq/L. Renal function tests and liver function tests were normal. On review of her past medical history, it was noted that she had been having recurrent episodes of symptomatic hyponatremia and hypoglycemia, which were being treated by hypertonic saline and dextrose infusion. She had also been diagnosed as having hypothyroidism, and was prescribed levothyroxine. On review of her obstetric history, it was noted that her last delivery was complicated with severe post-partum hemorrhage. She also had post-partum lactation failure and secondary amenorrhea. With the above clinical information, she was suspected to have postpartum hypopituitarism, and was evaluated. Free T4 - 0.68 ng/dl (0.7-2.2), Free T3 - 1.56 pg/dl (1.5-4.5), TSH - 0.80 mIU/ml (0.3-5.5), 8:00 AM Serum Cortisol - 0.30 µg/dl (6.2 - 19.4), Serum Albumin - 3.7 gm/dl, ACTH - 9.9 pg/ml (0-46), Growth Hormone (GH) - 0.058 ng/mL (0.15-10), Prolactin - 1.84 ng/ml (3.7-17.9), LH - 1.81 mIU/ml (2- 18), FSH - 0.216 mIU/ml (more than 40), Estradiol E2 - 10 pg/ml (less than 28).

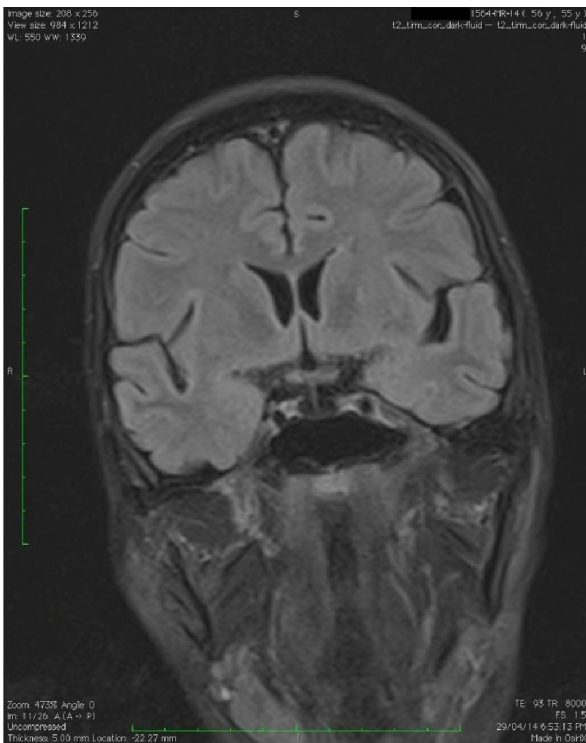
\*Corresponding author: Harris, P.

Clinical Assistant Professor, Department of Internal Medicine, MES Medical College and Hospital, Perinthalmanna.

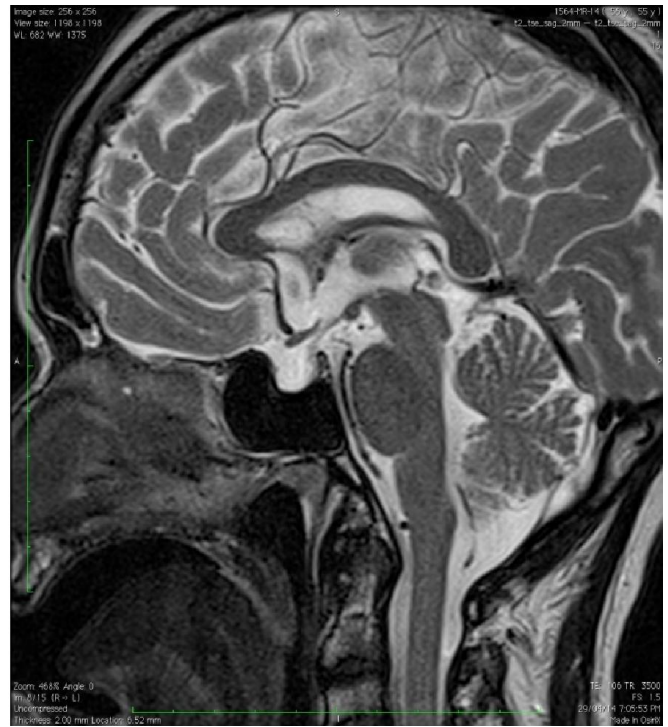A magnetic resonance imaging of the brain was done which showed empty sella with normal posterior pituitary. The patient was diagnosed of having Sheehan's syndrome with hyponatremic encephalopathy by clinical manifestations, laboratory tests and magnetic resonance imaging. Her encephalopathy improved with restriction of fluid intake and hypertonic saline. She was also initiated on hormone replacement therapy, which led to improvement in her general condition, and she was discharged from hospital.



**Image 1. T1 sagittal section of MRI Brain showing empty sella. Posterior pituitary is seen intact**



**Image 2. Coronal section of MRI Brain showing empty sella with intact posterior pituitary**



**Image 3. T2 sagittal section of MRI Brain showing empty sella. Posterior pituitary is seen intact**

## DISCUSSION

The pituitary gland plays a critical role in regulating the function of downstream glands, and also exerts independent endocrine actions on a wide variety of peripheral organs and tissues. Pituitary and surrounding sellar structures can be significantly damaged by acute hemorrhagic vascular events. Common causes are preexisting adenoma, postpartum hemorrhage, or in association with diabetes, hypertension, sickle cell anemia, or acute shock. The pituitary gland is enlarged in pregnancy and is prone to infarction from hypovolemic shock. Sheehan's syndrome, first described by Sheehan in 1937 is postpartum hypopituitarism caused by ischemic necrosis due to blood loss and hypovolemic shock during and after child birth. The anterior pituitary is more susceptible to damage than posterior pituitary. Presentation of Sheehan's syndrome may be acute or chronic. The acute form is very rare and diagnosis of the chronic form may be delayed for many years. This interval may be as long as 15 to 20 years. (De Groot, 1989) Lethargy, amenorrhea and failure of lactation are the usual presenting features. Characteristic manifestation of Sheehan syndrome include failure to lactate, amenorrhea, genital & axillary hair loss, asthenia, weakness, sign of premature ageing, dry skin, hypopigmentation & other evidence of hypopituitarism. Hyponatremia is a rare acute presentation of Sheehan's syndrome. (Boulanger *et al.*, 1999) Several mechanisms are responsible for hyponatremia. Independent of vasopressin, hypothyroidism and glucocorticoid deficiency can decrease free water clearance causing hyponatremia. Hypopituitarism can stimulate vasopressin secretion causing hyponatremia by inappropriate ADH secretion. (Shoji *et al.*, 1996; Anfusio *et al.*, 2009; Putterman *et al.*, 1991; Singhania *et al.*, 2010) Stress of an operation, severe infection, oral administration of excessive amount of

fluids without administration of an adequate dose of hydrocortisone can precipitate hyponatremia in patients with hypopituitarism. (Bethune and Nelson, 1965) The diagnosis of hypopituitarism in hyponatremic patients is often overlooked and it is a common electrolytic disorder, occurring in 33% to 69% of all cases with Sheehan's syndrome. (Kurtulmus *et al.*, 2006) Rarely there is development of overt diabetes insipidus, although subclinical vasopressin deficiency is common. (Atmaca *et al.*, 2007; Jialal *et al.*, 1987) As deficiency of pituitary hormone and their target hormones produces a constellation of symptoms, diagnosis of Sheehan's syndrome is often delayed. In the presence of lactation failure, prolonged amenorrhea and hypoglycemic crises the diagnosis can be made reliably. The diagnosis of Sheehan's syndrome can be done by laboratory analysis of pituitary hormones and their target hormones, and magnetic resonance imaging of brain which shows empty sella. In the absence of clinical and laboratory picture, an isolated empty sella is not suggestive of Sheehan's syndrome. Treatment involves hormone replacement therapy, including glucocorticoids, thyroid hormone, sex steroids, growth hormone, and vasopressin. T4 should not be administered until adrenal function, including ACTH reserve, has been evaluated and either found to be normal or treated. Treatment of the hypothyroidism alone may increase the clearance of the little cortisol that is produced, thereby increasing the severity of the cortisol deficiency.

### Conclusion

This case report shows the importance of taking detailed medical history, various hormone testing and pituitary imaging in the evaluation of hyponatremia. In a female presenting with recurrent hyponatremia or hypoglycemia, the importance of taking history of obstetric and postpartum events is emphasized. Once the diagnosis is confirmed, hormone replacement therapy will improve the outcome.

### REFERENCES

- Anfuso S, Patrelli TS, Soncini E, Chiodera P, Fadda GM, Nardelli GB. 2009. A case report of Sheehan's syndrome with acute onset, hyponatremia and severe anemia. *Acta Biomed.*, 80:73-6
- Atmaca H, Tanriverdi F, Gokce C, *et al.* 2007. Posterior pituitary function in Sheehan's syndrome. *Eur J Endocrinol.*, 156:563.
- Bethune JE, Nelson DH. 1965. Hyponatraemia in hypopituitarism. *N Engl J Med.*, 272: 771-6
- Boulanger E, Pagniez D, Roueff S. 1999. Sheehan syndrome presenting as early post-partum hyponatremia. *Nephrol Dial Transplant*, 14:2714-2715.
- De Groot LJ. 1989. Textbook of endocrinology. 2nd ed. Philadelphia: Saunders, p. 431-2.
- Jialal I, Desai RK, Rajput MC. 1987. An assessment of posterior pituitary function in patients with Sheehan's syndrome. *Clin Endocrinol (Oxf)*, 27:91.
- Kurtulmus N, Yarman S. 2006. Hyponatremia as the presenting manifestation of Sheehan's syndrome in elderly patients. *Aging Clin Exp Res.*, 18(6): 536-9.
- Putterman C, Almog Y, Caraco Y, Gross DJ, Ben-Chetrit E. 1991. Inappropriate secretion of antidiuretic hormone in Sheehan's syndrome: A rare cause of postpartum hyponatremia. *Am J Obstet Gynecol.*, 165:1330-3.
- Sheehan HL. 1937. Postpartum necrosis of the pituitary. *J Path Bacteriol.*, 45:189-214
- Shoji M, Kimura T, Ota K. 1996. Cortical laminar necrosis and central pontine myelinolysis in a patient with Sheehan syndrome and severe hyponatremia. *Intern Med.*, 35:427-31.
- Singhania P, Singh S, Banerjee R, Singhania B, Banerjee I, Maitra S. 2010. Hyponatremia – A rare and emergency presentation of Sheehan's Syndrome. *Pak J Med Sci.*, 26:713-5.

\*\*\*\*\*