



CASE STUDY

REHABILITATION OF A PATIENT WITH CUSTOM MADE OCULAR PROSTHESIS

^{1,*}Dr. Nitin Deora, ²Dr. Dimpy Kakkar, ³Dr. Shaveta Kaushal and ⁴Dr. Raghav Takkar

¹MDS, Reader, Department of Prosthodontics, GIDSR, Ferozpur, India

²MS Ophthalmology

³MDS, Senior Lecturere, Department of Prosthodontics, GIDSR, Ferozpur, India

⁴Post Graduate Student, Department of Prosthodontics, GIDSR, Ferozpur, India

ARTICLE INFO

Article History:

Received 15th July, 2016
Received in revised form
22nd August, 2016
Accepted 08th September, 2016
Published online 30th October, 2016

Key words:

Ocular defect,
Custom made ocular prosthesis, Eye.

Copyright © 2016, Nitin Deora. This is an open access article distributed under the Creative Commons Attribution License, which permits unrestricted use, distribution, and reproduction in any medium, provided the original work is properly cited.

Citation: Nitin Deora, 2016. "Rehabilitation of a patient with custom made ocular prosthesis", *International Journal of Current Research*, 8, (10), 39925-39928.

ABSTRACT

Loss of an eye is a traumatic event which has a crippling effect on the psychology of the patient. Several ocular disorders require surgical intervention that may result in the ocular defect. An ocular prosthesis is fabricated to restore the structural, functional and cosmetic defects created by such conditions. This case report presents the prosthetic management of the ocular defect with a custom made ocular prosthesis.

INTRODUCTION

The loss of eye has a crippling effect on the social and physical health of the patient. Various causes attributed to this are congenital defect, irreparable trauma, tumour, painful blind eye, sympathetic ophthalmia or the need for histological confirmation of a suspected diagnosis (Nafij *et al.*, 2013). Surgical procedures in the removal of an eye can be broadly classified as: Evisceration (where the contents of the globe are removed leaving the sclera intact), Enucleation (most common, where the entire eyeball is removed after severing the muscles and the optic nerve) and Exenteration (where the entire contents of the orbit including the eyelids and the surrounding tissues are removed) (Kaur *et al.*, 2010). An ocular prosthesis is a maxillofacial prosthesis that artificially replaces an eye missing as a result of trauma, surgery, or congenital absence. The prosthesis does not replace missing eye lids or adjacent skin, mucosa or muscle (The glossary of prosthodontic terms, 2005). Ocular prosthesis also does not provide vision, patient is blind on affected side and has monocular vision which affects depth perception (Somkuwar *et al.*, 2009).

Enucleation of the eye may be required for the following reasons:

- Cancer of the eye, such as retinoblastoma and uveal melanoma.
- Severe injury of the eye when the eye cannot be saved or attempts to save the eye have failed.
- End stage glaucoma.
- Painful, blind eye.
- In cases of sympathetic ophthalmia (inflammation of the eye) to prevent travel to other eye, which if untreated can cause blindness.
- Congenital cystic eye.
- In a deceased person, so the cornea can be used for a living person who needs a corneal transplant by a surgical operation called keratoplasty.
- Constant infection in a blind or otherwise useless eye.

An orbital implant is placed after removal of the eye to restore volume to the eye socket and enhance movement or motility of an ocular prosthesis and eyelids. A number of advantages are derived from this practice. If no material is used to fill the space of the orbit, it will exhibit a shrunken appearance as the size of a prosthetic eye is limited by the opening between the superior and inferior palpebral fissure.

*Corresponding author: Dr. Nitin Deora,

¹MDS, Reader, Department of Prosthodontics, GIDSR, Ferozpur, India.

Case Report

A 26 year old male patient (Fig.1) reported to the Department of Prosthodontics and Crown & Bridge with the chief complaint of missing right eye. Patient gave a history of penetrating injury causing ophthalmitis. Enucleation of the eye was done with simultaneous silicone implant placement. Patient was put on recall visits for check-up and review. The tissue bed was found healthy for the ocular prosthesis after two months. Patient was tried with preformed ocular prosthesis, but due to inadequate space a prefabricated ocular prosthesis could not be placed. Thus a customised prosthesis was the treatment of choice.

MATERIALS AND METHODS

1. Local anaesthetic eye drops were used to comfort the impression making.
2. Preliminary impression was made by injecting light body silicone impression material with the help of sterile disposable syringe.
3. The preliminary impression material was poured with dental stone and custom tray was fabricated using self cure PMMA. (Fig.2,3)
4. The custom tray was sandpapered and polished to avoid any injury to the ocular tissue.
5. A disposable syringe was used to inject light body silicone impression material with the custom tray in place for making the definitive impression. (Fig.4)
6. A wax pattern was fabricated on the master cast and try in was done.
7. The wax pattern was modified according to the available space and any over extensions caused by the pattern were checked and corrected. (Fig.5)
8. Wax pattern was invested and a heat cure PMMA shell was made. (Fig.6)
9. The definitive ocular shell was tried in patient. Digital reproduction of the iris with advanced photography and image correction software was done. Its position and size was determined and iris button was fixed to the ocular shell.
10. Customisation for the blood vessels was done and once desired esthetics were achieved, the shell was coated with thin layer of wax and invested.
11. Dewaxing was done and packing was done with clear heat cure PMMA.
12. The prosthesis was polished and final insertion was done. (Fig.7)
13. Post insertion instructions for removing & replacing the prosthesis and for cleaning the prosthesis were given. (Fig.8)

DISCUSSION

The sensory organs play a very significant role in one's life. The most tragic and most common loss of one of these sensory organs is that of eye (Shankar *et al.*, 2011). Eye is a vital organ as it is important component of vision and facial expression (Ram and Shah, 2013). Loss of eye is associated with physical and psychological trauma to the patient. Patient may experience stress due to facial disfigurement, societal reactions and adjusting to functional disabilities. Therefore, prosthesis is essential for the psychological upliftment and social acceptance of the patient. Making of an artificial eye has been practiced since ancient times. First ocular prosthesis was fabricated, as

early as 5th century BC, by Romans & Egyptian priests (Ragher *et al.*, 2014). Artificial eye prostheses were made from enamel, metal or painted clay etc. In 15th century, first in-socket eye was made using gold. Nowadays PMMA is being used to fabricate eye prosthesis as it gives life like appearance (Pauly *et al.*, 2011). Various types of ocular prostheses based on their fitting procedure include Stock shell, custom made ocular prosthesis and Sclera shell.

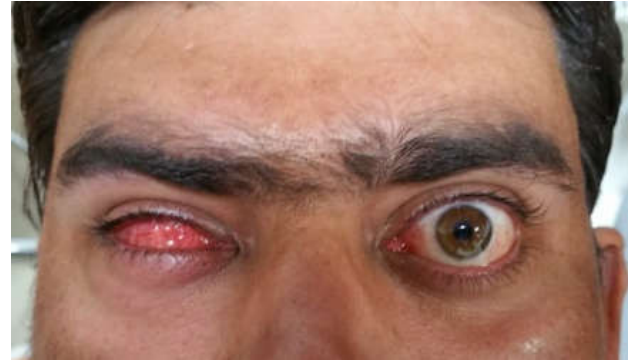

Fig.1. Patient with an ocular defect



Fig.2. Primary impression



Fig.3. Primary cast with the impression




Fig.4. Custom tray for definitive impression

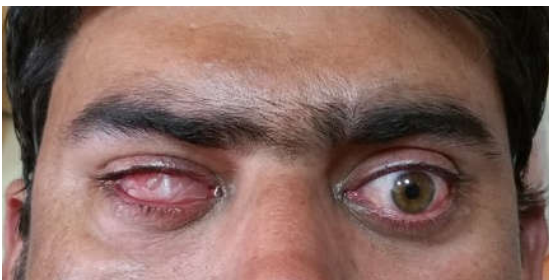

Fig. 5. Wax try-in

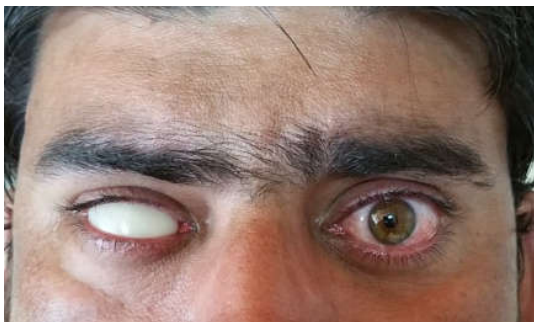

Fig. 6. Customised Ocular Shell Try-in

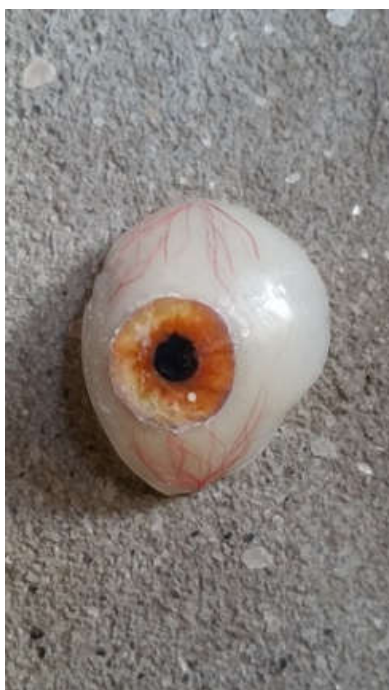

Fig. 7. Definitive Prosthesis

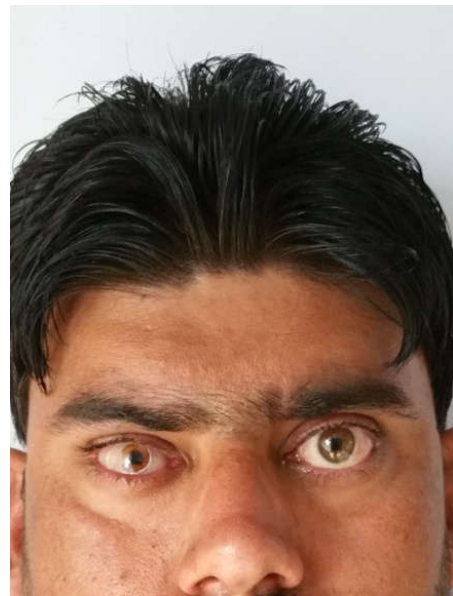

Fig. 8. Definitive Prosthesis in Place

Techniques to fabricate these prosthesis are ocular implants, empirically fitting the stock shell, modifying the stock eye by making an impression of the ocular defect or custom eye technique using PMMA. In this case, firstly stock eye was tried but it had poor fit, asymmetrical appearance, less motility and it caused irritation to the socket and led to redness. To overcome these disadvantages a custom made ocular prosthesis was fabricated. A custom made eye was fabricated according to patient's socket size, it fitted snugly and required modifications were also done easily. Patient was given eye drops initially to reduce any irritation to the surrounding tissues and called for regular follow up. There was close adaptation of the prosthesis with the tissue bed as it was supported by the silicone implant. There was digital reproduction of the iris with advanced photography and positioned over the ocular prosthesis using clear acrylic. A well made and properly planned ocular prosthesis maintains its orientation when patient performs various functional movements of the eye. Both artistic and high technical expertise is required for fabricating a prosthesis that appears to have a realistic appearance. The ideally constructed prosthesis must duplicate the missing feature so precisely that the casual observer notices nothing that the casual observer notices nothing that would draw attention to the prosthetic reconstruction. (Ahmad *et al.*, 2009)

Care for prosthesis (Chin *et al.*, 2015)

- Detailed history of the patient's wearing habits.
- Ensure comfortable fit with smooth edges.
- Proper contouring and polishing should be done.

REFERENCES

- Ahmad N, Bhandari AJ, Pai U, Gangadhar SA. 2009. Prosthetic management of a patient with ocular defect. *Parvata. Med. Rev.*, 1:32-34.
- Chin MC, Marques C, Danz HJ. Ocular prosthesis- Indications to management. *Canadian Journal of Optometry*, 77(2):24-32.
- Kaur A, Pavaiya A, Singh SV, Singh RD, Chand P. 2010. A simplified approach to fabrication of an ocular prosthesis: a case series. *Indian. J. Dent. Res.*, 21: 615-617.

- Nafij BJ, Theerathavaj S, Mohammad KA. 2013. A Complete Procedure of Ocular Prosthesis: A Case Report. *International Medical Journal*, 20:729 -730.
- Pauly M, Giridhar A, P. Varghese. 2011. Ocular Prosthesis. *Kerala Journal of Ophthalmology*, XXIII:338-341.
- Ragher M, Chatterjee A, Sanketsopanpatil, Chatterjee D, Mallikarjuna DM, Swetha V, Dandekeri S, Pradeep MR and Ashwinishetty. 2014. Ocular prosthesis- A Simplified Technique. *Austin. J. Clin. Case. Rep.*, 1:01-03.
- Ram HK. and Shah RJ. 2013. Simplified method for Ocular Rehabilitation: - A Case Report. *IOSR. Journal of Dental and Medical Sciences*, 4:10-13.
- Shankar R, Srinivas K, Singh M, Wangoo A. A New Procedure for the Fabrication of Custom Ocular Prosthesis.: 49-52.
- Somkuwar K, Mathai R, Jose P. 2009. Ocular Prosthesis: Patient rehabilitation- A case report. *People's Journal of Scientific Research*, 2:21-26.
- The glossary of prosthodontic terms. *J Prosthet Dent.*, 2005; 48-49.
