



## RESEARCH ARTICLE

### GELATINOUS TUMOUR OF MANDIBLE: A REPORT OF THREE CASES AND REVIEW

<sup>1</sup>Varsha, V. K., <sup>2</sup>Niranjan, K. C., <sup>2</sup>Amsavardini Tayyar, <sup>3</sup>Kumar, G. S. and <sup>2</sup>Hallikeri, K.

<sup>1</sup>Department of Oral and Maxillofacial Pathology, Rajarajeswari Dental College & Hospital, Mysore Road, Bangalore, Karnataka, India

<sup>2</sup>Department of Oral and Maxillofacial Pathology, SDM College of Dental Sciences and Hospital, Dharwad- 580 009, Karnataka, India

<sup>3</sup>Department of Oral and Maxillofacial Pathology, K.S.R Institute of Dental Sciences and Research, Tiruchengode, Tamil Nadu, India

#### ARTICLE INFO

##### Article History:

Received 23<sup>rd</sup> July, 2016  
Received in revised form  
30<sup>th</sup> August, 2016  
Accepted 18<sup>th</sup> September, 2016  
Published online 30<sup>th</sup> October, 2016

##### Key words:

Impacted premolar,  
Mandible,  
Odontogenic myxoma.

#### ABSTRACT

Odontogenic myxomas are benign neoplasm of uncertain histogenesis with a characteristic histologic appearance, often associated with locally aggressive & infiltrative fashion. Odontogenic myxomas represent 1% to 17.7% of all odontogenic tumors. Odontogenic myxoma commonly occurs in the second and third decade, and the mandible involved more commonly than the maxilla. They are believed to be derived from primitive mesenchymal portion of developing tooth germ as an inductive effect of nests of Odontogenic epithelium on mesenchymal tissue or as a direct myxomatous change of fibrous tissue. Characteristic histopathological feature are loosely arranged spindle cells to stellate cells with lightly eosinophilic cytoplasm in a mucoid rich, intercellular matrix. An occasional active odontogenic islands or inactive islands are found infrequently but probably represents residual rests rather than an integral part of neoplasm. Radiographically most of the multilocular myxomas are expansile & greater than 4 cms where as unilocular tend to be smaller in diameter & presents as fine, bony trabeculae within its interior structure expressing a 'tennis racket' appearance. Only 5% of myxomas are associated with unerupted tooth. Herein, we are presenting three case reports of odontogenic myxomas occurring in second decade of life in mandible.

Copyright © 2016, Varsha et al. This is an open access article distributed under the Creative Commons Attribution License, which permits unrestricted use, distribution, and reproduction in any medium, provided the original work is properly cited.

Citation: Varsha, V. K., Niranjan, K. C., Amsavardini Tayyar, Kumar, G. S. and Hallikeri, K. 2016. "Gelatinous tumour of mandible: A report of three Cases and Review", *International Journal of Current Research*, 8, (10), 40619-40625.

#### INTRODUCTION

Gelatinous tumours of jaw are usually related to the odontogenic myxomas (OM) and are termed so due to their mucoid or jelly like appearance on gross examination. The characteristic feature being that this jelly like material sticks to the instrument when touched. OM are rare non encapsulated, locally invasive benign tumour of jaw that infiltrate the marrow spaces. Myxoma of jaws were first illustrated by Thoma and Goldman in 1947 although Rudolph Virchow (1863) was probably the first to describe histological features of Myxoma. (Reichart and Philipsen, 2004) World health Organization in 2003 classified OM as benign neoplasm arising from odontogenic ectomesenchyme with or without odontogenic epithelium. (Pindborg and Karmer, 1971) They appear to be originating from the dental papilla, follicle or periodontal ligament. (Subramanaiah et al., 2015) OM commonly occurs

in the second and third decade, and the mandible more involved than the maxilla with a female predilection. (Manne et al., 2012) Clinically they often manifest as an asymptomatic swelling of jaws. Radiographic presentation of OM may vary from exclusively radiolucent to mixed or radio opaque lesion. (Subramanaiah et al., 2015) OM on gross reveal a mucoid/ gelatinous grayish white appearance with expansion of the cortical plates. Histologically they are characterized by stellate cells with branching process lying in an abundant mucopolysaccharide stroma. Odontogenic islands may or may not be present. (Reichart and Philipsen, 2004) Here we are presenting 3 case reports of OM occurring in second decade of life in mandible associated with an impacted premolar and we have also reviewed clinical, radiological presentation with histopathology of these unusual odontogenic tumours.

#### Case Report

One male and two female patients reported to SDM College and Hospital with a chief complaint of painless swelling in lower jaw with minimum of 3 months duration during the

\*Corresponding author: Niranjan, K. C.

Department of Oral and Maxillofacial Pathology, Rajarajeswari Dental College & Hospital, Mysore Road, Bangalore, Karnataka, India.

period of 2009-2012. Particulars of all the three cases of OM regarding age, gender, duration, site, symptoms, intra oral and radiographic details are compiled in Table I. All the three patients were in second decade with the mean age of 15.6 years (14 yrs- 17yrs). The duration of these tumours ranged from 3 months to 12 months. Two of our reported cases were from posterior mandible (Case 1 & 3) and one from anterior mandible. All the three cases presented as asymptomatic swelling with obliteration of vestibule (Figure 1), absence of 2<sup>nd</sup> premolar and malaligned teeth on the affected side of the mandible. Case 2 showed over retained 75. Radiographically all the three patients showed well defined radiolucency with corticated borders and expansion of cortical plates. (Figure 2) Two of the cases showed multilocular radiolucency among which one showed tennis racket appearance (Case 1) (Figure 3). Case 2 illustrated unilocular radiolucency (Figure 4).

All the three cases demonstrated impacted premolars and were displaced. On incisional biopsy a diagnosis of odontogenic myxoma was made and later the lesion was excised. Macroscopic examination of the excised specimens demonstrated white lesion with soft & gelatinous texture associated with impacted second premolar in all three cases. (Figure 5,6&7) Microscopic examination revealed an unencapsulated mass with cellular stroma comprising of spindle and stellate shaped tumour cells in a myxoid background (Figure 8 & 9). The myxomatous component closely resembled the mesenchymal portion of developing tooth. Case 2 and 3 exhibited odontogenic rests along with moderate amount of dense collagen fibers (Figure 10). Case 1 and 2 also revealed osteoid formation. Correlating the clinical, radiographic and microscopic findings diagnosis of odontogenic myxoma was confirmed.

**Table I. Clinical details of the present cases**

Case Details	Case 1	Case 2	Case 3
Age	16 years	14 year	17 year
Gender	Male	Female	Female
Site	43-46 region	33-36 region	44-46 region
Size	4x3 cms	3x3 cms	2x3cms
Duration	3 months	1 year	6 months
Symptom	Asymptomatic	Asymptomatic	Asymptomatic
Intra oral manifestation	Diffuse swelling extending from 43- 46 teeth region with obliteration of buccal vestibule.	Diffuse swelling extending from 33- 36 teeth region with obliteration of buccal vestibule.	Diffuse swelling extending from 44- 47 teeth region with obliteration of buccal vestibule
Radiographic features	Well defined & corticated border. Multilocular radiolucency with tennis racket appearance. Impacted 45 and displaced towards lower border of mandible.	Well defined corticated border. Unilocular radiolucency. Impacted 35 & root resorption w.r.t 33 & 34.	Well defined & corticated border. Multilocular radiolucency. Impacted 45 & displaced posteriorly.
Macroscopic features	White, soft & gelatinous	White, soft & gelatinous	White ,soft & gelatinous

**Table II. Summary of previous reported cases of Odontogenic Myxoma in last five years**

S.No.	Author	Age/Sex	Site	Duration	Radiographic features	Treatment	Recurrence
1	Altug et al. 2011	21/M	Maxilla	N.M	Unilocular radiolucency	N.M	N.M
2	Shah et al. 2011	37/F	Maxilla	N.M	Unilocular radiolucency	Partial en bloc excision	Absent
3	Kaymakci et al. 2011	9/F	Maxilla	N.M	Mixed *	Partial maxillectomy	Absent
4	Manne et al. 2012	19/M	Mandible	1 month	Multilocular radiolucency	Segmental resection	Absent
5	Singhal et al. 2013	19/F	Maxilla	1 year	Multilocular radiolucency	Total excision	Absent
6	Gupta et al. 2013	26/ F	Mandible	18 months	Multilocular radiolucency	N.M	N.M
7	Ghalayani et al. 2013	24/M	Maxilla	N.M	Unilocular radiolucency	Total excision	Absent
8	Rius 2013	55/M	Mandible	10 yrs	Unilocular radiolucency	Enucleation & Curratge	Absent
9	Deliverska et al. 2013	18/M	Mandible	N.M	Unilocular radiolucency	Peripheral ostectomy	Absent
10	Lahey et al. 2013	69/F	Mandible	2 weeks	Mixed *	Segmental resection	Absent
11	Jindwani et al. 2013	10/M	Maxilla	2 yrs	Radiolucent	Radical resection	Absent
12	Munjhal et al. 2013	40/F	Maxilla	2 months	Mixed*	Total excision	N.M
13	Sharma et al. 2013	18/M	Maxilla	5 months	N.M	Excision	N.M
14	Sarkar 2013	34/F	Maxilla	1 year	Unilocular radiolucency	Excision	Absent
15	Kennath et al. 2013	25/F	Maxilla	1 month	Multilocular radiolucency	Excision	Absent
16	Nguyen et al. 2014	24/F	Maxilla	N.M	Multilocular radiolucency	Extended radical Maxillectomy	Absent
17	Rani et al. 2014	55/M	Mandible	5 years	Multilocular radiolucency	Hemimandibulectomy	N.M
18	Ali et al. 2014	24/F	Maxilla	17months	Radiolucent	N.M	N.M
19	Dunphy et al. 2014	29/M	Maxilla	N.M	Radiolucent	Partial Maxillectomy	Absent
20	Kawase-Koga et al. 2014	40/M	Mandible	N.M	Multilocular radiolucency	Enucleation & Curratge	Absent
21	De souza et al. 2014	36/F	Mandible	N.M	Mixed *	Segmental mandibulectomy	Absent
22	Liu et al. 2014	37/M	Maxilla	5 yrs	Radiolucent	Right radical maxillectomy & left partial maxillectomy	Absent
23	Kumar et al. 2014	32/F	Mandible	2 yrs	Multilocular radiolucency	surgical resection	Absent
24	Guo 2014	14/M	Mandible	2 months	Irregular radiolucency	Partial en bloc excision	Absent
25	Manjunath et al. 2014	28/F	Maxilla	N.M	Unilocular radiolucency	Excision	N.M

Continue.....

26	Kiresur 2014	17/M	Maxilla	3 months	Multilocular radiolucency	Surgical Resection	N.M
27	Limidawala <i>et al.</i> 2015	36/M	Maxilla	1 year	Multilocular radiolucency	Total excision	Present
28	Limidawala <i>et al.</i> 2015	28/F	Maxilla	1.3 yrs	Mixed*	Total excision with surgical excision	N.M
29	Ayranci <i>et al.</i> 2015	33/M	Mandible	N.M	Unilocular radiolucency	Total excision	Absent
30	Saxena <i>et al.</i> 2015	18/M	Maxilla	N.M	Unilocular radiolucency	Total excision	Absent
31	Subramaiaam <i>et al.</i> 2015	18/M	Maxilla	4 yrs	Mixed*	Left Maxillectomy	Absent
32	Vijayabanu <i>et al.</i> 2015	65/M	Maxilla	6 months	Radio opaque lesion	Partial Maxillectomy	Absent
33	Khan <i>et al.</i> 2015	52/F	Maxilla	3 years	Mixed*	Surgical excision & Curettage	Absent
34	Dabbaghi <i>et al.</i> 2016	27/F	Mandible	3 years	Mixed *	Block resection	Absent
35	Aditya <i>et al.</i> 2016	43/M	Mandible	2 yrs	Multilocular radiolucency	N.M	N.M
36	Hammad <i>et al.</i> 2016	45/F	Mandible	N.M	Multilocular radiolucency	Enucleation, curettage & peripheral ostectomy	Absent
37	Murphyet <i>et al.</i> 2016	13/M	Maxilla	6 months	Mixed *	Partial Maxillectomy	Absent
38	Contrera Toro <i>et al.</i> 2016	2.5/M	Maxilla	2weeks	Unilocular radiolucency	Peripheral Bone Osteotomies	Absent
39	Bravo-Burguillos <i>et al.</i> 2016	21months/M	Maxilla	N.M	Unilocular radiolucency	Enucleation & curettage	Absent

Table 3. Radiologic classification of Odontogenic Myxoma by Zhang et al

Type	Radiographic Pattern
Type I	Unilocular radiolucency
Type II	Multilocular radiolucency
Type III	Lesion involving the alveolar bone
Type IV	Lesion involving the maxillary sinus
Type V	Osteolytic destruction
Type VI	Mixed areas of osteolytic destruction and osteogenesis

Table 4. Correlation between radiographic pattern and septa by Noffke et al

Pattern	Rationale
Soap bubble appearance	Large spaces surrounded by round or curved bony septae
Honey comb Appearance	Small angular spaces resembling a bee's honey comb
Tennis Racket Appearance	Crossed straight septa resembling the strings of a tennis racket
Ground glass Appearance	Visual effect of many fine, poorly calcified trabeculations superimposed on each other and arranged in disorganized fashion.

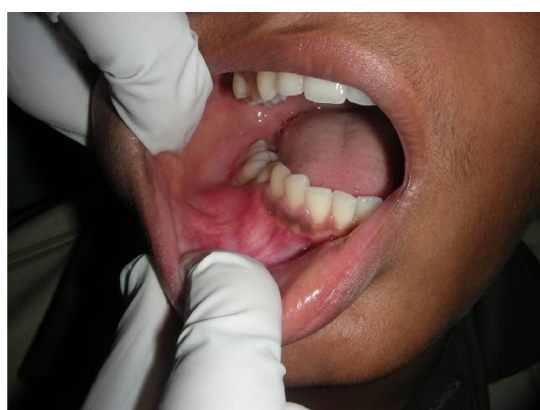

Figure 1. Intraoral swelling with obliteration of vestibule i.r.t 43-46 region in case 1

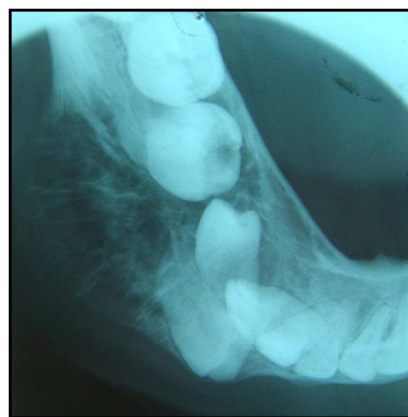

Figure 2. Occlusal radiograph revealed multilocular radiolucency with cortical expansion & tooth displacement in case 3

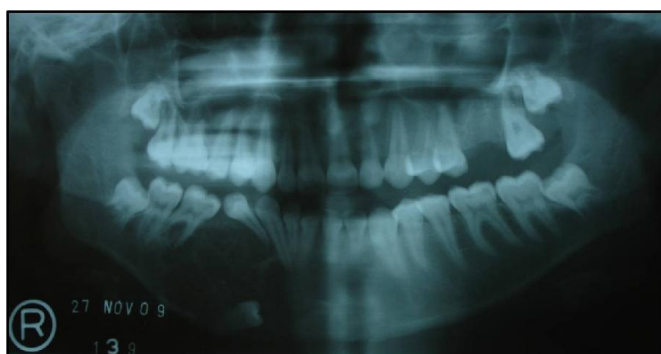

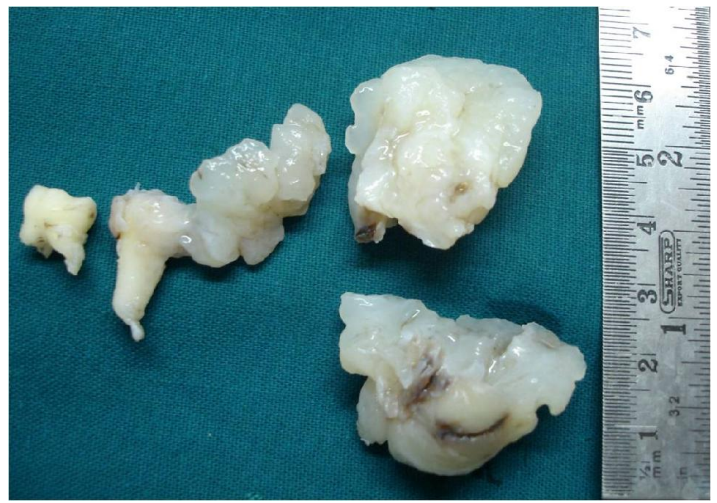
Figure 3. OPG revealed Multilocular radiolucency with TENNIS RACKET appearance and impacted 45 in case 1

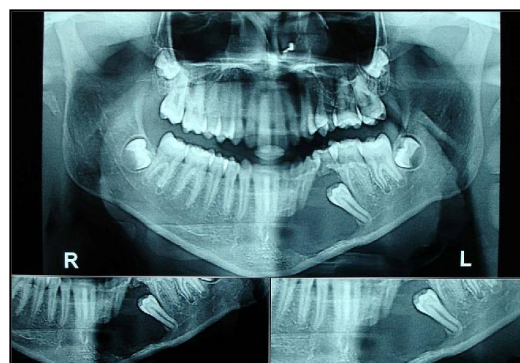
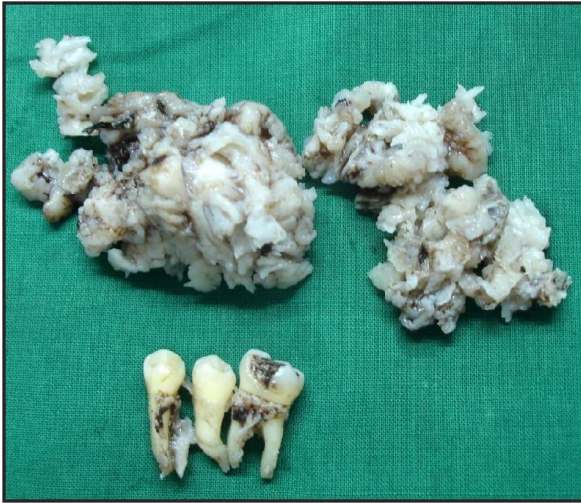
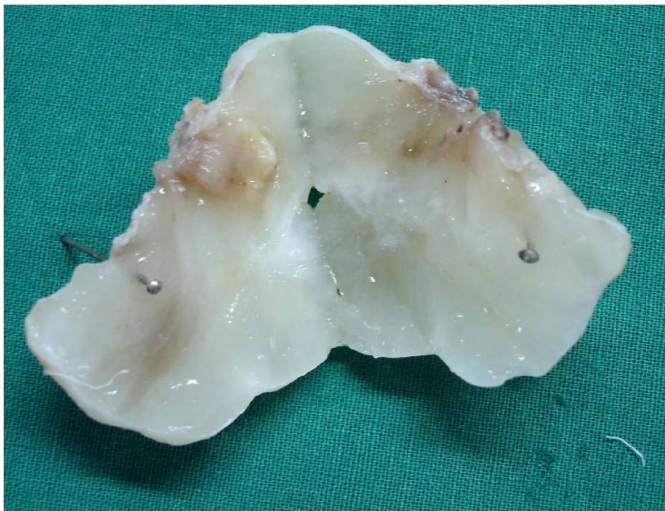Figure 4. OPG revealed unilocular radiolucency with impacted 35 in case 2



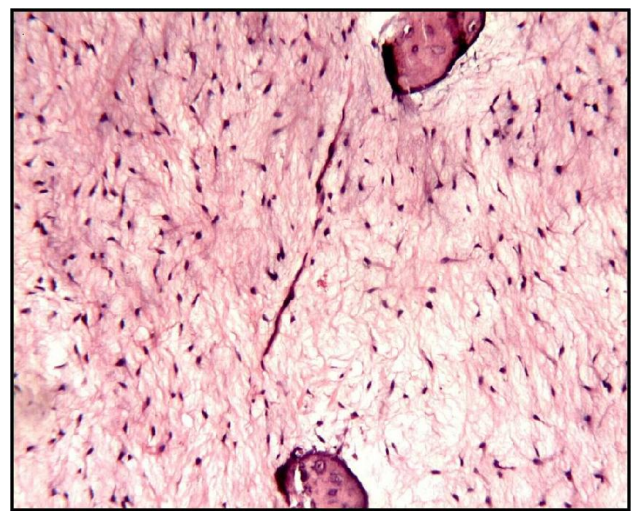
**Figure 5. Gross specimen showing greyish white gelatinous tumour mass showing irregular surface with 44, 45 & 46 in case 1**



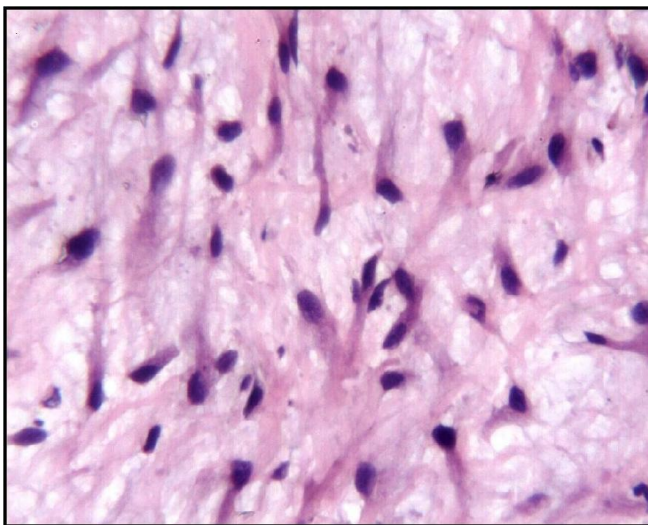
**Figure 6. Gross specimen showing Creamish white gelatinous mass with 35 and 75 in case 2**



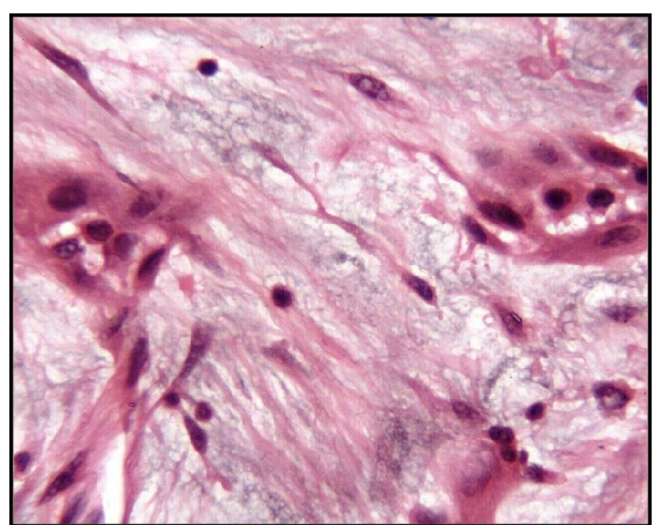
**Figure 7. Gross specimen showing Creamish white gelatinous mass in case 3**



**Figure 8. Photomicrograph showing stellate and spindle shaped cells with residual bone in myxomatous background (H&E stain 100x magnification)**



**Figure 9. Photomicrograph showing stellate and spindle shaped cells with thin interconnected cellular projection amidst a hypercellular background. (H&E stain 400 x magnification)**



**Figure 10. Photomicrograph showing myxomatous connective tissue with inactive odontogenic epithelial rests. (H&E stain 400 x magnification)**

## DISCUSSION

Myxomas are derived from Greek word 'muxa' for mucus. They are myxoid tumors of primitive connective tissue as stated in Dorland's medical dictionary. They are benign mesenchymal tumors that occur rarely in the head and neck. When they do occur, they are prevalent in the jaws and occur less frequently in the subcutaneous tissues. (Canalis *et al.*, 1976) Based on the tissue derived from, head and neck myxomas are classified into facial bone derived and soft tissue derived. In the late 70's Regezi *et al* subdivided facial myxomas into true osteogenic myxoma and odontogenic myxoma. (Regezi *et al.*, 1978) Guo *et al* subdivided myxomas of maxillofacial area based on the location into central, peripheral and soft tissue myxomas. (Guo *et al.*, 2014) To best of our knowledge after reviewing the literature of past 5 years (2011-2016) approximately about 39 cases have been reported. (Table II) OM are infrequent benign, site aggressive, locally infiltrative tumours discerned as a slowly expanding swelling or asymmetry of the affected jaw associated with odontogenesis comprising a debatable histogenesis. Dental papilla, dental follicle and root forming apparatus are thought to give rise to OM. (Reichart and Philipsen, 2004) To substantiate OM odontogenic origin following factors have been put forth. i) Constrained occurrence in association with jaws and tooth bearing area ii) Association with missing/unerupted tooth in younger age & iii) similitude to tooth mesenchyme and presence of odontogenic islands. (Martínez-Mata *et al.*, 2008) Few authors doubt its true odontogenic origin based on ultrastructural, immunohistochemical and biochemical studies in recent years. Studies have suggested other origin for OM's such as myofibroblastic, dual fibroblastic/histiocytic origin. (Reichart and Philipsen, 2004) Others suggest dissimilarity in the extracellular matrix of dental soft tissue and OM. (Halfpenny *et al.*, 2000) Various authors considered that there is a significant difference in the Glycosaminoglycans of OM and dental pulp. (Martínez-Mata *et al.*, 2008) OM represent 3-6% of all odontogenic tumours. Its frequency range between 0.5%- 17.7% of odontogenic tumours in Asia, Europe and America. On literature review showed that OM generally occur in 2<sup>nd</sup> and 4<sup>th</sup> decade of life with female predilection. They are rarely seen below 10 yrs and above 50 yrs of age group. (Noffke *et al.*, 2007) On literature review studies on most common age group have shown discrepancies. Oldest patient observed in our review was in a 69 year old male and youngest being 21 month old male reported by Lahey *et al* and Bravo-Burguillos *et al* respectively. (Lahey *et al.*, 2013; Bravo –Burguillos *et al.*, 2016) Out of 39 cases reviewed 22 were in male. These tumours are not restricted to any particular region of jaws but mandible more frequently affected than maxilla (3:1). (Kumar *et al.*, 2014) In our review we observed that cases reported in maxilla (29) was more than in mandible. We believed that cases in maxilla were reported more due to its rarity in maxilla. Two out of three cases reported here were in female and all three cases presented in 2<sup>nd</sup> decade (14-17 yrs) in the mandibular premolar –molar region which is in conformity with the typical demography. The duration of this lesion in our review ranged from 2 weeks to 5 years. Clinically most of the OM patients present as asymptomatic slow growing expansile lesion, associated with missing or impacted tooth occasionally. Based on the region it expands into Sally Nguyen *et al* classified symptoms into i) palate and oral cavity ii) maxillary sinus and nasal cavity and iii) Orbit. Expansile mass occurring in oral cavity and palate may be associated with facial asymmetry, trismus, dysphagia, dysphonia, malocclusion

and displacement or mobility of teeth. Nerve involvement lead to paraesthesia (Nguyen *et al.*, 2014) and ulceration of overlying mucosa occurs when lesion interferes with occlusion. (Kiresur and Sathyavanthan, 2014) Symptoms associated with lesions of maxillary sinus and nasal cavity were sinusitis, sinus/paranasal pain, nasal obstruction, nasal discharge and recurrent epistaxis. Lesion expanding into orbit presented with symptoms of exophthalmoses and diplopia. (Nguyen *et al.*, 2014) Mandibular lesions show expansion of cortical plates Maxillary lesions were more aggressive than those seen in mandible as they infiltrate into sinus and adjacent structures. (Reichart and Philipsen, 2004) Radiologically OM's widely vary from lesions being purely radiolucent to mixed lesion to complete radio opaque. Our review also demonstrated the same. Zhang *et al.* (2007) reviewed 41 cases and alienated the radiographic features into 6 types. Table III

Noffke *et al.* (2007) described multilocularity based on degree of classification and type of septa. Based on the patterns created by the septa multilocular lesions were described as in Table IV He demonstrated significant correlation between the locularity and lesional size wherein multilocular lesions were larger in size. In accordance with the literature all three cases reported here were asymptomatic, slow growing lesions associated with impacted and displaced premolar presenting unilocular radiolucency in case 2 and multilocular radiolucency (case 3) with tennis racket appearance in case 1. Histopathologically OM comprises mainly of two components-cellular and myxoid matrix. Cellular components include spindle to stellate cells which have anatomising long tapering cytoplasmic processes. But round ellipsoid & triangular cells may also be present with intense cytoplasmic eosinophilia. Nuclei are usually small inconspicuous & hyperchromatic. Mitotic activity may be present but are usually scarce. Less amount of odontogenic epithelium are present in minority of cases but are not a prerequisite for diagnosis. (Reichart and Philipsen, 2004) The Myxoid component comprises alciphilic ground substance which is primarily hyaluronic acid 80% & chondroitin sulphate (20%). (Subramaniam *et al.*, 2015) Histopathological features of our cases were similar to the histopathological features of OM as reported in literature and this hyaluronic acid was well appreciated in all our cases by (combination of Alcian blue & PAS) special stains. In view of the fact that nature of OM has been controversial from the day of its original description, these are considered as aggressive in spite of being slow growing tumours for which various rationales have been attributed. Several studies have been carried out to perceive the contribution of cellular and matrix components in determining the aggressive nature of OM's. Moshri *et al.* suggested that in OM's cells are heterogeneous comprising of actively secreting fibroblast and significant number of myofibroblast. (Moshiri *et al.*, 1992) Martínez-Mata *et al.* also reported the presence of Myofibroblast. (Martínez-Mata *et al.*, 2008) Vered *et al* have suggested that myofibroblast play role in synthesis and reorganization of extra cellular matrix and besides that its role in aggressiveness of odontogenic tumours has been proved. (Vered *et al.*, 2005) Bast *et al* put forward that dysregulation of antiapoptotic mechanism contribute to aggressiveness of OM's. (Bast *et al.*, 2003) Moreira *et al* suggested that hypermethylation of proapoptotic genes p27, P53 and Rb1 downregulate protein expression and contribute to myxoma growth. (Moreira *et al.*, 2011) Slootweg *et al.* proposed that increase in tumor size was related to ECM production due to the extreme water-binding capacity of the GAG-matrix. (Slootweg *et al.*, 1985) Hodson &

Prout suggested that this large content of hyaluronic acid also played a significant role in the neoplastic behaviour of OM's. (Prout and Hodson, 1968) Miyagi *et al* in his study denoted that Matrix metalloproteinase 9 facilitate the invasion of the tumour cells through normal tissues thus participate in an imperative role in invasion. (Miyagi *et al.*, 2012) Bologna-Molina *et al* conducted a study to examine the expression of VEGF-A (vascular endothelial growth factor) and Orosomucoid -1 (ORM-1) and their potential role in biological behaviour of OM. He suggested that VEGF and ORM-1 play a role in angiogenesis and tumour structural viscosity respectively influencing the growth of tumour. (Bologna-Molina *et al.*, 2015) Recently Gonzalez-Galvan attempted to correlate the angiogenesis with growth and behaviour of OM's where in they concluded that neoangiogenesis has a limited role to play in the growth and behavior of these neoplasms. (Del Carmen González-Galván *et al.*, 2016)

### Treatment

The various treatment modalities followed are curettage with peripheral ostectomy, enucleation, local excision, segmental or total jaw resection and radical resections. (Manjunath *et al.*, 2014) Conservative treatment such as enucleation and curettage are done on smaller lesions measuring less than 3cms, whereas segmental resections with immediate reconstructions are carried out when lesions are larger. (Murphy *et al.*, 2016) Whatever may be the treatment modality followed ultimately our aim should be to prevent recurrence as OM are gelatinous in nature and lack fibrous capsule and infiltrative growth pattern. (Saxena *et al.*, 2015) The recurrence rates array from 10% to 33%, average being 25 %. (Kiresur and Sathyavanthan, 2014) Recurrence can be minimized with extensive partial or total resection procedures as the lesions are not radiosensitive. (Manjunath *et al.*, 2014; Kiresur and Sathyavanthan, 2014; Limdiwala and Shah, 2015) In spite of following stringent treatment protocol complete surgical removal of maxillary lesions are near to impossible. This may be attributed to non encapsulation, infiltration of the myxomatous lesional tissue into the cancellous maxillary bone along with their close association with adjacent vital structures. (Kiresur and Sathyavanthan, 2014) In our review Limdiwala *et al.* (Kiresur and Sathyavanthan, 2014) presented a case of myxoma with recurrence in which he stated that the probable reason for recurrence could be incomplete removal of the lesion during the first surgery. Ten of the cases reported did not state about recurrence as the patients were lost for follow up and rest of the cases did not report any recurrence.

### Conclusion

OM is benign aggressive non metastasizing odontogenic tumour with conflicting histogenesis. According to literature it is hard to estimate the incidence of OM cases since they present clinically as asymptomatic and slow growing tumours to locally aggressive. Moreover patients refer to the clinician only after it gets symptomatic and for esthetic/functional quandary. The nature of OM has been controversial. Myofibroblast and hyaluronic acids do have a role in behavior of OM's. Further investigations are required for better understanding of local aggressiveness.

### REFERENCES

Aditya A, Khandelwal P, Joshi S, Trimbake S, Dighe R. 2016. Odontogenic Myxoma of Mandible: Report of A Rare Case. *J Clin Diagn Res.*, February; 10(2): ZJ01-ZJ02.

- Ali S, Bansal P, Bhargava D, Kunal V. 2014. Odontogenic myxoma of the maxilla infiltrating the maxillary sinus :A rare case report. *IOSR-JDMS*, 13(11):89-93
- Altug HA, Gulses A, Sencimen M. 2011. Clinico-radiographic examination of odontogenic myxoma with displacement of unerupted upper third molar: Review of the literature. *Int.J.Morphol.*, 29(3):930-933
- Ayrancı F, Ömezli MM, Rastgeldi OZ, Duman A. 2015. Odontogenic Myxoma Located in The Mandible: A Case Report, 1(3):25-28
- Bast BT, Pogrel MA, Regezi JA. 2003. The expression of apoptotic proteins and matrix metalloproteinases in odontogenic myxoma. *Oral Maxillofac Surg.*, 61:1463-6
- Bologna-Molina R, Mosqueda-Taylor A, Domínguez-Malagón H, Salazar-Rodríguez S, Tapia G, Gonzalez-Gonzalez R *et al.* 2015. Immunolocalization of VEGF-A and orosomucoid-1 in odontogenic myxoma. *Rom J Morphol Embryol.*, 56(2):465-73.
- Bravo -Burguillos ER, Pozo Kreilinger JJ, Munoz Garo JM, Parra AR. 2016. Infant Odontogenic Myxoma : case Report and Literature review of a specific entity described. *Arch Otolaryngol Rhinol.*, 2(1): 6-9.
- Canalis RF, Smith GA, Konrad HR. 1976. Myxomas of the head and neck. *Arch Otolaryngol.*, May; 102(5):300-5.
- Contrera Toro MD, Siqueira Barreto I, Ingrid Amstalden EM, Chone CT, Nizam feilsticke L. 2016. Odontogenic Myxoma in Children: A Case Report and Literature Review. *Case Rep Oncol Med.*, 2016: 1-6
- Dabbaghi A, Nikkerdar N, Bayati S, Golshah A. 2016. Rare appearance of an odontogenic myxoma in cone-beam computed tomography: a case report. *J Dent Res Dent Clin Dent Prospects*, 10(1): 65-68
- De Souza J. G. O., Claus J. D. P., Ouriques, F. D. 2014. Treatment of Odontogenic Myxoma: A Multidisciplinary Approach 6-Year Follow-Up Case. *Case Rep Dent*, 2014:1-9
- Del Carmen González-Galván M, Aguirre-Urizar JM, Bologna-Molina R, Farfán-Morales JE, Gainza-Cirauqui ML, Marichalar-Mendia X, Mosqueda-Taylor A. 2016. Assessment of CD-105 as an Angiogenic Modulator in Odontogenic Myxomas and Dental Follicles. *Int J Surg Pathol.*, 1-6.
- Deliverska EG. 2013. Odontogenic myxoma - A rare case and diagnostic and therapeutic challenges. *J of IMAB*, 19(4):404-406.
- Dunphy L, Shah S, Halsnad M, Amel-Kashipaz R, Praveen P. 2015. Odontogenic myxoma presenting as a spontaneous oro-nasal fistula: A case report, 8(3); 167-170,
- Ghalayani, P., GR Jahanshahi, HR Mohagheghiyan. 2013. Odontogenic Myxoma of Maxilla in an Atypical Location: A Case Report. *J Dent (Shiraz)*, March; 14(1): 41-45
- Guo Y-J, Gao Y, Ma X-C. 2014. An Unusual odontogenic myxoma in mandible and submandibular region: a rare case report. *Dentomaxillofac Radiol.*, 43:1-6.
- Gupta S, Grover N, Kadam A, Gupta S, Sah K, JD Sunitha, 2013. Odontogenic myxoma. *Natl J Maxillofac Surg.*, Jan-Jun; 4(1): 81-83
- Halfpenny W, Verey A, Bardsley V. 2000. Myxoma of the mandibular condyle. A case report and review of the literature. *Oral Surg Oral Med Oral Pathol Oral Radiol Endod.*, Sep; 90(3):348-53
- Hammad HM, Hasen YM, Odat AA, Mikdadi AM, Safadi RA. 2016. Odontogenic myxoma with diffuse calcifications: a case report and review of a rare histologic feature. *Oral Surg Oral Med Oral Pathol Oral Radiol.*, e1-e9.

- Jindwani K, Nevaskar V, Agrawal D. 2013. Odontogenic Myxoma of Maxilla: Management and Follow-up of A Rare Case. *Indian Journal of Clinical Practice*, 24(2):130-137.
- Kawase-Koga Y, Saijo H, Hoshi K, Takato T, Mori Y. 2014. Surgical management of odontogenic myxoma: a case report and review of the literature. *BMC Res Notes*, Apr 5; 7:214
- Khan SF, Agarwal P, Sur J. 2015. A rare case report of Myxoid fibroma of maxilla. *Quant Imaging Med Sur.*, 5(5): 778-782.
- Kiresur MA, Sathyavanthan H. 2014. An aggressive odontogenic myxoma of the maxilla. *Indian J Dent*, Oct-Dec; 5(4): 214-217
- Kumar N, Kohli M, Pandey S, Agarwal P. 2014. Odontogenic Myxoma. *J Maxillofac Oral Surg.*, June; 13(2): 222-226
- Lahey E, Woo S, Park H. 2013. Odontogenic Myxoma with Diffuse Calcifications: A Case Report and Review of the Literature. *Head Neck Pathol.*, March; 7(1): 97-102
- Limdiwala P, Shah J. 2015. Odontogenic myxoma of maxilla: A review discussion with two case reports. *Contemp Clin Dent*, Jan-Mar;6(1):131-6
- Manjunath S, Gupta A, Swetha P, Moon Nj, Singh S, A. 2014. Report. *Ann Med Health Sci Res.*, Mar-Apr; 4(Suppl 1): S45-S48
- Manne RK, Kumar VS, Sarath PV, Anumula L, Mundlapudi S, Tanikonda R. 2012. Odontogenic Myxoma of the Mandible. *Case reports in Dentistry*, 1-4.
- Martínez-Mata G, Mosqueda-Taylor A, Carlos-Bregni R, de Almeida OP, Contreras-Vidaurre E, Vargas PA, Cano-Valdéz AM, Domínguez-Malagón H. 2008. Odontogenic myxoma: clinico-pathological, immunohistochemical and ultrastructural findings of a multicentric series. *Oral Oncol.*, Jun;44(6):601-7
- Miyagi SP, Maranduba CM, Silva Fde S, Marques MM. 2012. Dental Pulp stem cells express proteins involved in the local invasiveness of odontogenic myxoma. *Braz Oral Res.*, 26:139-144
- Moreira PR, Cardoso FP, Brito JA, Batista AC, Gomes CC, Gomez RS. 2011. Hypomethylation of tumour suppressor genes in odontogenic myxoma. *Braz Dent J.*, 22:422-427
- Moshiri S, Oda D, Worthington P, Myal IR. 1992. Odontogenic myxoma: Histochemical and Ultrastructural study. *J Oral Pathol Med.*, 2:401-403.
- Munjal M, Bhardwaj V, Garg B, Sood N. 2013. Odontogenic myxoma of the maxilla: a clinical case report and review of literature. *Online J Otolaryngol.*, 3(2): 51-60.
- Murphy C, Hayes R, McDermott M, Kearns GJ. 2016. Odontogenic myxoma of the maxilla: surgical management and case report. *Ir J Med Sci.*, 14:1-4
- Mustafa Kaymakci, Selçuk Yazici 2011. Odontogenic myxoma of the maxilla. *Clin Pract.*, September 28; 1(4): e136.
- Nguyen S, Charbonneau S, Ghannoum JE, Bissada E. 2014. Extensive Odontogenic Myxoma of the Maxilla: A case report and review of literature. *International Journal of Otolaryngology and Head & Neck Surgery*, 3:364-370
- Noffke CE, Raubenheimer EJ, Chabikuli NJ, Bouckaert MM. 2007. Odontogenic myxoma: review of the literature and report of 30 cases from South Africa. *Oral Surg Oral Med Oral Pathol Oral Radiol Endod.*, Jul;104(1):101-9
- Pindborg JJ. and Kärner IRH. 1971. Histological typing of Odontogenic tumours. *Jaw Cysts and Allied lesions*. International Histological classification of Tumours, No 5, World Health Organisation: Geneva.
- Prout R.E.S, Hodson JJ. 1968. Analysis of the Mucopolysaccharide of a Myxoma of the Mandible. *Nature*, 218, 99 – 100.
- Rani V, Mahaboob Kadar MK, Babu A, Sankari L, Krishnasamy G. 2014. Odontogenic myxoma diagnostic dilemma: A case report and review of literature. *J Cranio Max Dis.*, 3:163-167
- Regezi JA, Kerr DA, Courtney RM. 1978. Odontogenic tumors: Analysis of 706 cases. *J Oral Surg.*, 36:771-8.
- Reichart PA. and Philipsen H.P. 2004. Odontogenic tumours and Allied Lesions, Quintessence Publishers. London, UK. pp 189-197.
- Rius JM, Nadal A, Lahor E, Mtui B, Brunet L. 2013. Unusual presentation of localized gingival enlargement associated with a slow growing odontogenic myxoma. *Int J Oral Sci.*, September; 5(3): 172-175.
- Sarkar RR. 2013. Oncologic profile of maxillary odontogenic myxoma: A rare case. *Contemp Clin Dent*, Jul-Sep; 4(3): 374-377.
- Saxena R, Astekar M, Panat SR, Sapra G, Agarwal A, Agarwal A. 2015. Odontogenic Myxoma of the Maxilla: A Case Report with Review of Literature. *J Dent Sci Oral Rehab.*, 6(3):148-150
- Shah A, Lone P, Latoo S, Ahmed I, Malik A, Hassan S et al. 2011. Odontogenic myxoma of the maxilla: A report of a rare case and review on histogenetic and diagnostic concepts. *Natl J Maxillofac Surg.*, Jul-Dec; 2(2): 189-195
- Sharma N, Prashant D, Sharma S, Prashant V. International Journal of Oral & Maxillofacial Pathology; 2013;4(1):85-89
- Singhal R, Singh A, Rastogi P, Dixit J. 2012. Odontogenic myxoma presenting as localized inflammatory gingival enlargement: A diagnostic dilemma. *J Indian Soc Periodontol.*, Jul-Sep; 16(3): 461-464
- Slotweg PJ, Van der Bos T, Strak W. 1985. Glycosaminoglycans in myxoma of the jaw: A biochemical study. *J Oral Pathol.*, 14:299-306
- Sri Kennath J. Arul, Verma S, A. Sri Sennath J. Arul, Verma R. 2013. Infiltrative odontogenic myxoma of the posterior maxilla: Report of a case. *J Nat Sci Biol Med.*, Jul-Dec; 4(2): 484-487.
- Subramaniam R, Narashiman S, Narashiman M, Giri V, Kumar S. 2015. Odontogenic Myxoma of the Maxilla-A rare case Report. *Journal of Clinical and Diagnostic Research*, 9(5):ZD29-ZD31.
- Vered M, Shohat I, Buchner A, Dayan D. 2005. Myofibroblasts in stroma of odontogenic cysts and tumours can contribute to variation in the biological behaviour of lesions. *Oral Oncol.*, Nov;41(10):1028-1033.
- Vijayabanu B., C. Sreeja, N. Bharath, I. Aesha, V. Sadesh Kannan, M. Devi. 2015. Odontogenic myxoma of maxilla: A rare presentation in an elderly female. *J Pharm Bioallied Sci.*, August; 7(Suppl 2): S759-S762.
- Ying Liu, Bo Han, Tao Yu, Longjiang Li. 2014. A large odontogenic myxoma of the bilateral maxillae: A case report. *Oncol Lett*, September; 8(3): 1328-1332
- Zhang, H Wang, X He. 2007. Radiographic examination of 41 cases of Odontogenic myxomas on the basis of conventional radiographs. *Dentomaxillofacial Radiology.*, 36:160-167