



## RESEARCH ARTICLE

### A NEW TREATMENT METHOD FOR DIAPER DERMATITIS: IODINE IMPREGNATED INCISE DRAPE

\*<sup>1</sup>Mesut Sipahi, <sup>2</sup>Ghaniya Ede, <sup>3</sup>Emine Çölgeçen, <sup>4</sup>Çiğdem Kader and <sup>2</sup>Ümmügülsüm Aliye Geçit

<sup>1</sup>Bozok University School of Medicine, Department of General Surgery, Yozgat, Turkey

<sup>2</sup>Bozok University School of Medicine, Department of Pediatrics, Yozgat, Turkey

<sup>3</sup>Bozok University School of Medicine, Department of Dermatology, Yozgat, Turkey

<sup>4</sup>Bozok University School of Medicine, Department of Infectious Disease, Yozgat, Turkey

#### ARTICLE INFO

##### Article History:

Received 17<sup>th</sup> August, 2016

Received in revised form

19<sup>th</sup> September, 2016

Accepted 25<sup>th</sup> October, 2016

Published online 30<sup>th</sup> November, 2016

##### Key words:

Diaper dermatitis,  
Incise Drape,  
Irritant dermatitis.

#### ABSTRACT

**Objectives:** Diaper dermatitis is a prevalent disease all over the world, regardless of social and economic conditions. In some cases, it can lead to troublesome situation for parents and babies. Conventional treatment is applied successfully. In surgery, Povidone-iodine impregnated drape is used to reduce the surgical wound infection due to it has broad antifungal and antibacterial properties. Additionally, it has barrier properties in the mechanical trauma during cleaning and irritation of the urinary and stool. In our study, we investigated effects of povidone-iodine impregnated drape on diaper dermatitis.

**Materials and Methods:** Patient's diaper dermatitis scores were determined. Considering the treatment options of family, patients were randomly divided into two groups as conventional treatment and study group. In the study group, povidone-iodine impregnated drape was pasted on diaper area. Dermatitis scores were evaluated again on post-treatment day 1 and day 3.

**Results:** There was no significant difference on 3<sup>rd</sup> day healing levels and dermatitis scores between control and study groups. It was observed that both treatment methods were effective in the diaper dermatitis. On first day, there was more healing in the group of applied povidone-iodine impregnated drape than classical treatment group ( $p < 0.01$ ).

**Conclusion:** Application of povidone-iodine impregnated drape on diaper region was more fast effective than classical treatment. It can be an effective treatment choice in diaper dermatitis.

Copyright©2016, Mesut Sipahi et al. This is an open access article distributed under the Creative Commons Attribution License, which permits unrestricted use, distribution, and reproduction in any medium, provided the original work is properly cited.

**Citation:** Mesut Sipahi, Ghaniya Ede, Emine Çölgeçen, Çiğdem Kader and Ümmügülsüm Aliye Geçit, 2016. "A new treatment method for diaper dermatitis: Iodine impregnated incise drape", *International Journal of Current Research*, 8, (11), 42320-42323.

## INTRODUCTION

Diaper (napkin) dermatitis (DD) which is the irritant contact dermatitis of the diaper site is a commonly seen dermatologic problem in infants and children worldwide (Jordan *et al.*, 1986). Although it can be encountered in any age, DD is the most commonly observed in infants aged between 9 and 12 months (Serdaroğlu and Üstünbaş, 2010). The best criterion for the diagnosis is localization of lesions. Lesions in DD are localized in the genital, buttocks, thigh and lower abdominal regions (Boiko, 1999). Ammoniac which is formed as a result of the bacterial degradation of urea in the urine is accused form the etiology. Elevation of pH in the diaper site which is caused by ammoniac activates the inactive enzymes that are found in the stool. The activated proteases and lipases are highly irritant for the skin (Shin, 2005). In addition, shortening of the bowel transit time in case of diarrhea and failure to inactivate feces enzymes, friction, wetness, improper skin care and the use of

broad spectrum antibiotics decrease defence of the skin, preparing the ground for bacterial infection (Tüzün *et al.*, 2015). Although currently used antibacterial, antiinflammatory, creams, powders and cream barriers can largely treat irritant diaper contact dermatitis successfully, the treatment of irritant diaper contact dermatitis may take a long time. Iodophor-impregnated adhesive drapes are a material used by adhesion on the skin to reduce infection risk of surgical site preoperation. These drapes prevent maceration of the skin owing to the breathable film on them and constitutes a mechanical layer between the skin and the external environment. The drapes have bactericidal effects owing to iodine they contain and impede bacteria to reach wound site by inhibiting their movement with adhesion on the skin (Yoshimura *et al.*, 2003). The objective of this study is to examine effectiveness of the application of povidone-iodine (PVP-I) impregnated incise film on treatment of diaper dermatitis.

## MATERIALS AND METHODS

The study was approved by the ethics committee of Bozok University Medical Faculty. Among 86 consecutive patients

\*Corresponding author: Mesut Sipahi,

<sup>1</sup>Bozok University School of Medicine, Department of General Surgery, Yozgat, Turkey.

aged between 4 and 36 months, presented to the pediatrics outpatient clinic and diagnosed with irritant diaper contact dermatitis between January 2015 and June 2015, 68 patients who completed the follow-up after treatment were included in the study. Parents of the patients were informed about classical treatment and drape application gave written consents. Patients with a history of thyroid disease, goitre detected in physical examination, those having a history of systemic or metabolic disease, secondary infection in the diaper underpad site and the patients with a history of the use of steroids were excluded from the study. Severity of dermatitis was assessed with a 5-point scoring system described by Davies *et al.* Zero point indicates existence of no rash; 1 point mild rash with mild maceration, 2 points: moderate rash, maceration and/or independent papules; 3 points: severe rash with papulopustula, maceration and 4 points: severe rash, erosions and ulceration of the skin (Davies *et al.*, 2005). Patients with 0 points were considered to have normal skin findings, while the infants with 1 point were determined as to have first grade dermatitis, 2 points as second grade dermatitis, 3 points as third grade dermatitis and 4 points fourth grade dermatitis. Taking into account the preferences of the parents, patients were divided into two groups as the controls receiving classical treatment and study group receiving drape therapy. Demographics of the two groups were recorded and the levels of diaper dermatitis were determined. The control group was prescribed standard treatment in concordance with the guidelines with description of use. Povidone-iodine impregnated drape (Rashfix, Sipahi, Yozgat, Turkey) was prepared by cutting in a shape of 5x10 cm rectangular. In the study group, mechanical cleaning of the underpad site with a wet cotton cloth was performed under supervision of their parents. After the underpad site was cleaned and dried, prepared drape was applied (Figure 1). The families were given 3 prepared drapes. Cleaning of the skin and application of the drape were described. They were advised to change the drape in the event of unstick and/or after 24 hours. All the patients were asked to come for control at posttreatment first and third days. Diaper dermatitis scores were evaluated and recorded. The statistical analysis was performed utilizing SPSS 18 for Windows (SPSS Inc., Chicago, IL, USA) software package with a significance level set at  $p < 0.05$ . Dermatitis scores were evaluated pretreatment, on day one and three days after the treatment with Kruskal Wallis test. The decrease in dermatitis score between the two groups was evaluated with Mann Whitney-U test. Dermatitis scores were evaluated in the dependent groups between pretreatment and the first day and between the first day and the third day with Wilcoxon test.

## RESULTS

Of 86 patients diagnosed with irritant contact diaper dermatitis, 40 were assigned to the study and 46 to the control group. In the study group; 2 patients did not come to control at the first day and 9 patients at the third day, while in the control group 4 patients did not come to control at the first and 9 patients at the third day. Considering a total of 68 patients who completed the follow-ups, there were 31 patients in the study and 37 patients in the control group. The control group consisted of 12 girls and 25 boys of which 12 had third, 18 second and 7 first grade dermatitis. Whereas of 16 girls and 15 boys in the study group, 12 had third, 12 second and 7 first grade dermatitis (Figure 2). None of the patients included in the study (control or study group) had fourth grade dermatitis. There was statistically significant improvement in the dermatitis scores between the

days 0 and 1 and the days 1 and 3 in both two groups in themselves ( $p < 0.01$ ). Both treatment options were found to be effective in irritant contact diaper dermatitis. When the two groups were compared, the dermatitis scores were similar pretreatment and at the third day ( $p = 0.888$ ,  $p = 0.119$ ). However, dermatitis scores at the first day were significantly lower in the study group compared with the controls ( $p < 0.01$ ).

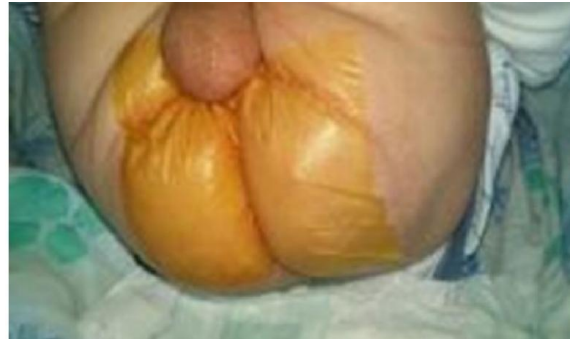

Figure 1. Application of incise drape

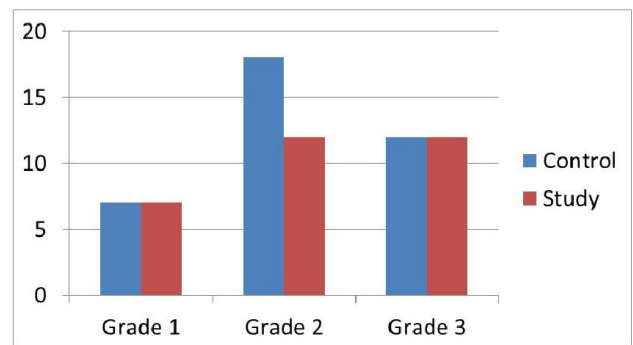


Figure 2. The number of patients accordingly dermatitis scores

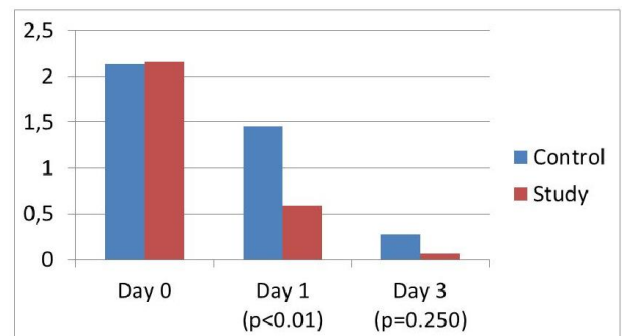
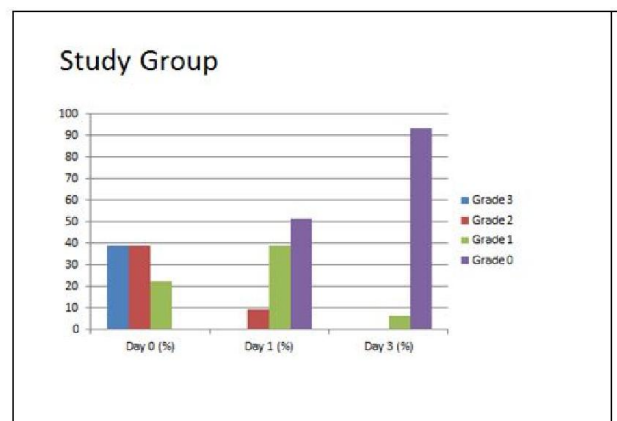
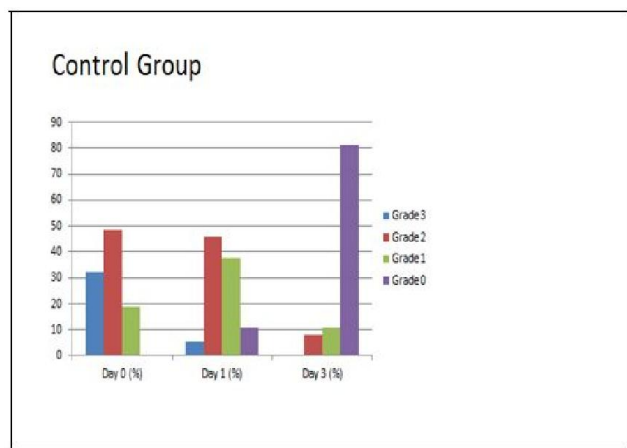


Figure 3. Mean dermatitis scores after treatment





**Figure 4. Recovery rates of study and control groups**

Although the treatment level at the third day was similar for the two groups, the study group were found to receive more effective treatment in terms of the treatment level at the first day. The mean dermatitis scores were found as 2.16, 0.58 and 0.06 in the study group at the days 0, 1 and 3; respectively, while these respective values were found as 2.14, 1.46 and 0.27 in the control group (Figure 3). In the study group, the mean dermatitis score which was 2.16 pretreatment improved by 1.58 at the first day and 2.10 at the third day of the treatment. In the control group, the mean dermatitis score which was 2.14 pretreatment decreased by 0.68 in the first day and 1.86 in the third day of the treatment. No significant difference was found in the degree of improvement at the third day between the groups ( $p=0.250$ ), while the degree of improvement at the first day was higher in the study group ( $p<0.01$ ). Among 31 patients from the study group; third grade dermatitis found in 38.7%, second grade dermatitis in 38.7% and first grade dermatitis in 22.6% of the patients at the postoperative day 0. These rates were regressed to the third grade dermatitis in 0%, second grade dermatitis in 9.7% and first grade dermatitis in 38.7%, while dermatitis was regressed to normal skin findings in 51.6% of the patients at the day 1. Whereas first grade dermatitis was found in 6.5% of the patients, while there were normal skin findings in 93.5% at the day 3. In the control group; third grade dermatitis was found in 32.4%, second grade dermatitis in 48.6% and first grade dermatitis in 18.9% of the patients at the day 0, while at the first day third grade of dermatitis was found in 5.4%, second grade dermatitis in 45.9%, first grade dermatitis in 37.8% and normal skin findings in 10.8% of the patients. Full recovery was observed in 10.8% of the patients in the control group at the first day. As in the study group, among the controls also no third grade dermatitis was observed, while second grade dermatitis was found in 8.1%, first grade dermatitis in 10.8% and normal skin findings in 81.1% of the patients. At the end of the third day, full recovery was found by 93.5% in the study group and 81.1% in the control group (Figure 4).

## DISCUSSION

Iodine impregnated incision drapes are a material used in surgery in order to reduce postoperative wound site infections. A diaper consists of a breathable film layer on the top and iodine impregnated layer at the bottom which is adhered on the skin. The drapes adhered to the skin before surgery and used for the disinfection of bacteria and to prevent movement of bacteria toward wound site (Kattbogen *et al.*, 1991; Ha'eri,

1983. The cause of surgical site infections is multifactorial. Although there are contradictory publications in the literature proposing that surgical drapes decrease surgical site infections, these material which decrease bacterial contamination are widely used in surgery (Webster and Alghamdi, 2013; Dewan *et al.*, 1987. There are 4 causative factors in irritant contact dermatitis including wetness, friction, urine and feces and microorganisms (Humphrey *et al.*, 2006). Excessive hydration and maceration of the stratum corneum impair the barrier function of the skin, facilitating the penetration of microorganisms (Zimmerer *et al.*, 1986). Additionally, friction also disrupt the barrier function of the skin through mechanical trauma. In 1988, Berg *et al.* described that irritant contact dermatitis develops as a result of influencing of the skin by physical, chemical, enzymatic and microbial factors (Berg, 1987). Besides maceration of the skin and impaired barrier function, degradation of urea found in the urine by bacterial enzymes urease increases pH which in turn causes activation of inactive enzymes in the stool. The activated proteases and lipases causes irritant dermatitis in the skin with weakened defensive features (Shin, 2005; Berg, 1987. Diaper dermatitis creates a favorable ground for bacterial colonization and infections. The leading microorganism generated in diaper dermatitis is candida albicans followed by more infrequent staphylococci and streptococci species (Benjamin, 1986; Gökalp *et al.*, 1990). The main goals in the treatment of diaper dermatitis include keeping the skin dry, protecting the skin against irritating chemical agents and infection therapy for bacteria and fungi. ABCDE therapy has been described for this purpose (Boiko, 1999). The current treatment include quick diaper change (Humphrey *et al.*, 2006), ventilation through diaper free time, the use of barriers, keeping the skin dry and education of caregivers. This treatment method was applied on the patients in the control group and a successful treatment was achieved. At the end of the third day, dermatitis scores improved in 100% of the patients, while full recovery was observed by 81%. Classical treatment is an effective treatment option in irritant contact diaper dermatitis and can be successfully administered. However, 6.5% of all the patients in the study group regressed to the first grade dermatitis, while 93.5% fully recovered. No statistically significant difference was found between the groups in the third day scores. However, a significant improvement was observed in the study group compared to the control group at the end of the first day ( $p<0.01$ ). We think that this difference resulted from the following features of surgical drapes. Whereas cream barrier that are used in the classical treatment feature a partial barrier against the stool, urine and other irritant agents, surgical drapes features full barrier between the skin and the external environment. No matter how much care is taken after fastening the diaper in infants, cleaning again for a new urine and feces takes a certain time. Drapes prevent the skin against irritating chemicals during this time.

In the classical treatment, the skin which has already been irritated during mechanical cleaning of the urine and feces, exposes to trauma again. Since the cleaning is made over the drape in the babies with drapes adhered, no trauma occurs again during the cleaning. We think that, effect of the antibacterial cream application lasts short since the cream is absorbed by the skin in a short time, it is also absorbed by the underpad and distributed on movement. Whereas, iodophor which is used in the drape application has a direct and long lasting effect on the skin owing to its broad antibacterial feature (Kramer *et al.*, 2010).

## Conclusion

Iodine impregnated incision drapes may be one of the fast-acting treatment options for the treatment of irritant contact diaper dermatitis.

## REFERENCES

- Benjamin L. 1986. Clinical correlates with diaper dermatitis. *Pediatrician*, 14:21-6.
- Berg R. 1987. Etiology and pathophysiology of diaper dermatitis. *Advances in dermatology*. 3:75-98.
- Boiko S. 1999. Treatment of diaper dermatitis. *Dermatologic Clinics*, 17(1):235-40.
- Davies MW, Dore AJ, Perissinotto KL. 2005. Topical vitamin A, or its derivatives, for treating and preventing napkin dermatitis in infants. *Cochrane Database Syst Rev.*, 19(4).
- Dewan P, Van Rij A, Robinson R, Skeggs G, Fergus M. 1987. The use of an iodophor-impregnated plastic incise drape in abdominal surgery- A controlled clinical trial. *Australian and New Zealand Journal of Surgery*, 57(11):859-63.
- Gökalp A, Aldirmaz C, Oğuz A, Gültekin A, Bakici M. 1990. Relation between the intestinal flora and diaper dermatitis in infancy. *Tropical and Geographical Medicine*, 42(3):238-40.
- Ha'eri GB. 1983. The efficacy of adhesive plastic incise drapes in preventing wound contamination. *International surgery*. Jan-Mar;68(1):31-2. PubMed PMID: 6853079. Epub 1983/01/01. eng.
- Humphrey S, Bergman J, Au S. 2006. Practical management strategies for diaper dermatitis. *SkinTherapyLett.*, 11(7):1-6.
- Jordan W, Lawson K, Berg R, Franxman J, Marrer A. 1986. Diaper dermatitis: frequency and severity among a general infant population. *Pediatric Dermatology*, 3(3):198-207.
- Katthagen B, Zamani P, Jung W. 1991. [Effect of surgical draping on bacterial contamination in the surgical field]. *Zeitschrift für Orthopädie und ihre Grenzgebiete*. 130(3):230-5.
- Kramer A, Assadian O, Lademann J. 2010. Prevention of postoperative wound infections by covering the surgical field with iodine-impregnated incision drape (Ioban® 2). *GMS Krankenhaushygiene interdisziplinär*, 5(2).
- Serdaroğlu S, Üstünbaş TK. 2010. Diaper Dermatitis (Napkin Dermatitis, Nappy Rash). *J Turk Acad Dermatol.*, 4(4):04401r.
- Shin HT. 2005. Diaper dermatitis that does not quit. *Dermatologic Therapy*, 18(2):124-35.
- Tüzün Y, Wolf R, Bağlam S, Engin B. 2015. Diaper (Napkin) Dermatitis: A Fold (Intertriginous) Dermatoses. *Clinics in Dermatology*.
- Webster J. and Alghamdi A. 2013. Use of plastic adhesive drapes during surgery for preventing surgical site infection. *The Cochrane Library*.
- Yoshimura Y, Kubo S, Hirohashi K, Ogawa M, Morimoto K, Shirata K, et al. 2003. Plastic Iodophor Drape during Liver Surgery Operative Use of the Iodophor-impregnated Adhesive Drape to Prevent Wound Infection during High Risk Surgery. *World Journal of Surgery*, 27(6):685-8.
- Zimmerer R, Lawson K, Calvert C. 1986. The effects of wearing diapers on skin. *Pediatric Dermatology*, 3(2):95-101.

\*\*\*\*\*