



RESEARCH ARTICLE

AMELIORATIVE EFFECTS OF *MORINGA OLEIFERA* LAM. LEAF EXTRACT AGAINST SYSTEMIC IMMUNE EFFECTS OF TITANIUM DIOXIDE NANOPARTICLES IN MALE ALBINO RATS

*Dr. Eman Mohammed Mohammed Abd-Ella

Lecturer of Histology and Cytology, Zoology Department, Faculty of Science, Fayoum University, Egypt

ARTICLE INFO

Article History:

Received 20th September, 2016
Received in revised form
18th October, 2016
Accepted 05th November, 2016
Published online 30th December, 2016

Key words:

TiO₂ NPs,
Moringa,
Spleen,
Immune Responses,
CD3,
TNF- α .

ABSTRACT

Introduction and aim of the work: The protective effects of *Moringa oleifera* leaves extract (*MOLE*) against orally administered titanium dioxide nanoparticles (TiO₂ NPs) for 3 months on male albino rats were examined. Methods: The rats were divided into five groups • Group 1: rats were orally administrated with saline as a negative control group, • Group 2: Rats were orally administrated with TiO₂ (1200 mg kg⁻¹) (1\10 LD50), Group 3: Rats were administrated orally by *MOLE* (50 mg kg⁻¹ BW), Group 4: co-treatment of *MOLE* and TiO₂ as a protective group for 3 months and Group 5: post treatment of TiO₂ by *MOLE* for 3 successive month as therapeutic treatment. Spleen was examined for alterations in cytokines expression as CD3 and TNF- α , histopathology and histochemically by estimation of total proteins and polysaccharides. Results: TiO₂ NPs up-regulated CD3 and TNF- α expression in spleen where TNF- α expression was significantly increased (p<0.05) and CD3 expression was significantly (P<0.05) decreased but *MOLE* administration as co-treatment or therapeutic normalized cytokines expression. Conclusion: present findings confirmed the protective and therapeutic effects of *MOLE* on TiO₂ NPs induced alteration in immune responses in male albino rats.

Copyright©2016, Eman Mohammed Mohammed Abd-Ella. This is an open access article distributed under the Creative Commons Attribution License, which permits unrestricted use, distribution, and reproduction in any medium, provided the original work is properly cited.

Citation: Eman Mohammed Mohammed Abd-Ella, 2016. "Ameliorative effects of *Moringa oleifera* Lam. leaf extract against systemic immune effects of titanium dioxide nanoparticles in male albino rats", *International Journal of Current Research*, 8, (12), 43441-43449.

INTRODUCTION

The spleen is an organ found in virtually all vertebrate animals. Similar in structure to a large lymph node, it acts primarily as a blood filter. The spleen plays important roles in regard to red blood cells (also referred to as erythrocytes) and the immune system. It removes old red blood cells and holds a reserve of blood, which can be valuable in case of hemorrhagic shock, and also recycles iron. As a part of the mononuclear phagocyte system, it metabolizes hemoglobin removed from senescent erythrocytes. The globin portion of hemoglobin is degraded to its constitutive amino acids, and the heme portion is metabolized to bilirubin, which is removed in the liver (Mebius and Kraal, 2005). The spleen synthesizes antibodies in its white pulp and removes antibody-coated bacteria and antibody-coated blood cells by way of blood and lymph node circulation. A study published in 2009 using mice found that the spleen contains, in its reserve, half of the body's monocytes within the red pulp (Swirski *et al.*, 2009). Monica premi, stated that these monocytes, upon moving to injured tissue (such as the heart), turn into dendritic cells and macrophages while promoting tissue healing (Monica premi *et al.*, 2010). Brender mentioned that the spleen is a center of activity of the

mononuclear phagocyte system and can be considered analogous to a large lymph node, as its absence causes a predisposition to certain infections (Brender *et al.*, 2005). Titanium dioxide nanoparticles (TiO₂ NPs) are widely used in a number of applications: as an additive, including as a white pigment in paint, as a food colorant, in sunscreens and in cosmetic creams as well as in the environmental decontamination of air, water and soil by the destruction of pesticides (Medina *et al.*, 2007). Hoet mentioned that with the rapid development of nanotechnology, the potential health hazards and environmental impact of manufactured TiO₂ NPs have gained increasing attention (Hoet *et al.*, 2004). Sang added that the smaller the particles of TiO₂, the more reactivity, effectively and toxicity (Sang *et al.*, 2012). Intraperitoneal injection of 100-nm TiO₂ NPs in high doses (324-2592 mg kg⁻¹ bw) caused significant accumulation of particles, mainly in the spleen, but also in the liver, kidney and lung (Chen *et al.*, 2009). *Moringa oleifera* (*M. oleifera*) Lam. (local name Sajna) belongs to the Moringaceae family (Goyal *et al.*, 2007). It is a multipurpose tree widely distributed in Bangladesh, India, Pakistan, Sri Lanka, Myanmar, Malaysia, Singapore, the Philippines, Thailand, Cuba, Jamaica and Nigeria (Guevara *et al.*, 1999). *M. oleifera* is valued mainly for the young leaves and tender pods which are esteemed as very common vegetable in Bangladesh and India. It is reported that

*Corresponding author: Dr. Eman Mohammed Mohammed Abd-Ella, Lecturer of Histology and Cytology, Zoology Department, Faculty of Science, Fayoum University, Egypt.

Moringa leaf is a potential source of natural antioxidants such as total phenolic and antioxidant vitamin A, C and E, ascorbic acid oxidase, polyphenol oxidase and catalase (Gyton and Hall, 2006; Harold, 2006). The leaves are a rich source of essential amino acids such as methionine, cysteine, tryptophan, lysine, vitamins and minerals (Jahn, 1988). Moringa leaves have been reported to act as a hypocholesterolemic agent, thyroid hormone regulator, antidiabetic agent, antitumor agent and hypotensive agent (Moore *et al.*, 2010). Despite the above mentioned beneficial effect of Moringa leaves, its efficacy in reducing particular toxicity in general and Nano-titanium toxicity in particular, has not yet been studied enough. Therefore, we aimed to investigate the efficacy of *M. oleifera* leaves on nano-titanium toxicity in rats' model.

MATERIALS AND METHODS

Chemicals: Titanium Dioxide nano-particles (TiO₂ NPs): Anatase form, particle size (25-100 nm) was purchased from Sigma Aldrich chemical Co., USA.

Animals: Tow-month old (160 - 200 g body weight) male albino rats (*Rattus rattus*) were selected from animal house of National Research Center, Giza, Egypt. The animals were housed under controlled environment conditions (12 h light/dark cycle) at a temperature of 25°C + 10°C and humidity of 60% + 5% and fed standard diet and water *Ad libitum* for the experimental period.

Plant material: *Moringa oleifera* leaves powdered obtained as capsules (natural product drug) from local pharmacy of Texas, USA.

Extract preparation of *Moringa oleifera* leaves (MOLE)

The ethanol extracts was prepared by soaking 100 gm of *Moringa oleifera* leaves powdered in 300 ml ethanol (95%) shaking (24 h) then covered by a piece of aluminum foil and kept in the refrigerator. The infusion was filtered by a piece of double gauze and the filtrate was centrifuged at 3000 rpm for 10 minutes, then the supernatant (ethanol) was evaporated using a rotatory evaporator apparatus attached to a vacuum pump. The 100 gm of dried grape seeds powder yield 26.7 gm ethanol (Balu *et al.*, 2016).

Experimental protocol: The rats were randomly divided into 5 groups of 12 animals each as follows:

- Group 1: served as negative control (rats were orally administrated with ml of normal saline for 3 month).
- Group 2: (positive control group) TiO₂ NPs -intoxicated rats: received 1200 mg kg⁻¹ body weight TiO₂ NPs by gavage (1/10 LD 50) in 1 mL saline solution as a solvent once daily for 3 months (Wang *et al.*, 2007).
- Group 3: (MOLE control group): Rats were administrated orally MOLE (50 mg/kg b.w/day) diluted with saline solution; once daily for three months.
- Group 4: (MOLE +TiO₂); co-treatment group: received 50 mg kg⁻¹ body weight MOLE one hour before TiO₂ by gavage once daily for 3 months.
- Group 5: (therapeutic group), rats received 1200 mg kg⁻¹ body weight TiO₂ by gavage (1/10 LD 50) in 1 mL saline solution as a solvent once daily for 3 months, then treated daily with a single dose of MOLE (50

mg/kg b.w/day) diluted with saline solution; for successive 3 months.

Examinations

Rats of each group were sacrificed by cervical dislocation at the end of the experimental periods and decapitation. Spleen of each animal was obtained and divided and fixed in buffered neutral formalin 10% solution for 24 hrs, dehydrated through alcohols, cleared in xylene and embedded in paraffin wax. Five-micrometer thickness paraffin sections were prepared and mount on clean slides. For histopathological studies, such as sections were stained with Ehrlich's hematoxylin and counterstained with eosin (Drury and Wallington, 1967). For histochemical investigations, the periodic acid Schiff's (PAS) technique of Hotchkiss (1948); was used for the detection of total carbohydrates; 1, 2 glycol group. Bromophenol blue method to demonstrate total proteins (Maize, 1953). For immunohistochemical studies; other sections were deparaffinized, placed on charged slides, and used for localization of CD3; (cluster of differentiation 3), T-cell co-receptor helps to activate the cytotoxic T-Cell; and TNF- α ; (tumor necrosis factor alpha), It is produced chiefly by activated macrophages, where it's primary role is in the regulation of immune cells; on cells. Anti-CD3 and TNF- α antibodies respectively were employed to stain the cells in an avidin-biotin-complex (ABC) immunoperoxidase technique. Specifically, the sections were incubated in 5% H₂O₂ (in methanol) solution for 10 min to block endogenous peroxidase activity and then incubated with primary anti-CD3 and TNF- α rabbit monoclonal antibody respectively (1:50 dilution in 1% bovine serum albumin solution; Pan-T Clone SP7, Thermo Scientific, Lab Vision, Fremont, CA) for 60 min at room temperature. After rinsing with phosphate-buffered saline (PBS, pH 7.4) to remove unbound primary antibody, the samples were incubated with diaminobenzidine (DAB) chromogenic solution for 5 min at 25°C. The sections were then counterstained with haematoxylin for 15 sec. (Kiernan, 2007). For statistical analysis, each section was counted manually at high power (X400) after identifying at low power (x100). The representative areas with the highest concentration of stained cells were detected according to the recommendation of Cohen and Hogan (1994). About 1000 cells/slide were counted in each of five microscopic fields from well-labeled areas to determine the average of TNF- α Labelling index. TNF- α was expressed as number of labeled cells (positive for TNF- α) as a percentage of the total number of cells counted in each specimen. All identifiable staining was regarded as positive. Then this method applied with CD3 expression.

Statistical analysis

The obtained results of each of, TNF- α and CD3 were expressed as mean + Standard Error (SE). They were also statistically analyzed by using the SPSS11 computer software program (ANOVA) analyses.

RESULTS

Histopathological results

The spleen tissues of the negative control group are illustrated in Figure 1(A). This spleen tissue is normal in histological presentation and appeared with normal architecture. The spleen

tissue sections consist of the white and red pulps. Where the white pulp contain the splenic follicles and the marginal zone, while red pulp consists of many splenic sinusoids, small macrophages and large-sized megakaryocytes. In Figure 1 (B); the photomicrograph illustrate the spleen tissue of the MOLE control group. The pulps are also well defined and the entire tissues structural integrity is normal. The white pulps appear relatively quiet prominent. The specimens of TiO₂ NPs treated group (positive control group) show the white pulp contains lymphocytic proliferation around the central vein, peri-arterial lymphocytic sheath (PALS) with congestion in the blood vessels and degenerated areas with apoptotic cells; Figure 1 (C, D & E). The spleen of the MOLE and TiO₂ NPs co-administered rats (protective group) showed decrease in the lymphocytic proliferation especially around the PALS, while the congestion still persist; Figure 1 (F). Most of the tissue sections of spleen of group 5 (therapeutic group), show apparent normal structure for white and red pulps as it was seen in the normal control group Figure 1 (G).

Table 1. Means of TNF- α antibody values recorded at different treatments

Groups	Parameters	Mean + SE	P value
negative control, group 1		12.00 \pm 0.97	--
TiO ₂ NPs -intoxicated, group 2		49.70 \pm 2.25 ^a	< 0.05
MOLE control, group 3		14.60 \pm 1.05	--
co-treatment, group 4		23.20 \pm 2.00 ^b	< 0.05
therapeutic group, group 5		70.10 \pm 6.11 ^b	< 0.05

a significant difference with the group I

b significant difference with the group II

Results are expressed as mean \pm SD

LSD_{0.05 - 0.01} (1.04 - 1.39)

Table 2. Means of CD3 antibody values recorded at different treatments

Groups	Parameters	Mean + SE	P value
negative control, group 1		39.00 \pm 0.93	--
TiO ₂ NPs -intoxicated, group 2		19.10 \pm 2.20 ^a	< 0.05
MOLE control, group 3		50.20 \pm 1.61 ^a	< 0.05
co-treatment, group 4		52.40 \pm 2.86 ^b	< 0.05
therapeutic group, group 5		32.90 \pm 1.31 ^b	< 0.05

a significant difference with the group I

b significant difference with the group II

Results are expressed as mean \pm SD

LSD_{0.05 - 0.01} (1.24 - 1.69)

Histochemical results

Negative control and MOLE control spleen sections stained with PAS method are shown in Figure 2 (A & B). This spleen tissue is normal in polysaccharides contents and the pulps are also well defined and the entire tissues structural integrity is normal. The white pulps appear relatively quiet prominent. Splens of rats administered TiO₂ NPs had an alteration in carbohydrate content. Glycogen appeared around the cell membranes Figure 2 (C & D). Most of the tissue sections of

spleen of group 4 & 5 (protective and therapeutic group), show apparent normal structure for white and red pulps as it was seen in the normal control group and positive reaction of PAS at the wall of blood vessels Figure 2 (E & F). Examination of spleen sections from the negative control and MOLE control groups, spleen sections stained with by bromophenol blue method, showed normal protein content and the pulps are also well defined and the entire tissues structural integrity is normal. The white pulps appear relatively quiet prominent, Figure 2 (G & H). Protein content was moderately decreased in the splenic cells of rats administered with TiO₂ NPs, Figure 2 (I). Most of the tissue sections of spleen of group 4 & 5 (protective and therapeutic group), show apparent normal structure for white and red pulps as it was seen in the normal control group Figure 2 (J & K).

Immunohistochemical results

TNF- α labeled cells in spleen sections were increased after administration of TiO₂ NPs; Figure 3 (C); when compared with Spleen sections from the negative control rats of group 1 as well as the sections of spleen of MOLE control, group 3; Figure 3 (A & B). Sections of spleen from co-treatment (groups 4) revealed shortage of the numbers of TNF- α labeled cells when compared with TiO₂ NPs -intoxicated, group 2, but more pronounced increasing at sections of group 5 than spleen sections of TiO₂ NPs group 2 Figure 3 (D & E) respectively. The mean optical density of TNF- α expression for all groups presented in Table 1. There was a significant increase (P<0.05) in TNF- α expression in TiO₂ NPs -intoxicated, group 2 with mean value 49.70 \pm 2.25 compared with negative control, group 1 with mean value 12.00 \pm 0.97 as well as the sections of spleen of MOLE control, group 3 with mean value 14.60 \pm 1.05. There was a significant decrease (P<0.05) in TNF- α expression in co-treatment (groups 4) with mean value 23.20 \pm 2.00 when compared with TiO₂-intoxicated, group 2. But TNF- α expressions more pronounced increased; significant increase (P<0.05); at group 5 in mean value 70.10 \pm 6.11 when compared with TiO₂-intoxicated. Spleen sections from the negative control rats of group 1 showed normal distribution of CD3+ T-lymphocytes through the cells of white pulp; Figure 3 (F); while the sections of spleen of MOLE control group 3 as well as co-treatment group 4 showed high distribution of CD3+ T-lymphocyte numbers; Figure 3 (G & I); when compared with TiO₂ NPs -intoxicated, group 2 that showed high decrease in CD3+ T-lymphocyte distribution through the PALS of spleen sections that the majority of cells were weakly stained, and only a few had a strongly positive reaction; Figure 3 (H). Sections of spleen from therapeutic groups (groups 5); Figure 3 (J) revealed slight increasing in the numbers of CD3+ T-lymphocytes when compared with TiO₂ NPs -intoxicated, group 2 but more pronounced at sections of group 4. The mean optical density of CD-3 expression for all groups presented in Table 2. There was a significant decrease (P<0.05) in CD-3 expression in TiO₂ NPs -intoxicated, group 2 with mean value 19.10 \pm 2.20 compared with negative control, group 1 with mean value 39.00 \pm 0.93 and MOLE control, group 3 with mean value 50.20 \pm 1.61. There was a significant increase (P<0.05) in CD-3 expression in both co-treatment and therapeutic groups (groups 4 & 5 respectively) with TiO₂ NPs -intoxicated, group 2 with mean value 19.10 \pm 2.20, but CD-3 expressions was more pronounced at group 4 in mean value 52.40 \pm 2.86 than sections of group 5 in mean value 32.90 \pm 1.31.

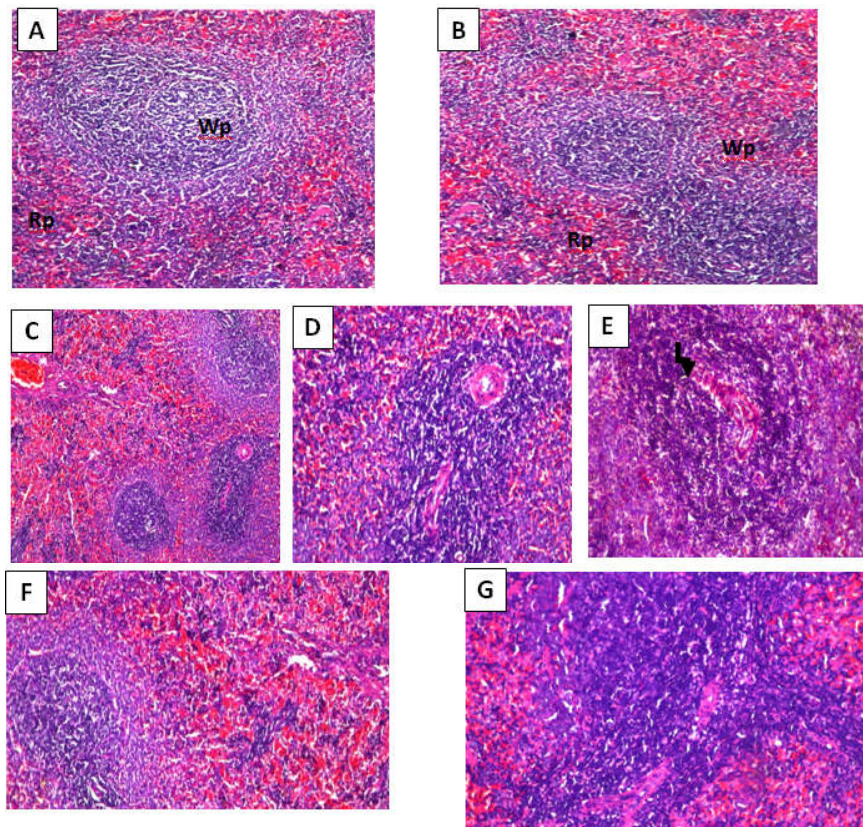


Figure 1. (A) Normal histological features of splenic tissue of the negative control group I stained with hematoxylin and eosin, it consists of the capsule, white pulps (wp) with the central arteries, trabeculae and red pulps (rp), vascular organization and cellular composition (400X). (B) Normal histological features of splenic tissue of the MOLE control group III stained with hematoxylin and eosin, it consists of the capsule, white pulps (wp) and red pulps (rp), vascular organization and cellular composition (400X). (C, D, & E) Spleen sections of rats administered TiO₂ NPs group II show enlarged white pulps, thickened capsule, increased proliferation of lymphocytes with some degenerated areas (arrow) and apoptotic cells, hematoxylin-eosin (400, 800, 400 x respectively). (F) Spleen section of co-treatment group IV, slightly there is no histopathological alterations, hematoxylin-eosin (400 x). (G) Spleen section of therapeutic group V, there is no histopathological alterations but there is slightly increasing proliferation of lymphocytes, hematoxylin-eosin (400 x)

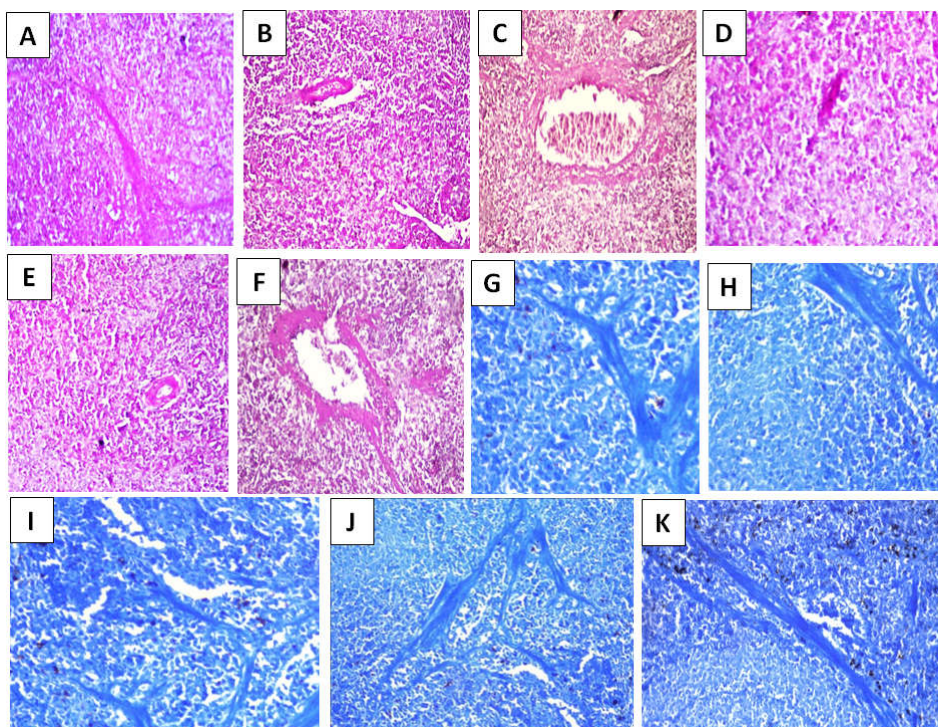


Figure 2. Total carbohydrates in spleen sections. (A): Normal features of splenic tissue of the negative control group I stained with PAS (200x). (B) Normal features of splenic tissue of the MOLE control group III stained with PAS (200x). (C, D) Spleen sections of rats administered TiO₂ NPs group II show a slight decrease in carbohydrate content, stained with PAS (200x). (E) Spleen section of co-treatment group IV, mild alterations in carbohydrate content, stained with PAS (200x). (F) Spleen section of therapeutic group V, slight normal distribution of carbohydrate contents, stained with PAS (200x). - Protein content in spleen sections. (G): splenic tissue of the negative control group I with a considerable amount of protein elements, stained with bromophenol blue (200x). (H) Normal features of splenic tissue of the MOLE control group III stained with bromophenol blue (200x). (I) Spleen section of rat administered TiO₂ NPs group II show a slight decrease in protein content with a weak response towards bromophenol blue reaction, stained with bromophenol blue (200x). (J) Spleen section of co-treatment group IV, mild alterations in protein content, stained with bromophenol blue (200x). (K) Spleen section of therapeutic group V, slight normal distribution of protein contents, stained with bromophenol blue (200x)

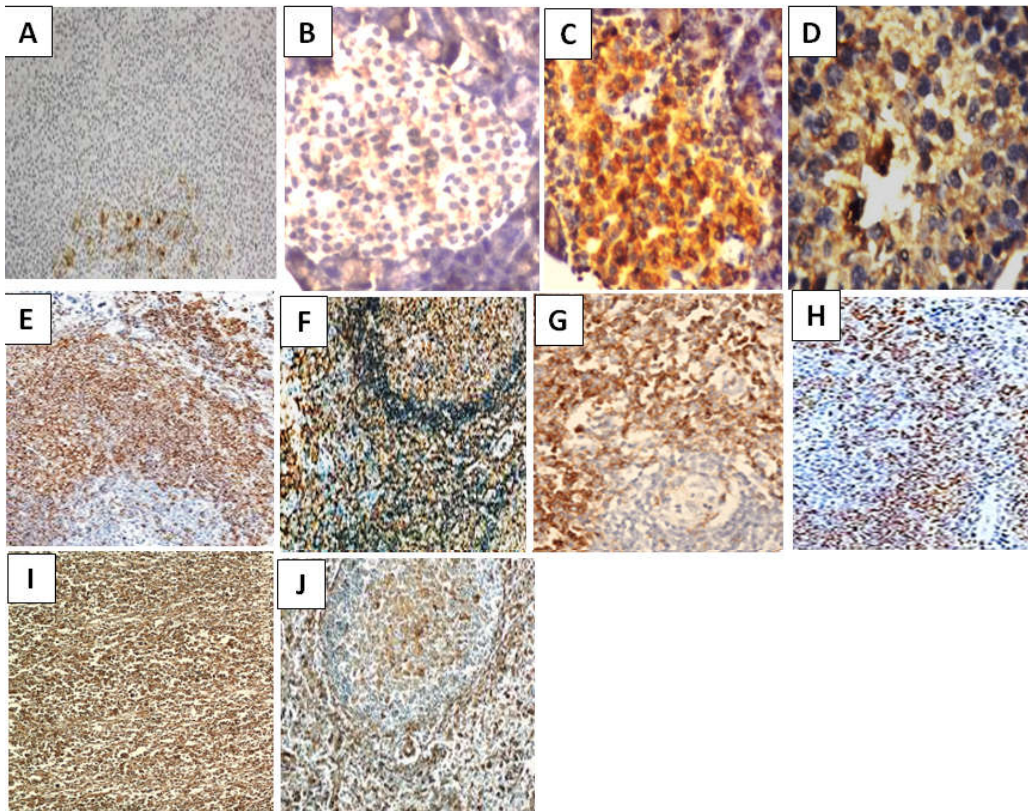


Figure 3. (A): splenic tissue of the negative control group I with a weak diffuse of immunostaining TNF- α (Immunoperoxidase, X200). (B) Normal features of splenic tissue of the MOLE control group III shows week to mild diffuse of immunostaining TNF- α (Immunoperoxidase, X400). (C) Spleen sections of rats administered TiO₂ NPs group II show a high diffuse of immunostaining TNF- α (Immunoperoxidase, X400). (D) Spleen section of co-treatment group IV, with a slight diffuse of immunostaining TNF- α (Immunoperoxidase, X400). (E) Spleen section of therapeutic group V, show a high diffuse of immunostaining TNF- α (Immunoperoxidase, X200). (F): splenic tissue of the negative control group I with a moderate diffuse of immunostaining CD3 (Immunoperoxidase, X200). (G) Normal features of splenic tissue of the MOLE control group III shows slightly high diffuse of immunostaining CD3 (Immunoperoxidase, X200). (H) Spleen sections of rats administered TiO₂ NPs group II show a weak diffuse of immunostaining CD3 (Immunoperoxidase, X200). (I) Spleen section of co-treatment group IV, with high diffuse of immunostaining CD3 (Immunoperoxidase, X200). (J) Spleen section of therapeutic group V, show a moderate diffuse of immunostaining CD3 (Immunoperoxidase, X200)

DISCUSSION

Increased use of artificial nanoparticles in a wide range has introduced a potential inhaled pollutant. As a result of expanding usage of TiNPs in various products as well as in biological and medical applications, it is important to study their environmental safety, transport and possible toxicological effects on humans. Recordati explained that the toxicity of TiNPs is size- and dose-dependent as well as coating- and cell type-dependent (Recordati *et al.*, 2016). Although the reports on toxicity of nanoparticles are now increasing, immunity-related responses of nanoparticles have not been well studied. In this study, we focused on the systemic immune response induced by repeated exposure of titanium dioxide nanoparticles, involved in immune organ formation, lymphocyte proliferation, lymphocyte distribution and cytokine induction. Chen demonstrated that acute toxicity induced by various doses of TiO₂ NPs in mice, that accumulation of TiO₂ NPs (80 nm, 100 nm, anatase) was high in spleen, liver, kidneys and lung in a decreasing manner (Chen *et al.*, 2009). Some of the particles were excreted from the kidney and Linglan found that the inflammatory cytokines cascade may cause inflammatory cell chemotaxis and apoptosis, resulting in serious spleen injury (Linglan *et al.*, 2009). According to Shi, the cellular damage and oxidative stress of nanoparticles in the splenocytes were related to the particle size and chemical compositions of nanoparticles (Shi *et al.*, 2013). Most of nanoparticles tend to accumulate in the

liver (Sadauskas *et al.*, 2007) as well as spleen and kidney (Xue *et al.*, 2011). In the present study spleen of the TiO₂ NPs treated groups showed many drastic changes in the white pulps. As progressive dilation and congestion of blood sinuses, increased number of connected white pulps with increased proliferation of lymphocytes, dilated and elongated trabecular. The dilated and elongated splenic vein may referred to decreased ribosomes, glycogen granules and cristae of mitochondria may led to corrugated membranes, (Khaki *et al.*, 2006). Also Melamed mentioned that progressive dilation and congestion of blood sinusoids could be considered as a reactive change that may be related to the inhibitory effect on the vascular smooth muscles which induced relaxation and consequent vasodilatation (Melamed *et al.*, 2003). Danz reported that this vasodilatation and increased vascular permeability should lead to loss of fluid from the blood which would result in degeneration and necrosis in the tissues and may be considered as a reaction to progressive epithelial cell death and atrophy of the tissue (Danz *et al.*, 1998). TiO₂ NPs treated group showed degenerative and atrophic changes in rat spleen with small sized lymphatic follicles and absence of germinal centers. The differentiation between red and white pulps was indistinct. This results are in agreement with (Circic *et al.*, 2005). Highly reduced total protein was detected in the splenic tissue with moderately stained capsule of TiO₂ NPs treated groups. Yee and Choi found that mercury treatment caused biochemical damage to tissues, total protein depletion and genes through diverse mechanisms, such as disrupting

membrane potential, altering protein synthesis and mitochondrial damage (Yee and Choi, 1996). Anthony and Allison & Gomez-Vargas found that the protein depletion of TiO₂ NPs treated groups may be due to the ability of TiO₂ to induce lysis of target cells by initiation of mitochondrial reaction, or tissue reaction as liposomes stimulating complexes (Gomez-Vargas, et al., 2004 and Anthony, C. and Allison, 2002). Harold added, it may also result by tissue destruction as activated vascular permeability and result in systemic effects that include fever and the production of acute-phase proteins (Harold, 2005). Also decreased protein content in tissue may be due to the drastic effect on the rough endoplasmic reticulum (RER), mitochondria and Golgi apparatus and increased lysosomes in the cells (Eid and Al-Dossary, 2007).

Highly decreased total glycogen was detected in the splenic tissue with moderately stained capsule of TiO₂ NPs treated groups. Decreased polysaccharides content in the degenerated epithelial cells of bronchioles and haemolysed RBCs was detected also by Abu El Naga; She stated that this decrease may be due to decreased T3 and T4 hormones of the thyroid glands, which lessen entrance of glucose to the cells, this investigation and the result of the present study were insured the finding of Viera; who reported that the nanoparticles effect may contributed to the cascade of reactions called "Gulf War syndrome", in which antithyroid effects were documented in its symptoms (Abu El Naga, 1989; Viera, 2001). Szelényi stated that cytokines are cell-signaling proteins secreted to mediate the immune response of a body and to regulate inflammatory processes. The family of cytokines includes pro-inflammatory proteins, such as tumor necrosis factor (TNF)- α cytokines allow organisms to respond to infectious agents and induce inflammation (Szelényi, 2001); where Abou-Raya and Kanterman found that over-production of these agents can occur as well, leading to chronic inflammation and/or autoimmunity (Abou-Raya, 2006; and Kanterman *et al.*, 2012). While the immune system and its cells have mechanisms to inhibit the inflammation induced by these cytokines (Kim *et al.*, 2004), changes in levels of these proteins can serve as an indirect index to assess immune function status (Liu *et al.*, 2014).

In the present study the values of TNF- α produced by TiO₂ NPs group showed significant increased difference. These results are in agreement with those of Carter and Swain, who stated that T lymphocytes were stimulated with TiO₂ NPs increased TNF- α cytokine production after 24h post stimulation (Carter and Swain, 1997). Where Roman-Ramos R, mentioned that administration of TiO₂ NPs to mice increased their mRNA expression of inflammatory genes including those for IL-6 and TNF α , once again, oxidative stress might also be involved in this process (Roman-Ramos *et al.*, 2011). In support of this notion, it was found that N-acetyl cysteine (anti-oxidant) attenuated lipopolysaccharide induced apoptosis in splenic lymphocytes (Martin *et al.*, 2000). The data presented here indicated that in fact there was a strong positive correlation among the changes in morphometrical results of TNF- α and the loss of splenic anti-oxidants; this lends credence to the potential role that oxidative stress might be having in mediating the immunotoxicity of TiO₂ NPs. As T-lymphocytes play an important role in maintaining host immune status (Ayuob, 2013), the alterations in T-lymphocyte levels in response to TiO₂ NPs consumption here may reflect a wider TiO₂ NPs - induced immunotoxicity. where TiO₂ NPs induced a decrease in CD3+ T-lymphocytes in the splenic PALS. These were

confirmed by morphometrical results which showed a significant decrease ($P < 0.05$) in optical density of CD-3 expression in TiO₂ NPs -treated group (II) compared with control group (I). Cemerski S, stated that oxidative stress induces structural modifications in T-lymphocytes, leading to their becoming hypo-responsive consequently (Cemerski *et al.*, 2003), the oxidative stress induced by TiO₂ NPs could be responsible for the reduction in T-lymphocytes in the spleen. Support for this hypothesis has been bolstered by a recent study wherein aluminum-induced oxidative stress reduced the number and density of T-lymphocytes in the spleen of pregnant rats (Ayuob, 2013). Plants have played a significant role in maintaining human health and improving the quality of human life for thousands of years and have served humans well as valuable components of medicines, seasonings, beverages, cosmetics and dyes (Agaie, 2004). Newman stated that herbal medicine is based on the premise that plants contain natural substances that can promote health and alleviate illness (Newman *et al.*, 2000).

One such plant, *Moringa oleifera*, (Family: Moringaceae) is a multipurpose tree, used as vegetable, spice, a source of cooking and cosmetic oil and as a medicinal plant (Fahey, 2005). *Moringa oleifera* is one of the leading names recently in plants and drug research. *Moringa Oleifera* leaves contain flavonoid pigments, such as kaempferol, rhamnetin, isoquercitrin and kaempferitrin. Flavonoid compounds have various biological activities, including antiinflammatory and anti-cancer ones (Jahn, 1988). In addition, the *Moringa Oleifera* leaves are rich in a group of the glycoside compounds, glucosinolates and isothiocyanates (Caceres *et al.*, 1992), as well as in beta-sitosterol, glycerol-1-(9-octadecanoate), 3-O-(6'-O-oleoyl-beta-D-glucopyranosyl), beta-sitosterol and beta-sitosterol-3-O-beta-D-glucopyranoside, all of which have demonstrated anti-cancer properties in-vitro (Chaurasia's, 2010). In this study we investigated the toxicological impacts of TiO₂ NPs on the spleen as well as the potential role of *Moringa Oleifera* leaves extract (MOLE) in the clearance of TiO₂ NPs from treated spleen and protection of spleen against toxic impacts caused by TiO₂ NPs. The mechanism action of flavonoid pigments of *Moringa Oleifera* leaves are best known as antioxidant free radical for scavenging and inhibition of lipid peroxidation (Flora *et al.*, 1998). MOLE has been reported to support the immune cells through its antioxidant activity and free-radical removing action (Basaga *et al.*, 1997). In this study, the MOLE gradients; flavonoid pigments might be able to react with the free radicals produced from the reaction of TiO₂ NPs and the spleen proteins and enzymes. Additionally MOLE could induce the immune systems in the treated rats with TiO₂ NPs. In our finding we reported that TiO₂ NPs decreased total protein and polysaccharides contents as well as decreased CD3 secretion and increased TNF- α secretion but MOLE administration as co-treatment (group 4) or therapeutic treatment (group 5) slightly normalized it in a way to initiate chemo-attractant mechanism. On the same line CD3 a cytokine produced primarily by monocytes and to a lesser extent by lymphocytes, has pleiotropic effects in immune-regulation and inflammation. It down-regulates the expression of Th1 cytokines and acts as anti-inflammatory cytokine (Heinrich *et al.*, 2003). Pestka reported that CD3 acts as an essential immune-regulator. This studies may explain the role of MOLE that ameliorate the toxic effect of TiO₂ NPs by inducing the immune system and increased the secretion of CD3 (Pestka *et al.*, 2004). TNF- α inhibits IL-1 and IL-6 production from macrophages (Fiorentino *et al.*, 1991). TNF- α

plays a critical role in shaping the development of the immune response by blocking class II major histocompatibility complex expression and decreasing pro-inflammatory cytokine expression (Newman *et al.*, 2000).

Where the primary role of TNF is in the regulation of immune cells. TNF, being an endogenous pyrogen, is able to induce fever, apoptotic cell death, cachexia, inflammation and to inhibit tumorigenesis and viral replication and respond to sepsis via IL1 & IL6 producing cells. Dysregulation of TNF production has been implicated in a variety of human diseases including Alzheimer's disease (Swardfager *et al.*, 2010), cancer (Locksley *et al.*, 2001), major depression (Dowlati *et al.*, 2010), psoriasis (Victor and Gottlieb, 2002) and inflammatory bowel disease (IBD) (Brynskov *et al.*, 2002).

So, the increase in TNF- α secretion and expression as shown in the therapeutic treatment by MOLE may referred to control degree of toxicity induced by TiO₂ and to counteract the increase in expression and secretion of IL-1 and 6. But the decrease in antibody secretion as shown in the co-treatment by MOLE may referred to the protective ability of MOLE that dependent on ameliorating the TiO₂ NPs toxicity and protection spleen cells from this toxicity and this is coincided with the decrease in IL-8 and IL-10, because it has been reported that T cells and B cells besides antibody production they can secrete various interleukins as IL-8 and IL-10 (Smolen And Maini, 2006). IL-10 has pleiotropic effects in immunoregulation and inflammation. It enhances B cell survival, proliferation and antibody production (Pestka *et al.*, 2004). Xu stated that in spleen, TiO₂ nanoparticles administration caused an increase in proliferation of local macrophages (Xu *et al.*, 2013). It has been shown that long term exposure to low dose of TiO₂ NPs may cause spleen injury, resulting from alteration of inflammatory and apoptotic cytokines expression and reduction of immune capacity (Shi *et al.*, 2013). Fakurazi, also showed that MOLE accelerated recovery of hepatic cells after intoxicated with TiO₂ NPs. It was evidenced from the histopathological observation; the ability of MOLE to reverse the hepatic lesions was comparable to the treatment with TiO₂ NPs (Fakurazi *et al.*, 2008). A study of Blakely & McDonald revealed that animals pretreated with MOLE were able to prevent further damage by TiO₂ NPs intoxication. The presence of focal infiltration of lymphocytes were observed within 24h and after 48h the damage was reduced to only focal hydropic degeneration (Blakely and McDonald, 1995). Where Hydroethanol extract was thought to contain high phenolic content that may reduce the oxidative stress in spleen tissue (Ferguson, 2001). Certain phenolic compounds may also have induced phase II drug metabolism enzymes that will enhance the excretion of oxidizing species and inhibit cytochrome P450 activities.

Conclusion

In conclusion, based on the above findings, we suggest that ethanolic extract of leaves of *Moringa oleifera* could suppress the cellular and immune response in rat induced by TiO₂ NPs through modulation of cytokines expression and secretion. It may be rewarding to run detailed immunopharmacological studies with this plant to explore its potential as an alternative herbal medicine that could overcome the toxicity problems of allopathic immunosuppressants. The plant-derived

immunomodulators have tremendous potential to be developed as new pharmaceutical products.

Acknowledgement: The author would like to thank all participants for their contribution in this study including animal house technicians and histology technicians.

REFERENCES

- Abou-Raya A, Abou-Raya S 2006. Inflammation: a pivotal link between autoimmune diseases and atherosclerosis. *Autoimmun Rev.*, 5: 331-337.
- Abu El Naga 1989. Synergistic effect of nicotine and radiation exposure on the mammalian embryos. M.Sc. Thesis, Faculty of Science, Al Azhar University.
- Agaie, B. 2004. The role of phytochemicals in optional health. *Journal of the National Academy for Child Development*, 11(1): 27-29.
- Anthony, C. and Allison 2002. Squalane emulsions as adjuvants. *Science Direct*, 19 (1): 87-93.
- Ayuob NN 2013. Can vitamin E and selenium alleviate the immunologic impact of aluminium on pregnant rats' spleens? *Cell Immunol.*, 284: 104-110.
- Balu, M., P. Sangeetha, G. Murali and C. Panneerselvam, 2016. "Modulatory Role of Grape Seed Extract on Age-Related Oxidative DNA Damage in Central Nervous System of Rats," *Brain Research Bulletin*, Vol. 68, pp. 469-473.
- Basaga, H., Poli, G., Tekkaya, C. and Aras, I. 1997. Free radical scavenging and antioxidant properties of silibin complexes on microsomal lipid peroxidation. *Cell Biochem. Funct.*, 15:27-33.
- Blakely P, McDonald BR. 1995. Acute renal failure due to acetaminophen ingestion: A case report and review of the literature. *J Am Soc Nephrol*, 6, 48-53.
- Brender, MD, Erin; Allison Burke, MA, illustrator, Richard M. Glass, MD, editor 2005. "Spleen Patient Page" (PDF). *Journal of the American Medical Association* (American Medical Association) 294 (20): 2660.
- Brynskov J, Foegh P, Pedersen G, Ellervik C, Kirkegaard T, Bingham A, Saermark T 2002. "Tumour necrosis factor alpha converting enzyme (TACE) activity in the colonic mucosa of patients with inflammatory bowel disease". *Gut.*, 51 (1): 37-43.
- Caceres A., Saravia, A., Rizzo, S., Zabala, L., Leon, E.D. and Nave, F. 1992. Pharmacologic properties of *Moringa oleifera*, screening for antispasmodic, anti-inflammatory and diuretic activity. *J. of Ethnopharmacology*, 36(3):233-237.
- Carter, L. and Swain, L. 1997. Single cell analysis of cytokine production. *Curr. Opin. Immunol.*, 9: 177-182.
- Cemerski S, van Meerwijk JP, Romagnoli P 2003. Oxidative-stress-induced T lymphocyte hyporesponsiveness is caused by structural modification rather than proteasomal degradation of crucial TCR signaling molecules. *Eur J Immunol.*, 33: 2178-2185.
- Chaurasia's B.D. 2010. Spleen, Pancreas and Liver in B. D. Chaurasia's Human Anatomy Regional and Applied Dissection and Clinical Volume 2, 5th edn CBS Publishers & Distributors New Delhi Pp. 301-305.
- Chen, J., X. Dong, J. Zhao and G. Tang, 2009. *In-vivo* acute toxicity of titanium dioxide nanoparticles to mice after intraperitoneal injection. *J. Applied Toxicol.*, 29: 330-337. DOI: 10.1002/jat.1414

- Ciric M, Cekic S, Pavlovic V, Jovic Z, Tasic G 2005. Histopathological changes in spleen of rats treated with monosodium glutamate. *Acta Fac. Med. Naiss* 22:191-194.
- Cohen, J.S. and Hogan, M.E. 1994. The new genetic medicines. *Sc.I Am.*, 271:76-82.
- Danz, M., Hartmann, A. and Blaszyk, H. 1998. Mitogenic short-term effects on hepatocytes and adrenocortical cells: phenobarbital and reserpine as compared with carcinogenic and noncarcinogenic fluorine derivatives. *Exp. Toxic. Pathol.*, 50: 416-424.
- Dowlati Y, Herrmann N, Swardfager W, Liu H, Sham L, Reim EK, Lanctôt KL 2010. "A meta-analysis of cytokines in major depression". *Biol Psychiatry*, 67 (5): 446-457. doi:10.1016/j.biopsych.2009.09.033
- Drury, R.A.B. and Wallington, E.A. 1967. Carleton's Histological Technique. 4th ed. Oxford Univ. Press. New-York. Toronto.
- Eid, F. and Al-Dossary, A. 2007. Ultrastructural, histological and histochemical studies on the effect of electromagnetic field on the liver of pregnant rats and their fetuses. *The Egyptian J. of Hospital Medicine*, 28: 273-294.
- Fahey, J.W. 2005. *Moringa oleifera*: A Review of the Medical Evidence for Its Nutritional, Therapeutic, and Prophylactic Properties. Part 1 <http://www.tfljournal.org/article.php/20051201124931586> accessed on 06/04/2012.
- Fakurazi S, Hairuszah I, Nanthini U. 2008. *Moringa oleifera* Lam prevents acetaminophen induced liver injury through restoration of glutathione level. *Food Chem Toxicol*, 46, 2611-2615.
- Ferguson LR. 2001. Role of plant polyphenols in genomic stability. *Mutat Res.*, 475, 89-111.
- Fiorentino, D.F., A. Zlotnik, T.R. Mosmann, M. Howard and A. O'Garra, 1991. IL-10 inhibits cytokine production by activated macrophages. *J. Immunol.*, 147: 3815-3822. PMID: 1940369.
- Flora, K., Hahn, M., Rosen, H. and Benner, K. 1998. Milk thistle (*Silybum marianum*) for the therapy of liver disease. *Am. J. Gastroenterol.*, 93:139-143.
- Gomez-Vargas, A., Rosenthal, K., McDermott, M. and Hortelano, G. 2004. Continuous antigenic stimulation system (CASS) as a new immunization strategy. *Vaccine*, 22:3902-3910.
- Goyal, B.R., Agrawal, B.B., Goyal, R.K. and Mehta A.A 2007. Phyto-pharmacology of *Moringa oleifera* Lam.6 An overview. *Nat Prod Radiance*, 6(4): 347-353.
- Guevara, A.P., Vargas, C., Sakurai, H., Fujiwara, Y., Hashimoto, K., Maoka, T., Kozuka, M., Ito, Y., Tokuda, H. and Nishino, H. 1999). An antitumor promoter from *Moringa oleifera* Lam. *Mutat. Res.*, 440: 181-188.
- Gyton, A.C & Hall, J.E. 2006. Blood cells, immunity and Blood clotting in Textbook of Medical Physiology 11th edn Elsevier Saunders Pennsylvania, pp. 419-428.
- Harold, E. 2006. Abdomen & Pelvis in Clinical Anatomy Applied Anatomy for Students and junior doctor's 11th edn Blackwell Publishing Ltd U.K Pp 104-105.
- Harold, S. 2005. Adjuvants and antibody production: dispelling the myths associated with Freund's complete and other adjuvants. *ILAR Journal*, 46(3): 280-293.
- Heinrich, P.C., I. Behrmann, S. Haan, H.M. Hermanns and G. Müller-Newen *et al.*, 2003. Principles of interleukin-6-type cytokine signalling and its regulation. *Biochem. J.*, 374: 1-20. PMID: 12773095.
- Hoet, P.H., I. Brske-Hohlfeld and O.V. Salata, 2004. Nanoparticles-known and unknown health risks. *J. Nanobiotechnol.*, 2: 12. DOI: 10.1186/1477-3155-2-12
- Hotchkiss, R.D. 1948. A microchemical reaction resulting in the staining of Polysaccharides structures in fixed tissue preparations. *Arch. Biochem.*, 16: 131-44.
- Jahn, S.A.A. 1988. Monitored water coagulation with *Moringa oleifera* seeds in village household. *Journal of Analytical Science*, 1: 40-41.
- Kanterman J, Sade-Feldman M, Baniyash M 2012. new insights into chronic inflammation-induced immune suppression. *Semin Cancer Biol.*, 22: 307-318.
- Khaki, A., Tubbs, R., Shoja, M., Rad, J., Khaki, A., Farahani, R., Zarrintan, S. and Nag, T. 2006. The effects of an electromagnetic fields on the boundary tissue of the seminiferous tubules of the rat: A light and transmission electron microscope study. *Folia. Morphol.*, 65(3): 188-194.
- Kiernan, J.A. 2007. Immunohistochemical staining of inflammation and an artifact. *Biotech Histochem.*, 82: 273-274.
- Kim MS, Yi JM, Kim SH, Hong SH, Kim HM 2004. Madimadi, Korean folk medicine, blocks TNF-alpha, IL-1beta, and IL-8 production by activated human immune cells. *Cytokine*, 25: 179-186.
- Linglan, M.A., J. Zhao, J. Wang, J. Liu and Y. Duan *et al.* 2009. The acute liver injury in mice caused by nano-anatase TiO₂. *Nanoscale Res. Lett.*, 4: 1275-1285. DOI: 10.1007/s11671-009-9393-8.
- Liu C, Li M, Cao Y1, Qu JP1, Zhang ZW1, *et al.* 2014. Effects of avermectin on immune function and oxidative stress in the pigeon spleen. *Chem Biol Interact*, 210: 43-50
- Locksley RM, Killeen N, Lenardo MJ. 2001. "The TNF and TNF receptor superfamilies: integrating mammalian biology". *Cell*. 104 (4):487-501. doi:10.1016/S0092-8674 (01) 00237-9.
- Maize D, Brewer PA, Affert M. 1953. The cytochemical staining and measurements of protein with mercuric bromophenol blue. *Bid Bull.*, 104: 57-67.
- Martin KR, Kari FW, Barrett JC, French JE 2000. N-acetyl-L-cysteine simultaneously increases mitogenesis and suppresses apoptosis in mitogen-stimulated B-lymphocytes from p53 haploinsufficient Tg.AC (v-Ha-ras) mice. *In Vitro Mol Toxicol* 13: 237-248.
- Mebius, RE; Kraal, G 2005. "Structure and function of the spleen". *Nature reviews. Immunology*, 5 (8): 606-16.
- Medina, C., M.J. Santos-Martinez and A. Radomski, 2007. Nanoparticles: pharmacological and toxicological significance. *Br. J. Pharmacol.*, 150: 552-558. PMID: 17245366
- Melamed, R., Bar-Yosef, S., Shakhar, G., Shakhar, K. and Ben-Eliyahu, S. 2003. Suppression of natural killer cell activity and promotion of tumor metastasis by ketamine, thiopental, and halothane, but not by propofol: mediating mechanisms and prophylactic measure. *Anesth. Analg.*, 97: 1331-1339.
- Monica premi, H. K, Sharma, B., C. Sarkar and C. Singh. 2010. Kinetics of drumstick leaves (*Moringa oleifera*) during convective drying. *African Journal of Plant Science*, Vol. 4 (10): 391-400.
- Moore, K. L., Dally, A. F. and Agur, A. M. R. 2010. Abdomen in Clinically Oriented Anatomy 6th edn, Lippincott & Wilkins Publishers U.S.A Pp 263-264.
- Moore, K.W., M.R. de Waal, R.L. Coffman and A. O'Garra, 2001. Interleukin-10 and the interleukin-10 receptor. *Annu. Rev. Immunol.*, 19: 683-765. PMID: 11244051.

- Newman, D.J., Cragg, G.M. and Snader, K.M. 2000. The Influence of Natural Products upon Drug Discovery. *Natural Product Report*, 17: 215-234
- Pestka, S., C.D. Krause, D. Sarkar, M.R. Walter and Y. Shi *et al.* 2004. Interleukin-10 and related cytokines and receptors. *Annu. Rev. Immunol.*, 22: 929-979. PMID: 15032600.
- Recordati, C., De Maglie, M., Bianchessi, S., Argentiere, S., Cella, C., Mattiello, S., Cubadda, F., Aureli, F., D'Amato, M., Raggi, A., Lenardi, C., Milani, P., Scanziani E. 2016. Tissue distribution and acute toxicity of silver after single intravenous administration in mice: nano-specific and size-dependent effects. *Part. Fibre Toxicol.*, 13, 12.
- Roman-Ramos R, Almanza-Perez JC, Garcia-Macedo R, Blancas-Flores G, Fortis-Barrera A, *et al.* 2011. Monosodium glutamate neonatal intoxication associated with obesity in adult stage is characterized by chronic inflammation and increased mRNA expression of peroxisome proliferator-activated receptors in mice. *Basic Clin Pharmacol Toxicol.*, 108: 406-413.
- Sadauskas, E., H.Wallin, M.Stoltenberg, U.Vogel and P. Doering *et al.* 2007. Kupffer cells are central in the removal of nanoparticles from the organism. *Particle Fibre Toxicol.*, 4: 10-10. PMID: 17949501.
- Sang, X.Z., L. Zheng, Q.Q. Sun, T.Zhang and N. Li *et al.*, 2012. The chronic spleen injury of mice following exposure to titanium dioxide nanoparticles. *J. Biomed. Mater. Res., Part A*, 100: 894-902. PMID: 22275130.
- Shi, H., R. Magaye, V. Castranova and J. Zhao, 2013. Titanium dioxide nanoparticles: A review of current toxicological data. *Part Fibre Toxicol.*, 10: 15-15. DOI: 10.1186/1743-8977-10-15.
- Smolen, J.S. and R.N. Maini, 2006. Interleukin-6: A new therapeutic target. *Arthritis Res. Ther.*, 8: S5-S5. PMID: 16899109.
- Swardfager W, Lanctôt K, Rothenburg L, Wong A, Cappell J, Herrmann N 2010. "A meta-analysis of cytokines in Alzheimer's disease". *Biol Psychiatry*, 68 (10): 930–941. doi:10.1016/j.biopsych.2010.06.012.
- Swirski, FK; Nahrendorf, M; Etzrodt, M; Wildgruber, M; Cortez-Retamozo, V; Panizzi, P; Figueiredo, JL; Kohler, RH; Chudnovskiy, A; Waterman, P; Aikawa, E; Mempel, TR; Libby, P; Weissleder, R; Pittet, MJ 2009.
- Szelényi J 2001. Cytokines and the central nervous system. *Brain Res Bull.*, 54: 329-338.
- Victor FC, Gottlieb AB 2002. "TNF-alpha and apoptosis: implications for the pathogenesis and treatment of psoriasis". *J Drugs Dermatol.*, 1 (3): 264–75
- Viera, S. 2001. Adverse effects of adjuvants in vaccines. *Whale*, 8(2): 1-11.
- Wang, J., G. Zhou, C. Chen, H. Yu and T. Wang *et al.* 2007. Acute toxicity and biodistribution of different sized titanium dioxide particles in mice after oral administration. *Toxicol. Let.*, 168: 176-185. PMID: 17197136
- Xu, J., H. Shi, M. Ruth, H. Yu and L. Lazar *et al.*, 2013. Acute toxicity of intravenously administered titanium dioxide nanoparticles in mice. *Plos One*, 8: e70618-e70618. PMID: 23950972.
- Xue, C., W. Liu, J. Wu, X.Yang and H. Xu, 2011. Chemoprotective effect of N-Acetylcysteine (NAC) on cellular oxidative damages and apoptosis induced by nano titanium dioxide under UVA irradiation. *Toxicol. Vitro*, 25: 110-116. PMID: 20932892
- Yee, S. and Choi, H. 1996. Oxidative stress in neurotoxic effects of methylmercury poisoning. *Neurotoxicology*, 17: 17-26.
