



## CASE STUDY

### MIGRATED IUCD CAUSING UNILATERAL OBSTRUCTIVE HYDROURETERONEPHROSIS & NON-FUNCTIONING KIDNEY - A RARE PRESENTATION

**\*Gurmeet Singh, Alok Srivastava and Sanjeet Singh**

Dr RML Institute of Medical Sciences

#### ARTICLE INFO

##### Article History:

Received 24<sup>th</sup> September, 2016  
Received in revised form  
22<sup>nd</sup> October, 2016  
Accepted 05<sup>th</sup> November, 2016  
Published online 30<sup>th</sup> December, 2016

##### Key words:

Migrated IUCD,  
Laparoscopic Nephrectomy.

#### ABSTRACT

Intrauterine contraceptive device is commonly used method of contraception worldwide. IUCD insertion though a very safe method may be associated with complications. The present case report is about a 42-year-old female with recurrent dysuria. Investigations revealed hydronephrosis with non-functioning kidney due to migrated IUCD in abdominal cavity leading to extramural compression of left ureter. Migration of IUCD is a known complication but migration leading to compression of ureter leading to non-functioning of kidney.

Copyright©2016, Gurmeet Singh et al. This is an open access article distributed under the Creative Commons Attribution License, which permits unrestricted use, distribution, and reproduction in any medium, provided the original work is properly cited.

Citation: Gurmeet Singh, Alok Srivastava and Sanjeet Singh, 2016. "Migrated iucd causing unilateral obstructive hydronephrosis & non-functioning kidney - A rare presentation", *International Journal of Current Research*, 8, (12), 44356-44358.

## INTRODUCTION

Intrauterine contraceptive devices (IUCDs) are commonly used forms of contraception worldwide. However, migration of the IUCD from its normal position in the uterine fundus is a frequently encountered complication, varying from uterine expulsion to displacement in the endometrial canal to uterine perforation. Complete uterine perforation, in which the IUCD is partially or completely within the peritoneal cavity, requires surgical management (Boortz et al., 2012). Urological complications due to IUCD migration have been reported in literature (Farouk, 2007). The radiologist plays an important role in the diagnosis of IUCD migration and should be familiar with its appearance at multiple imaging modalities. In the literature, there is one reported case of IUCD piercing the myometrium & compressing the closely coursing right ureter causing Hydronephrosis & Hydroureter (Sharifiaghdas, 2007). To our knowledge, there are no reported cases of complete retroperitoneal migration of IUCD causing unilateral hydronephrosis leading to non-functioning of that kidney at the time of reporting this case. This case report describes urinary tract obstruction secondary to migrated/displaced IUCD.

## Case Report

A 42 years old female patient presented with off & on left loin pain and recurrent dysuria for the past 2 years. She was on antibiotics, NSAIDs and spasmolytics but pain remained persistent. Her past history was negative for any renal stone disease. She reported to have an IUCD placement 4 years back from a trained gynecologist. She was advised an ultrasound examination of the abdomen and pelvis, which revealed moderate left hydronephrosis and left hydroureter traceable till middle one-third. No calculus could be detected within the dilated system.

She subsequently reported again for a CT urography which revealed a radiopaque T-shaped IUCD had migrated with left limb of Copper-T migrating upto left fallopian tube and compressing the closely coursing left ureter resulting in small, moderately hydronephrotic left kidney with no parenchyma and left hydroureter. DTPA scan was done which revealed non-functioning left kidney. A per-op Retrograde ureterogram confirmed these findings (Figure 2). Laparoscopic left simple nephrectomy was planned. Perop findings revealed a small hydronephrotic left kidney with ureter dilated upto mid 1/3 with dense adhesions and a lump formed by left ureter, left ovary and left fallopian tube causing extramural obstruction of left ureter.

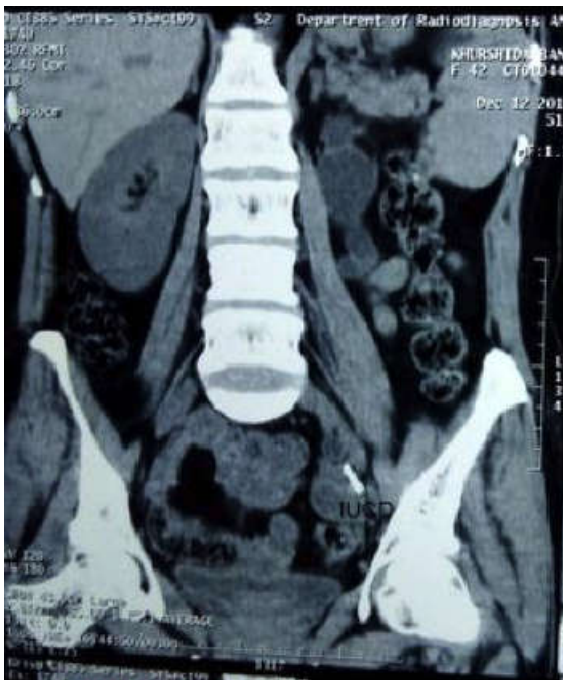


Fig. 1. CT scan showing IUCD migrated into peritoneal cavity

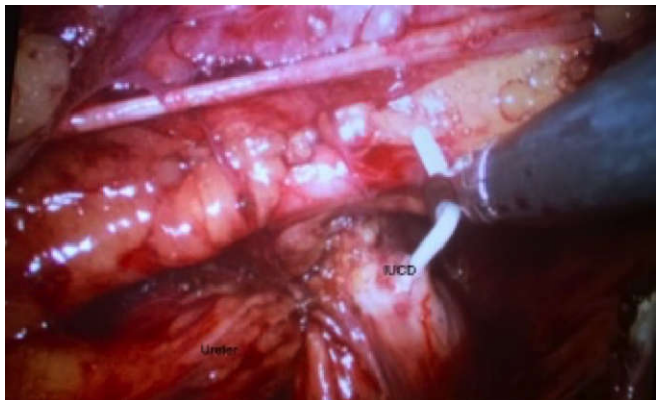


Fig. 2. Laparoscopic view of IUCD causing extramural compression of ureter

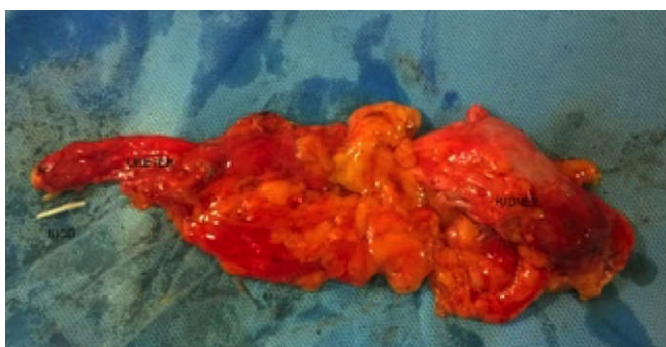

Fig 3. Specimen showing LEFT KIDNEY, URETER & IUCD

## DISCUSSION

Intrauterine contraceptive device (IUCD) has been widely used since 1965. It is the most popular method of reversible contraception in developing countries due to its high efficacy & low cost, with millions of women using it world wide (Nouira, 2007). Its efficacy is close to tubal ligation with added benefit of the ease of reversal. Regular self-examination for “missing threads” is useful for early detection of a migrated IUCD. Associated complications of an IUCD are bleeding,

infection, ectopic pregnancy, septic abortion and uterine perforation with partial or complete migration of the IUCD into adjacent structures e.g. peritoneum, appendix, colon, wall of iliac vein and urinary bladder. These displaced devices have been incriminated for perforation of surrounding viscera (Manan et al., 2001 and Yeni, 2002). The urological complications reported in literature include partial and complete vesical migration and stone formation, ureteric calculus formation and obstruction, acute and chronic pyelonephritis, persistent lower urinary tract symptoms (LUTS) and vesico-uterine fistula (El-Hefnawy, 2008). Intravesical migration of the IUCD is exceptionally rare but it must be kept in mind in women with recurrent urinary symptoms using the contraceptive devices (Manan, 2001). D Derevianko IM and colleagues report a series of 64 cases of IUCD presenting with urological complications but none of the IUCDs in this study had migrated outside or perforated the adjoining viscera (Derevianko, 1997). Extra uterine migration of the device has been reported as early as one week to as late as 18 years after insertion. How and when migration into urinary bladder occurs is unclear.

The mechanism of bladder perforation is either primary i.e. at the time of insertion or secondary by slow migration across the walls of uterus & bladder. Most of the perforations take place at the time of insertion and go unnoticed. Delayed onset of symptoms support secondary migration (Manan, 2001 and El-Hefnawy, 2008). Detection of expulsion or displacement should be immediately communicated to the patient and her healthcare provider, since they can lead to decreased contraceptive efficacy and may require further management. Embedment of an IUCD in the myometrium may necessitate intervention in the outpatient clinical setting and warrants communication of this finding to the referring clinician, as well as clear documentation in the radiology report. Patients with an uncomplicated perforation will likely undergo laparoscopic removal of the IUCD. Early surgical intervention appears to decrease the likelihood of adhesion formation, thereby making laparoscopic removal easier. Emergent surgical intervention should be guided by the patient's clinical presentation, supplemented by findings at cross-sectional imaging performed to detect serious intra-abdominal complications. Insertion of IUCD necessitates regular follow-up to confirm its correct position. Displaced IUCD should therefore, be included in the differential diagnosis in any patient having hydronephroureter and who gives history of IUCD placement.

## REFERENCES

- Boortz, H.E., Margolis, D.J.A., Ragavendra, N. et al. 2012. Migration of intrauterine contraceptive devices: radiologic findings and implications for patient care. *Radiographics* 2012; 32: 335-52.
- Derevianko, I.M., Derevianko, T.I., Ryzhkov, V.V. 1997. The urological complications of contraception using intrauterine coils. *Urolnefrol (Mosk)*, 5: 27-30.
- El-Hefnawy, A.S., El-Nahas, A.R., Osman, Y. et al. 2008. Urinary complications of migrated intrauterine contraceptive device. *Int Urogynecol J Pelvic Floor Dysfunct.*; 19:241-5.
- Farouk, K., Afridi, Z., Farooq, M.A. et al. 2007. Urological complications of intrauterine contraceptive devices. *JPMI2007*; 21: 260-65.

- Manan, A., Andhikari, D.B., Chugtai, M.N. 2001. Intravesical migration of intrauterine contraceptive device. *J Nepal Med Assoc.*, 40: 215-6.
- Nouira, Y., Rakrouki, S., Gargouri, M. et al. 2007. Intravesical migration of intrauterine contraceptive device complicated by bladder stones: A report of six cases. *IntUrogynecol J*, 18: 575-8.
- Sharifiaghdas, F., Beigi, F. M., Abdi, H. 2007. Laparoscopic Removal of a Migrated Intrauterine Device. *Urol J*. 4: 177-9.
- Yeni, E., Unal, D., Verit, A. 2002. Migration of intrauterine device as a cause of bladder stone. *Brazil J Urol*. 28: 43-4.

\*\*\*\*\*