



ISSN: 0975-833X

## CASE STUDY

# MULTIROOTED TOOTH GUIDED IMMEDIATE IMPLANT PLACEMENT IN MOLAR SITES: A REPORT OF TWO CASES

\*<sup>1</sup>Dr. Vaibhav Joshi, <sup>1</sup>Dr. Varun Suhag and <sup>2</sup>Dr. Shalini Gupta

<sup>1</sup>Department of Periodontics and Oral Implantology, Santosh Dental College, Ghaziabad

<sup>2</sup>Private Practitioner, Ghaziabad

### ARTICLE INFO

#### Article History:

Received 14<sup>th</sup> October, 2016

Received in revised form

22<sup>nd</sup> November, 2016

Accepted 08<sup>th</sup> December, 2016

Published online 31<sup>st</sup> January, 2017

#### Key words:

Immediate implant,  
Implant bed preparation,  
Interradicular bone septa.

### ABSTRACT

Post extraction immediate implant placement in multirooted molar area is a challenging task in view of anatomical limitations of the socket and in achieving primary stability after ideal placement of the implant along the interradicular septa. The aim of this article is to present a technique of tooth guided implant site preparation for immediate implant placement in multirooted molar areas. Coronal portion of the concerned tooth was reduced to the level of marginal gingiva, osteotomies were performed using centre of the remaining tooth root complex as the reference point and the implant bed is prepared engaging the interradicular septa. The remaining tooth root complex after complete implant site preparation is atraumatically removed and the fixture is placed directly in the prepared implant site thus allowing the precise placement with proper angulation. This technique helps the surgeon in ideal implant positioning in immediate implant placement cases as it prevents slipping of the drills in mesial or distal root sockets during initial osteotomies and allows stabilized and guided implant placement.

Copyright©2017, Vaibhav Joshi et al. This is an open access article distributed under the Creative Commons Attribution License, which permits unrestricted use, distribution, and reproduction in any medium, provided the original work is properly cited.

Citation: Dr. Vaibhav Joshi, Dr. Varun Suhag and Dr. Shalini Gupta, 2017. "Multirooted tooth guided immediate implant placement in molar sites: A report of two cases", *International Journal of Current Research*, 9, (01), 44967-44969.

## INTRODUCTION

Post extraction immediate implant placement in multirooted molar area involves anatomical challenges due to weak inter-radicular bone. Original protocols required the placement of implants into healed edentulous ridges. In 1989, Lazzara (1989) placed implants at the time of tooth extraction. The concept of immediate implant placement has continuously gained attention in scientific as well as clinical dentistry as it offers a number of advantages compared to conventional implant treatment, the first and foremost being a reduction of surgical interventions in combination with shorter treatment time. Today, Immediate implants achieve survival rates comparable to those of delayed implants placed in healed sites (Joshi *et al.*, 2015; Quirynen *et al.*, 2007). Challenges associated with immediate implant placement in multirooted mandibular molar sites include-precise three dimensional placement of implant along the interradicular septa and to achieve primary stability (Atieh *et al.*, 2010). The socket anatomy and the jumping distance i.e the space between the implant and the socket wall are also the relevant factors for the successful outcome of the procedure (Chen *et al.*, 2009). Implant site preparation in the presence of interradicular bone septa may also prove challenging. The aim

of this article is to present a technique that gives improved guidance during implant site preparation for immediate placement in multirooted molar extraction Sites.

### Case reports

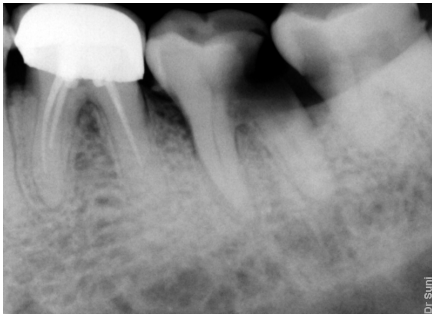
#### Patient 1

A 73 years old patient with a noncontributory medical history presented with deep carious lesion in mandibular left second molar which is impossible to restore with a crown (Fig.1). The patient opted for the removal of the hopeless tooth and restoration with an implant-supported prosthesis. Patient's consent was taken. Following local anesthesia, coronal reduction of the second molar was done upto the level of gingival margin. Pilot osteotomy was initiated at the centre of the tooth root complex without raising the flap (Fig.2). Interradicular implant bed preparation is done before extraction (Fig.3). Osteotomy was extended beyond the fundus of the socket to gain maximum interradicular bone support for primary stability in compliance with pre-operative radiographic assessment. After that all subsequent osteotomies have been performed through the center of the existing tooth and its roots (Fig.4). Then both roots were removed using a periosteal elevator ensuring a minimally traumatic extraction. The extraction socket was thoroughly curetted and a dental implant of size 4.5×11.5 mm was inserted (Fig.5).

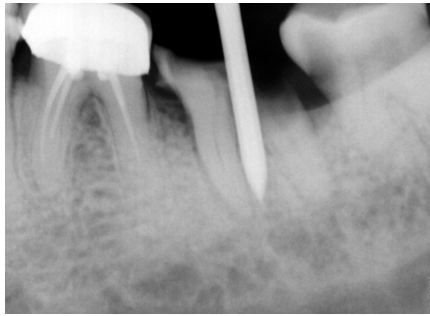
\*Corresponding author: Dr. Vaibhav Joshi,

Department of Periodontics and Oral Implantology, Santosh Dental College, Ghaziabad

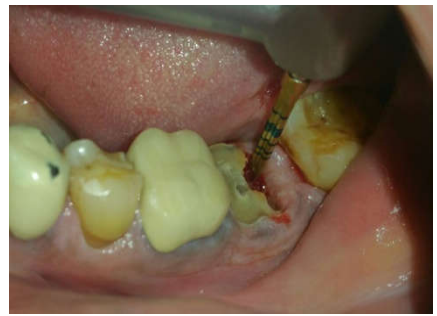**CASE I**



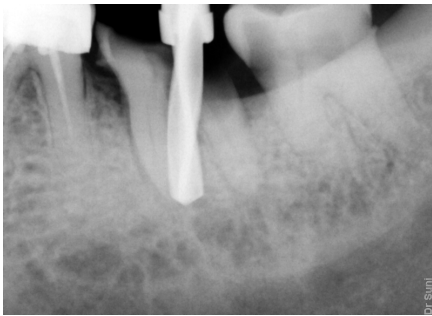
**Fig. 1. Pre-Operative IOPA X-ray**



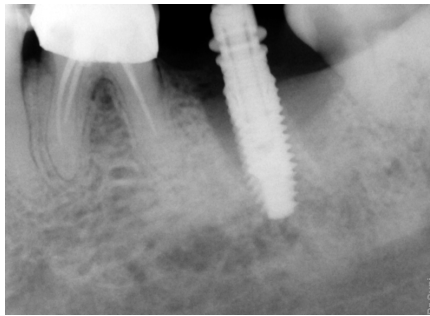
**Fig. 2. IOPA X-ray depicting pilot drill through the tooth's initially retained root complex**



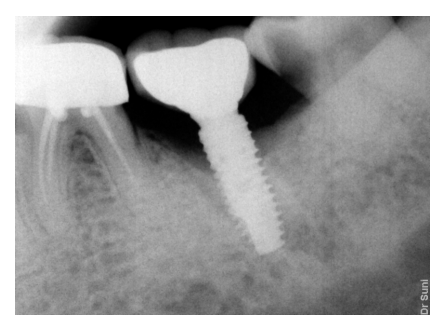
**Fig. 3. Clinical view showing pre extractive Inter-radicular implant bed preparation**



**Fig. 4. Subsequent drill placement**

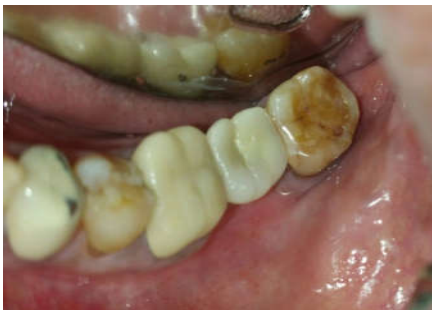

**Fig. 5. Final implant placement**

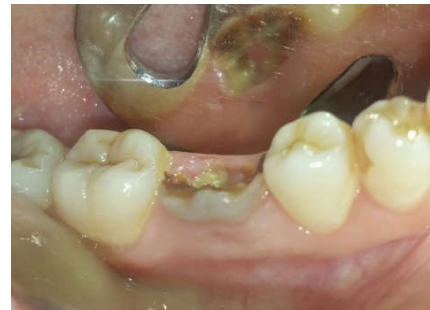

**Fig. 6. Radiograph taken after placement of the definitive restoration**

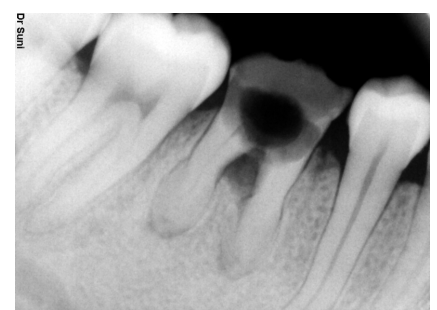**CASE II**



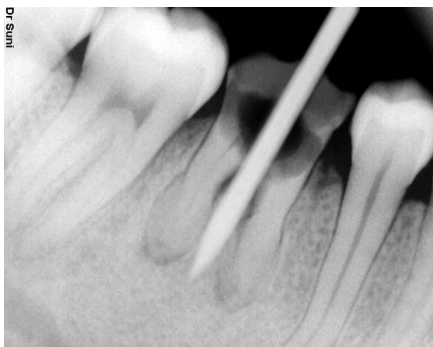**Fig. 7. Definitive implant crown placement**



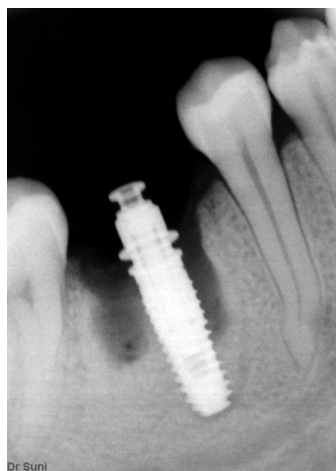**Fig. 8. Pre-Operative**



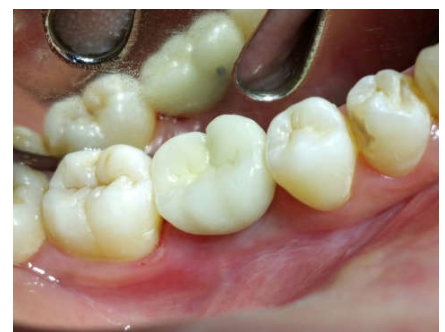**Fig. 9. Pre -operative IOPA X ray**



**Fig. 10. The pilot drill placed through the tooth's initial retained root complex**



**Fig. 11. Final implant placement**



**Fig. 12. Definitive implant crown placement**

Adequate insertion torque and sufficient primary stability allowed for a nonsubmerged healing approach and a cover screw was placed. Sutures were placed to approximate wound margins. Post operative instructions were given with proper antibiotic coverage. The sutures were removed after two weeks. Four months after the surgical intervention, the patient presented with healthy peri implant tissue condition and the prosthetic treatment was completed. Healing abutment was placed. Final impressions were taken and porcelain fused to metal crown served as the definitive restoration (Fig.6,7).

## Patient 2

A 26 years old patient complaints of carious tooth in right lower back jaw region (Fig.8,9). Medical history was not significant. The treatment plan called for immediate implant placement in right lower first molar after extraction of the hopeless tooth. Pre extractive interradicular implant bed preparation was performed according to the aforementioned protocol (Fig.10). After completion of the drilling process pre extractive implant bed was prepared. The retained root aspects guided the osteotomy drills and the retained root pieces were removed. Socket was curetted and dental implant of size 4.0×10mm was placed (Fig.11). Sutures were given. Postoperative regimen was the same as described for the first patient. After two weeks sutures were removed and patient was called for second stage. Healing was uneventful. Following successful osseointegration of the implant, the prosthetic treatment was completed during second stage (After 4 months) with porcelain fused to metal crown placed as definitive restoration (Fig.12).

## DISCUSSION

The case presentations in this article demonstrate an approach that allowed for improved guidance during implant bed preparation for immediate implants at multirooted molar sites. This technique helps in better stabilisation and guidance of osteotomy drills supported by retained roots and allows for precise three dimensional positioning of implant using maximum interradicular bone septa support at multirooted extraction sites. With proper patient selection and accurate clinical procedures, immediate implants perform predictably well and achieve success rates that are comparable to those of delayed implants placed in healed sites. Atieh *et al.* (2010) published a review on survival rates of immediate implants after evaluating data of 1013 implants in nine studies and reported a survival rate of 93.9% to 100% over an observation period of upto 11 years. Lang *et al.* (2012) in another review also reported high survival rates for implants placed in posterior mandibular region. Ideal three dimensional implant placement is significant in successful outcome of the procedure. (Lang and Berglundh, 2011) Interradicular bone septa causes slipping of drills in mesial or distal sockets and may hamper precise implant placement at multirooted molar sites, Pre extraction tooth root guided osteotomy and implant bed preparation proves better alternative to counteract this clinical difficulty. (Stephan *et al.*, 2013) The retained roots

guided the drills along the interradicular bone without slipping and allows stabilized and guided implant placement after atraumatic removal of both the roots. Moreover when this technique is applied the initially retained root complex serves as an ideal template for the emergence profile of the tooth to be replaced. The clinical application of this technique may raise concern about the risk of a deleterious reaction caused by drill debris displaced in the socket or in the osteotomy. Therefore it is recommended to thoroughly curette and debride the site prior to insertion of the implant. Adequate insertion torque and sufficient primary implant stability allowed for nonsubmerged healing in this case. This may be due to the support by the interradicular bone that is usually preserved in the lateral aspects of osteotomy hole, so the bone apical to the socket fundus is not the only factor for implant stability. Both implants showed successful osseointegration after uneventful healing period of 4 months.

## Conclusion

This technique of implant bed preparation allows stabilized and guided implant placement and helps in ideal three dimensional implant positioning. This is an uncomplicated and useful modification of the standard approach of immediate implant placement at multirooted molar extraction sites.

## REFERENCES

- Atieh MA, Payne AG, Duncan WJ, de silva RK, Cullinan MP. 2010. Immediate placement or immediate restoration/ loading of single implants for molar tooth replacement; a systematic review and meta analysis. *Int J Oral Maxillofac Implants*, 25:401-415.
- Chen ST, Darby IB, Reynolds EC, Clement JG. 2009. Immediate implant placement postextraction without flap elevation. *J Periodontol.*, 80:163-172
- Joshi V *et al.* 2015. Immediate Implant Placement in Aesthetic zone-CBCT Analysis. *Journal of International Oral Health*, 7(Suppl 2): 99-102.
- Lang NP. and Berglundh T. 2011. Periimplant diseases. Where are we now? Consensus of the seventh European workshop on periodontology. *J Clin Periodontol*, 38(suppl-11):78-181.
- Lang NP, Pun L, Lau KY, Li KY, Wong MC. 2012. A systematic review on survival and success rates of implants placed immediately into fresh extraction sockets after atleast 1 year. *Clin Oral Implants Res.*, 23(suppl 5):9-66.
- Lazzara RJ. 1989. Immediate implant placement into extraction sites: surgical and restorative advantages. *Int J Periodontics Restorative Dent*, 9: 332-343.
- Quirynen M, Van Assche N, Botticelli D, Berglundh T. 2007. How does the timing of implant placement to extraction affect outcome? *Int J Oral Maxillofacimplants*, 22(suppl); 203-223.
- Stephan F. Rebele, Otto Zuhr, Markus B. Hurzeler. 2013. Pre extractive interradicular implant bed preparation; novel approach to immediate implant placement at mutirooted molar sites. *Int J Periodontics Restorative Dent*, 33:88-95.

\*\*\*\*\*