



RESEARCH ARTICLE

POTENTIAL ALTERNATIVE TO FORMALDEHYDE FIXATIVES - A STUDY

*Ashika Rachael Samuel and Dr. Gheena

Department of General Pathology, Saveetha Dental College and Hospitals

ARTICLE INFO

Article History:

Received 20th November, 2016

Received in revised form

16th December, 2016

Accepted 02nd January, 2017

Published online 28th February, 2017

Key words:

Sodium nitrite,
Tissue fixation.

ABSTRACT

Aim: The aim of this study is to find a potential alternative that can be used in place of the regular fixatives.

Materials and Method: In this study, we will use sodium nitrite as a fixative. 5 samples of the tissue overlying the extracted teeth will be used. 30g, 35g, 40g, 45g and 50g of sodium nitrite were the concentrations.

Background: Fixation is the foundation step behind the study of pathology and essentially exists to prevent the autolysis and degradation of the tissue and tissue components such that they can be observed both anatomically and microscopically following sectioning. The broad objective of tissue fixation is to preserve cells and tissue components in a "life-like state". Sodium nitrite has been found to inhibit growth of disease-causing microorganisms; give taste and color to the meat; and inhibit lipid oxidation that leads to rancidity. The study was carried out in 2016 using 40g, 50g, 60g and 80g of sodium nitrite in 100 ml of water. 40g sodium nitrite showed the best fixation properties among the other concentrations. Even 60g showed significant results. However in the experimental study we chose concentrations around 40g.

Conclusion: An innovative Method to detect the effectiveness of a new salt like sodium nitrite as a fixative in place of the usual toxic Formalin.

Copyright©2017, Ashika Rachael Samuel and Dr. Gheena. This is an open access article distributed under the Creative Commons Attribution License, which permits unrestricted use, distribution, and reproduction in any medium, provided the original work is properly cited.

Citation: Ashika Rachael Samuel and Dr. Gheena. 2017. "Potential alternative to formaldehyde fixatives - A study", *International Journal of Current Research*, 9, (02), 46795-46799.

INTRODUCTION

Histology is a microscopic study in which tissue samples from animals and humans are studied. The main purpose of histology is due to its ability to contribute accurate information in forensic sciences, autopsy, diagnosis and education (Black, 2012). The histological staining procedure includes five steps, fixation, processing, embedding, sectioning and staining (Titford, 2009). Among these steps, the first step FIXATION aims at preserving the tissue structure and cell integration from degradation. This occurs due to the cross linking proteins of the fixatives. (Young, 2010). The most common fixative used is Formalin (Black, 2012). It has been noticed that formalin may be oxidised in the presence of oxygen leading to the formation of Formic acid. This may interfere while fixing the blood rich tissue specimens and form "formalin pigment". (Lillie, 1947 and Walker, 1964). The other known fixatives are neutral buffered formalin (NBF), paraffin-formalin, Bouin fixative etc. (Musumeci, 2014 and Lillie, 1947).

However the major drawback noticed is that, these fixatives lead to the denaturation of the proteins in the sample tissue rendering them dysfunctional (Young, 2010). Thus here arises the need to identify an alternative fixative that can perform similar function to formalin but eliminate its drawback and produce high efficiency results. It's has been found that sodium nitrite can serve for this purpose. Nitrites have commonly been used in curing of meat. This curing will prevent the meat from becoming rancid (Bryan, 2015). It also protects food against botulinum toxin and preserves its form (Nigam, 2010), As nitrates have the capacity to preserve the form and structure of the food, its application in the field of histology has been studied. Thus sodium nitrate has been experimented with to understand its fixative strength.

MATERIALS AND METHODS

For the study, sodium nitrite powder was mixed in 100 ml of distilled water in varying concentrations ranging from (30g,35g,40g,45g and 50g) and stored in uricol containers. These concentration values had been chosen following the pilot study (2016) of sodium nitrite solution with soft tissue

*Corresponding author: Ashika Rachael Samuel

Department of General Pathology, Saveetha Dental College and Hospitals

for 48 hours was conducted with concentrations 40g, 50g, 60 g and 80 g. It was observed that the 40 and 60g concentration was the most suitable concentration for the study. Concentrations of 30g, 35g, 40g, 45g and 50 g were selected. Mucosal tissue samples were collected from the extracted teeth. The size of each tissue was approximately 5*5 mm. One sample had been stored in the standard fixative solution – formalin. Previously in 2016, the first pilot study was based on an experimental study done with meat chunks kept under observation for 48 hours in sodium nitrite solution dissolved in 100 ml of distilled water. The concentrations chosen were 10 g, 30g, 45g, 60 g and 80 g. From these concentrations it was seen that the container with 10 g concentration showed the least fixation. The meat appeared very soft. It was observed that the container with the maximum concentration (80g) showed excellent fixation property. The specimen appeared normal in consistency and had not much change in its structure. Thus choosing this concentration, the study has been carried out with a few other experimental values to attain maximum accuracy in the result. The tissue samples were collected from the extracted teeth.

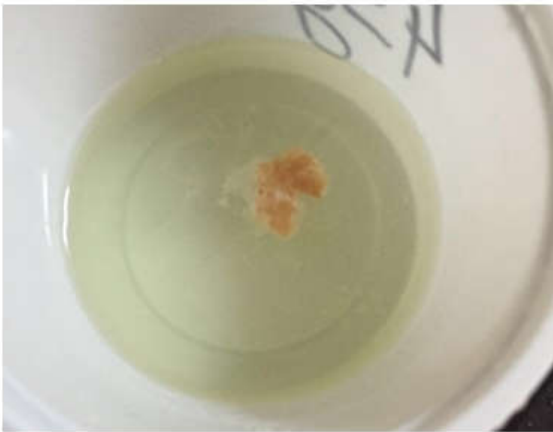

Fig. 1. Pilot study with meat chunk in 45 g concentration of sodium nitrite in distilled water

RESULTS

From the pilot study we proved that sodium nitrite has good fixative properties, particularly the 40 and 60 g concentrations. The effectiveness of the fixative also depends on the size of the tissue to be fixed. However the consequent study show that the fixation was best appreciated with 45g.

DISCUSSION

The primary objective of fixation is to prevent all the degenerative processes that occur once the tissue is deprived of the blood supply. The tissue ingestion that occurs due to the release of micro organisms due to rupture of outer membrane leads to autolysis. This phenomenon is greatly reduced by the properties of fixation. Further more, the other steps in histochemical procedure where the tissue is subjected to various chemicals and waxes need to be protected against any form of damage. Fixation aids in this aspect and protects the tissue (Drury, 1980 and Eltoun, 2001). Despite all the advantages, it is also noted that the fixative can cause some preliminary changes to the tissue like shrinkage, swelling, hardening etc when subjected to an aqueous environment. Even during processing, there may be some morphological changes in the non aqueous environment (Eltoun, 2001).

There are two main types of Fixation - chemical and physical means. Physical fixation includes heating, microwaving and cryo- preservation. Heat fixation is now replaced by micro wave techniques. Cryo - preservation refers to freeze drying and it is not applicable to the diagnostic tissue specimens (Eltoun, 2011). The chemical methods include perfusion and immersion techniques. In general, a fixative is a single agent dissolved in a particular solvent or it may be due to the combination of one or more agents (Leong, 1994). The most widely accepted fixatives are formalin. It is prepared by diluting one part of formalin in nine parts of water as a buffer. It is accepted that washing of the tissue specimens with formalin can reverse some reactions however the cross links will still remain the same (Eltoun, 2001). Another main advantage of formalin is its ability to preserve the peptide in the cellular proteins (NTP, 2011).

The formalin also reacts with lysine, tyrosine, threonine, serine, glutamine and others to form a cross links. These cross links are responsible for maintenance of the tissue in its normal physiological state (Eltoun, 2001). Though formalin serves to be so advantageous, it is highly hazardous to man. Its entry into the body through the eye, skin or respiratory tract can be very harmful to man. It may cause irritation, corrosion or allergy to man. Many studies have proved formalin to be carcinogenic to man kind. Common cancers caused are nasopharyngeal cancer, sinonasal cancer, myeloid leukaemia (Rolls, 1994). Some undesired effects are also seen with the fixation. The formalin may undergo oxidation reaction and form Formic acid resulting in fall in pH. This Formic acid will react with the haemoglobin and form a new compound, acid formaldehyde haemoglobin. This is a brown black granular pigment which gets deposited on the blood rich tissues. It is often misinterpreted as a micro organism or pigment (Rolls, 1994). Thus due to the above reasons, alternatives to formalin have come into use. Mostly used alternatives are glutaraldehyde and genipin. Glutaraldehyde possesses equivalent functions as formalin. The cross linking of glutaraldehyde are highly irreversible (Bozzola, 1992). The glutaraldehyde slowly degrades to glutaric acid which enables the conversion of a cyclic compound to an oligomeric compound. When this fixative is used for electron microscopy as a primary fixator, a secondary fixation is done with osmium tetroxide (Bozzola, 1992). Genipin is a naturally occurring fixative. It acts with the amino acids and converts it into a blue compound. It is believed that the use of this fixative on tissue builds its resistance collagenase degradation.

However, its action on nucleic acid is yet to be proven (Sung, 2000). In the pilot study, the soft tissue samples that were collected from the tooth extraction cases and were fixed using sodium nitrite for 48 hours. The samples were carefully observed for any kind of physical change. The tissues were soft in consistency. After fixation was complete, the tissues sample underwent processing for 2 and half hours in the various dehydrating agents that aimed at washing the samples and removing the water content. The samples were then placed in the embedding cassettes and put into the liquid paraffin till it solidified. After 24 hours they were removed from the cassettes and checked for the physical conformation. All tissue samples appeared in the same form and there was no deformation. The tissues were then placed into the blocks and hot wax was poured over it to obtain the blocks for the next step called sectioning. The blocks were obtained and the sectioning was successfully done.



Fig. 2. Fixation in the sodium nitrite

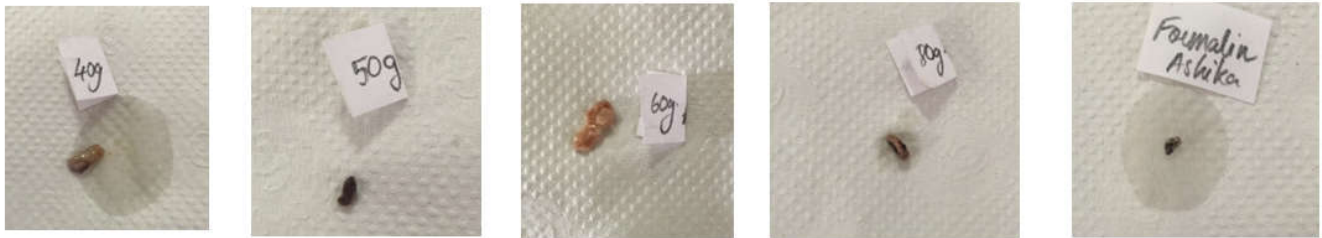

Fig. 3. Tissue sample after processing




Fig. 4. Block preparation before sectioning

Scoring	Ease cutting	Block stability and storage	General appearance	Morphological appearance of nuclei	Morphological appearance of cytoplasm of epithelial cells	Morphological appearance of connective tissue	Artefacts
0	Very difficult	Very poor	Distortion of the general architecture , improper orientation and staining	Not clearly visible	Hazy and distorted	Not clearly distinguished , hazy	Artefacts are numerous
1	Difficult	Poor	Orientation is proper with definition of a few structures and improper staining	Distorted appearance	Clearly visible and large number of vacuoles . Improper staining	Semblance of connective tissue observed , improper staining	Artefacts restricted to those elicited due to fixation of tissue processing . Improper staining
2	Very easy (too soft)	Medium	Structures are visible in proper orientation , margins not distinct , improper staining	Distinct in appearance , nucleoli is not visible	Distinct , less number of vacuoles . Staining not uniform	Collagen fibres are distinct in few areas and hazy in others . Improper staining	Less artefacts
3	Normal	Good	All structures are distinct in proper orientation to each other and exhibit proper staining .	Distinct nuclear membrane and nucleoli	Clearly seen, distinct , homogeneous, no vacuoles , uniform staining	Individual Collagen fibres can be made out distinctly with a distinct nucleus . Staining is proper .	No artefacts

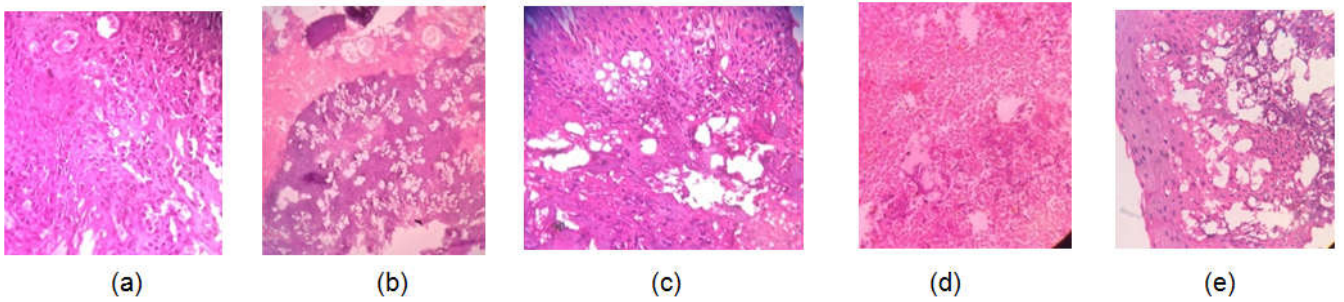


Fig. 5. Histopathological slide a)formalin (40X),b) 80g(10X),c) 60g (40X),d) 50g (40X) and e)40g (40X) respectively

Concentration	Ease Of cutting	Block stability on storage	General appearance	Morphology of nuclei	Morphology of cytoplasm	Morphology of connective tissue	Artefacts
40 g	3	Good	2	3	2	0	2
50 g	2	Good	0	0	0	0	0
60 g	3	Good	2	2	2	2	2
80 g	2	Good	0	1	0	0	0
Formalin	3	Good	3	2	3	3	3

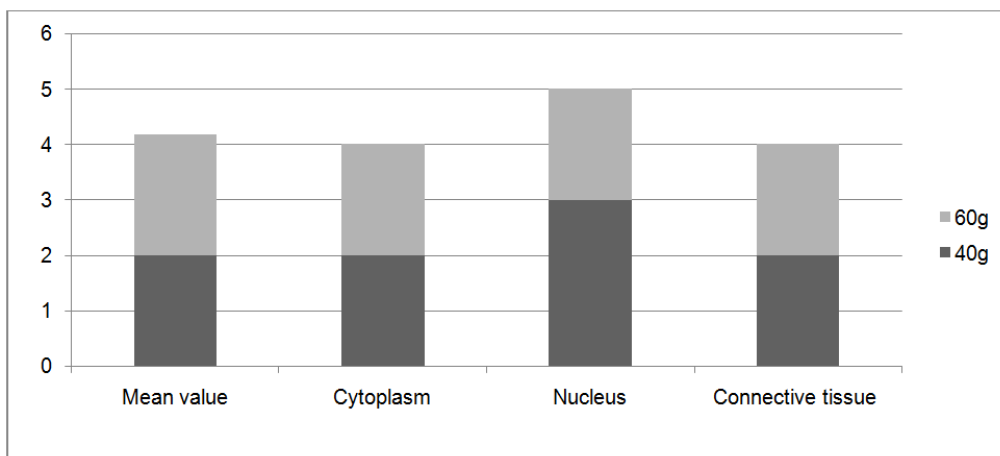


Fig. 6. Embedding and staining

Concentration	Ease Of cutting	Block stability on storage	General appearance	Morphology of nuclei	Morphology of cytoplasm	Morphology of connective tissue	Artefacts
30 g	2	Good	0	0	0	0	1
35 g	2	Good	0	0	0	0	0
40 g	3	Good	0	0	0	0	0
45 g	2	Good	2	1	2	2	2
50g	0	Good	0	0	0	0	0

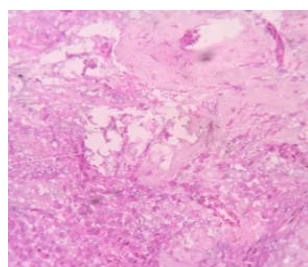


Fig. 6. Histopathological slide of 45g

The sectioned components were now eligible for staining and slide preparation. This was the scoring criteria for the various slide preparations. In the last step, using heamatoxylin and eosin stain, the tissue was stained and viewed under a microscope. The scoring was done based on the above mentioned criteria and it was graded. The slides demonstrated excellent staining and most of the cellular components were clearly visible. The grading was done and it was noticed that the concentration of 40 g and 60g showed the best fixation properties. In comparing these two, the most suitable fixative concentration found was 40g. Thus it proved from the study that sodium nitrite can be used as an alternative fixative. Care should be taken that the size of the tissue used must be a little larger in order to attain maximum success rate with this compound. The consequent study with concentrations 30,35,40,45 and 50 was done in the same way. The results from this part showed that only 45g had fixed the tissue effectively. The other samples obtained showed poor fixation as their morphological structures were not visible under the microscope. Only the 45g slide was clearly visible under the microscope and this was the only tissue available for scoring. The histopathological slide of 45g reveals the microscopic structures to an extent.

Conclusion

The need for discovering a potential alternative for formaldehyde was highly essential due to its hazardous effects on man. And it was proven in this study, that the experimental sodium nitrite solution could be used as an alternative to formaldehyde. However, we are still continuing the study to obtain more results about the efficacy of this compound with concentration around 60g and determine the accuracy of its fixing properties.

REFERENCES

- Black, J. 2012. Microbiology: Principles and exploration (8th ed.). John Wiley & Sons. p. 68.
- Bozzola, J.J., Russell, L.D. 1992. Electron microscopy: principles and techniques for biologists. Boston: Jones and Bartlett.
- Bryan, N. and Ivy, J., 2015. Inorganic nitrite and nitrate: evidence to support consideration as dietary nutrients. Nutrition Research, 35, 643-654.
- Drury, R.A.B., Wallington, E.A. 1980. Carleton's histological technique. 5th ed. New York: Churchill Livingstone.
- Eltoum, I., Fredenburgh, J., Grizzle, W.E. 2001. Advanced concepts in fixation: 1. Effects of fixation on immunohistochemistry, reversibility of fixation and recovery of proteins, nucleic acids, and other molecules from fixed and processed tissues. 2. Developmental methods of fixation. *J Histotechnol.*, 24;201-210.
- Eltoum, I., Fredenburgh, J., Myers, R.B., Grizzle, W.E. 2001. Introduction to the theory and practice of fixation of tissues. *J Histotechnol.*, 24;173 -190.
- Iyiola, S. and Avwioro, O. G. 2011. Alum haematoxylin stain for the demonstration of nuclear and extra nuclear substances. *Journal of Pharmacy and Clinical Sciences.*
- Leong, A.S.Y. 1994. Fixation and fixatives. In Woods AE and Ellis RC eds. *Laboratory histopathology.* New York: Churchill Livingstone, 4.1-1 - 4.1-26.
- Lillie, R.D., Hershberger, L.R. 1947. The genesis of acid formaldehyde hematin ("formalin pigment") and the influence of fixation on hemosiderins. *Bull Int Assoc Med Mus.*, 29:136, 1947.
- Musumeci, G. 2014. Past, present and future: overview on Histology and histopathology. *J Histol Histopathol*, 1, 5. <http://dx.doi.org/10.7243/2055-091X-1-5>
- Nigam, P. K. and Nigam, A. 2010. BOTULINUM TOXIN. *Indian Journal of Dermatology*, 55(1), 8-14.
- NTP. Report on carcinogens, Twelfth Edition. National Toxicology Program, USA Department of Health and Human Services, 2011; <http://ntp.niehs.nih.gov/ntp/roc/twelfth/roc12.pdf> November 7, 2011
- Rolls, G.O., Farmer, N.J., Hall, J.B. 1994. Artefacts in histological and cytological preparations. In Woods A and Ellis R eds. *Laboratory histopathology.* New York: Churchill Livingstone, 5.3-1 - 5.3-29.
- Sung, H.W., Chang, Y., Liang, I.L., Chang, W.H., Chen, Y.C. 2000. Fixation of biological tissues with a naturally occurring crosslinking agent: fixation rate and effects of pH, temperature, and initial fixative concentration. *J Biomed Mater Res* 2000.
- Titford, M. 2009. Progress in the development of microscopical techniques for diagnostic pathology. *J Histotechnol.* 32:9-19. <http://dx.doi.org/10.1179/his.2009.32.1.9>
- Walker, J.F. 1964. Formaldehyde, 3rd ed. Am Chem Soc Monograph Series. Reinhold, New York.
- Young, B., O'Dowd, G. and Stewart, W. 2010. *Wheater's Basic Pathology: A Text, Atlas and Review of Histopathology (5th Ed.).*
