



RESEARCH ARTICLE

STUDY OF INCIDENCE OF METOPIC SUTURE IN ADULT SKULLS

*Roghith Kannan and Thenmozhi, M. S.

Department of Anatomy, Saveetha Dental College, Chennai – 600 077

ARTICLE INFO

Article History:

Received 04th May, 2017
Received in revised form
02nd June, 2017
Accepted 25th July, 2017
Published online 31st August, 2017

Key words:

Metopic Suture,
Bregma,
Nasion,
Frontal Bone.

ABSTRACT

Background: The Metopic or Frontal Suture is formed at the meeting of the two halves of Frontal bone, in the midline. At birth the bone consists of two halves, the median surface usually disappears at about 8 years of age. Metopism is totally or partially persisting suture extending from anterior angle of the bregma of frontal bone to the nasion.

Materials and Method: An observational study was carried out on 50 dry adult human skulls which were used from the Department of Anatomy, Saveetha Dental College, Chennai, India, to study the incidence of metopic suture.

Result: The incidence of metopic suture was none in complete metopic suture, incomplete metopic suture was 20%. Among the incomplete ones, linear was found in 6 skulls (10%). 'V' shaped in 1 skull (1.6%) and 'U' shaped type in 5 skull (8%).

Conclusion: The knowledge of metopic suture is very important in radiological and orthopaedic surgeons during their practice in head injuries and it also important in practice of anthropologists and neurosurgeons.

Copyright©2017, Roghith Kannan and Thenmozhi. This is an open access article distributed under the Creative Commons Attribution License, which permits unrestricted use, distribution, and reproduction in any medium, provided the original work is properly cited.

Citation: Roghith Kannan and Thenmozhi, M. S. 2017. "Study of incidence of Metopic suture in adult skulls", *International Journal of Current Research*, 9, (08), 56429-56431.

INTRODUCTION

The frontal or the metopic suture is formed at the meeting of the two halves of the frontal bone which extends from the anterior angle of bregma to the nasion. The frontal bone forms the skeleton of the forehead which articulates inferiorly with the nasal and zygomatic bones. Metopic suture results when the suture between the two halves of the frontal bone fails to close. Among the incomplete ones, linear was found in 5 (5%), 'V' shaped in 1 (1%) and 'U' shaped type in 1 (1%) cases. Metopic suture usually starts to close in the second year of life and is usually completely obliterated within short duration of time. There is a continuous radial bone expansion in the second trimester and delineation of metopic suture occurs. In third trimester there is closure of metopic suture radiating from glabella and ascending upwards towards anterior fontanelle (Castilho *et al.*, 2006). Its presence in a fetal skull, along with other cranial sutures and fontanelles, provides a malleability to the skull that can facilitate movement of the head through the cervical canal and vagina during delivery. The dense connective tissue found between the frontal bones is replaced with bone tissue as the child grows older. Metopic sutures are either complete or incomplete. Metopism is a condition where the metopic suture completely extends from the bregma to the nasion (Bilodi *et al.*, 2003). If the suture is not present

throughout and occupies a small part between the bregma and nasion it is considered as incomplete metopic suture (Bademci *et al.*, 2007). Incomplete metopism is present in different shapes, U shaped, linear shape and V shaped of which linear shape is most common. This is very important for neurosurgeons as fracture of frontal bone is most common in metopic suture (Castilho *et al.*, 2006). When the Metopic suture is persistent, it is present as a typical dentate suture and about 2 cms anterior to the Coronal suture, which becomes more direct and simple, termed as pars bregmatica. It is also important for paleodemography and forensic medicine (Hauser *et al.*, 1991). The persistence of the metopic suture has been reported in frequencies ranging from 1% to 12% of skulls. According to Romanes, the metopic suture is present at birth but is normally closed by the fifth or sixth year, only traces of it being left above and below (Romanes, 1972). Moreover, according to Baaten *et al.*, people who live in rural areas have a higher incidence of metopism compared to people living in urban areas, with ratios of 4:1 and 4:2 respectively (Agarwal *et al.*, 1979). Fakhruddin and Bhalerao (1967) observed incidence of Metopism to be about 2% in Indian 8 skulls, Dixit & Shukla (1968) 2.53% in skulls from UP (Fakhruddin and Bhalerao, 1967). Among the incomplete ones, linear was found in 5 (5%), 'V' shaped in 1 (1%) and 'U' shaped type in 1 (1%) cases. In

*Corresponding author: Roghith Kannan,

Department of Anatomy, Saveetha Dental College, Chennai – 600 077

the present study, the objectives were to determine the incidence of metopic sutures and their extent.

MATERIALS AND METHODS

A total of 60 dry human skulls were used from the Department of Anatomy of Saveetha Dental College, Chennai for this observational study to determine and the study about the incidence of metopic suture. The extent of the metopic suture was also observed (complete or incomplete). The incomplete ones were classified as linear type, ‘V’ shape and ‘U’ type. Thereafter, they were observed for the presence of metopic suture or its remnants. Its length was measured with the help of thread spread straight from nasion to bregma. The data collected was tabulated using Microsoft excel worksheet. Photographs were taken of the metopic suture.

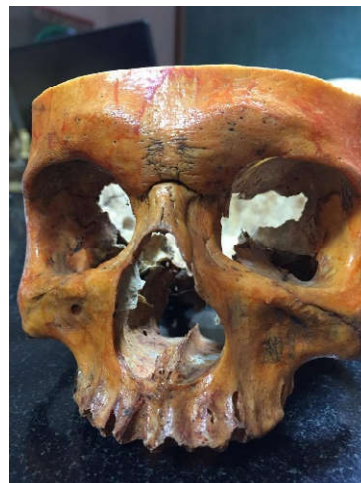RESULTS

The incidence of metopic suture was 20% of which complete metopic suture was none and incomplete metopic suture was in 12 skulls (20%). Among the incomplete ones, linear was found in 6 skulls (10%), ‘V’ shaped in 1 skull (1.6%) and ‘U’ shaped type in 5 skulls (8%).

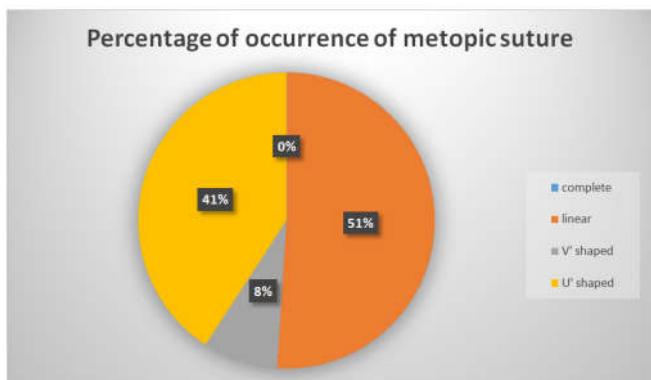
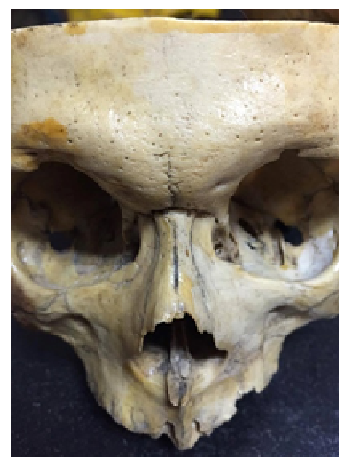Table 1. Incidence of Metopic suture

Type of suture	Number	Percentage
Complete	0	0%
Incomplete		
Linear	6	10%
‘V’ Shaped	1	1.6%
‘U’ Shaped	5	8%
Total	12	20%

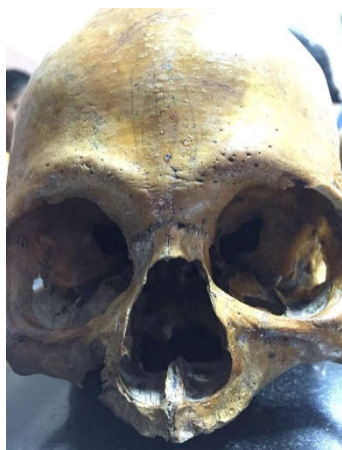U shape metopic suture



Linear metopic suture



‘V’ shaped metopic suture



DISCUSSION

The incidence of metopic suture varies from different races. The prevalence of metopic suture can be due to various causes such as abnormal growth of cranial bones, heredity, sexual, hormonal influence, growth interruption, atavism and cranial malformations. Maximum incidence of metopic suture was reported by Agarwal *et al* (1979), as 38.17% in Indian skulls, but incidence of Metopism observed by him was comparatively low, i.e. 2.66% (Agarwal *et al.*, 1979). Pankaj R study showed the incidence of metopic sutures in Indian adults was complete metopic suture (1.25%) and incomplete suture was (22.5%) (Wadekar *et al.*, 2014). Bryce *et al* reported metopism is present in 8.7 % of European skulls, 9.5 % of Scottish skulls, 1.2 % of Negroes, 5.1 % of Mongolian skulls and 1% of Australian skulls. The incidence of metopism is about 10% in Whites and Mongoloids and only 2 % in Negroids (Bryce, 1915). Ajmani *et al* carried out a study on 206 adult Nigerian skulls for the incidence of the metopic suture. They noted that metopism was present in 3.4% of cases, but an incomplete metopic suture was observed in 34.97% of the skulls (Ajmani *et al.*, 1983). Inderjit and Shah (1948) described variations in lower part of Frontal bone Y-shaped (in 1.25% cases), V-shaped (in 11.25% cases) and H-shaped (in 10 1.25% cases) while Das *et al* (1973) described the variations as a single linear midline suture (in 17.57% skulls), U-shaped (in 1.01%), V-shaped (in 1.93% skulls) and Y-shaped (in 0.28% skulls) (Inderjit and Shah, 1948). According to Baaten *et al*, people

who live in rural areas have a higher incidence of metopism compared to people living in urban areas, with ratios of 4:1 and 4:2 respectively (Baaten *et al.*, 2003). In this study 50 dry adult human skulls were analysed for the incidence of metopic suture. The total percentage of skulls with metopic suture was 20% of which there were no presence of complete metopic sutures and 12 skulls (20%) were incomplete metopic suture. The prevalence of 'U' shaped sutures was in 5 skulls (8%), 'V' shaped suture was in 1 skull (1.6%) and linear suture was 6 skulls (10%). In a head injury patient, there is a chance that the presence of the metopic suture may be enormously interpreted as a vertical fracture. It was reported that reconstructed tomography scans are superior to the plain X- ray films in the emergency setting. The information about metopic sutures is useful for forensic experts and radiologists. The morphological details of the metopic suture are important for the clinician from radiological and surgical point of view. To prevent confusion and a wrong diagnosis in emergency situations, while reading the X-ray/ CT and MRI films, the possibility of the metopic suture should be kept in mind (Bademci *et al.*, 2007).

Conclusion

Incidence of metopic suture was found to be in 12 skulls (20%). Persistent metopic suture may be wrongly diagnosed as a vertical skull fracture hence clinicians and surgeons should take this into consideration during diagnosis. It is important for forensic experts, neurosurgeons, maxillofacial surgeons, ENT surgeons and orthopaedic patients. Persistence of metopic suture is a useful guide in the identification of a person. Due to the paucity in the availability of the skulls, a lesser number of sample size was taken in our study.

Acknowledgement

With sincere gratitude, we acknowledge the staff members of Department of Anatomy and Saveetha Dental College for the whole hearted support and permission granted to utilize the resources and to conduct this study.

REFERENCES

- Agarwal S. K., Malhotra V. K. &Telewari S.P. 1979. Incidence of the metopic suture in adult Indian crania. *Actaanatomica.*, 105;469- 474.
- Agarwal S.K., Malhotra V.K. and Tewari S.P. 1979. Incidence of the metopic suture in adult Indian crania. *ActaAnat (Basel)*, 105(4): 469-474.
- Ajmani ML, Mittal RK, Jain SP. 1983. Incidence of the metopic suture in adult Nigerian skulls. *J Anat.*, 137: 177-183.
- Baaten PJ, Haddad M, Abi-Nader K, Abi- Ghosn A, Al-Kutoubi A, Jurjus AR. 2003. Incidence of metopism in the Lebanese population. *Clin Anat.*, 6:148-151.
- Bademci G, Kendi T, Agalar F. 2007. Persistent metopic suture can mimic the skull fractures in the emergency setting? *Neurocirugia.*, 18:238-240.
- Bademci G, Kendi T, Agalar F. 2007. Persistent metopic suture can mimic the skull fractures in the emergency setting? *Neurocirugia* 18: p. 238-240.
- Bilodi AK, Agrawal BK, Mane S, Kumar A. 2003. A study of metopic sutures in human skulls. *Kathmandu Univ Med J.*, 2:96-9
- Bryce TH. 1915. Osteology and Arthrology. In Quain's Elements of Anatomy, 4(11):177-180.
- Castilho.S M A, Oda.YJ & Santana. G D M. 2006.Metopism in adults skulls from southern Brazil. *Int. J .Morphol.*, 24 (1), p61-66.
- Fakhruddin S. and Bhalerao U.K. 1967. Interparietal Bone in Three Pieces-A case report. *J. Anat. Soc. India*, 16: 146-147.
- Hauser, G.; Mnazi. G.; Vienna, A. & De Stefano, G. F. 1991. Size and shape of human cranial sutures – a new scoring method. *Am. J. Anat.*190: p. 231-44.
- Inderjit and Shah M.A. 1948. Incidence of frontal or metopic suture amongst Punjabi adults. *I.M. Gazette*, 83: 507-508.
- Romanes G. J. 1972. Cunningham's Textbook of Anatomy, Oxford University Press, London, 11th ed; p133.
- Wadekar PR, Pundge SJ, Fulpatil MP, Pandit SV. 2014. Study of incidence of metopic suture in adult skulls. *Indian J Basic Appl Med Res.*, 4(1):277-83.
