



## CASE STUDY

# EVALUATION OF AgNOR STAINING USING EXFOLIATIVE CYTOLOGY IN ORAL SQUAMOUS CELL CARCINOMA

\*Hitasree, B. N., Malathi Manne, Shivani Neelam, Syed Afroz Ahmed, Charu Suri, Shahela Tanveer and Shravan Kumar

Sri Sai College of Dental Surgery Vikarabad, India

### ARTICLE INFO

#### Article History:

Received 16<sup>th</sup> November, 2016  
Received in revised form  
25<sup>th</sup> December, 2016  
Accepted 02<sup>nd</sup> January, 2017  
Published online 28<sup>th</sup> February, 2017

#### Key words:

Nonhistonic protein,  
Silver staining,  
Oral cancer.

### ABSTRACT

**Introduction:** Oral squamous cell carcinoma encompasses all malignancies originating in the oral cavity and there is need for improvement in early detection of oral carcinomas because treatment is more effective and the morbidity is minimal. Cytological study of oral cells is a non-aggressive technique that is well accepted by patients and an attractive option for early diagnosis. AgNORs study provides understanding of the tumoral behavior since their frequency, size and cell arrangement have been reported as a discriminatory factor between certain suspected lesions.

**Aim:** The aim of the present study was to evaluate the acidic, argyrophilic, nonhistonic proteins by using silver-staining AgNOR technique in exfoliated cells and to compare in normal oral mucosa and oral squamous cell carcinoma.

**Materials And Methods:** Exfoliative cells were obtained from 25 cases of oral squamous cell carcinoma and 25 cases of normal mucosa by using wooden spatula. After staining, 100 epithelial cells were randomly selected and counted by using oil immersion at 1000x magnification. Student's independent t-test was used for data analysis.

**Result:** The mean AgNORs count per nucleus was found to be 4.46 in oral squamous cell carcinoma group and 2.84 in normal mucosa with a p-value (<0.0001) and was statistically significant.

**Conclusion:** Thus the present study suggested that, the silver staining technique used for the detection of NORs in conjunction with exfoliative cytology is an easy, non-invasive and accurate screening method for the detection of clinically suspicious oral cancerous lesions. Because of its simplicity and high reliability for cellular proliferation, AgNOR staining with oral smears can be used as an adjunct to the other cytological diagnoses for the early detection of oral cancer.

Copyright©2017, Hitasree et al. This is an open access article distributed under the Creative Commons Attribution License, which permits unrestricted use, distribution, and reproduction in any medium, provided the original work is properly cited.

**Citation:** Hitasree, B. N., Malathi Manne, Shivani Neelam et al. 2017. "Evaluation of AgNOR staining using exfoliative cytology in oral squamous cell carcinoma", *International Journal of Current Research*, 09, (02), 46896-46899.

## INTRODUCTION

Oral squamous cell carcinoma (OSCC) is the most prevalent malignant neoplasm in oral cavity. (Pereira et al., 2007) It was defined by Pindborg et al. (1997) as "a malignant epithelial neoplasm exhibiting squamous differentiation as characterized patient by the formation of keratin and/or the presence of intercellular bridges. (Rajendran and Shivapathasundharam, 2006) The highest incidence is found to be increased by the very prevalent habits of chewing tobacco, betel quid and areca-nut. However, infection with high- risk human papillomavirus genotypes, a diet low in fruits and vegetables have also been implicated in the etiopathogenesis of OSCC. The mean 5- year survival rate has not improved from last 30 years despite the recent advances in diagnostic techniques and improvements in treatment modalities. (Feller and Lemmer, 2012) Exfoliative

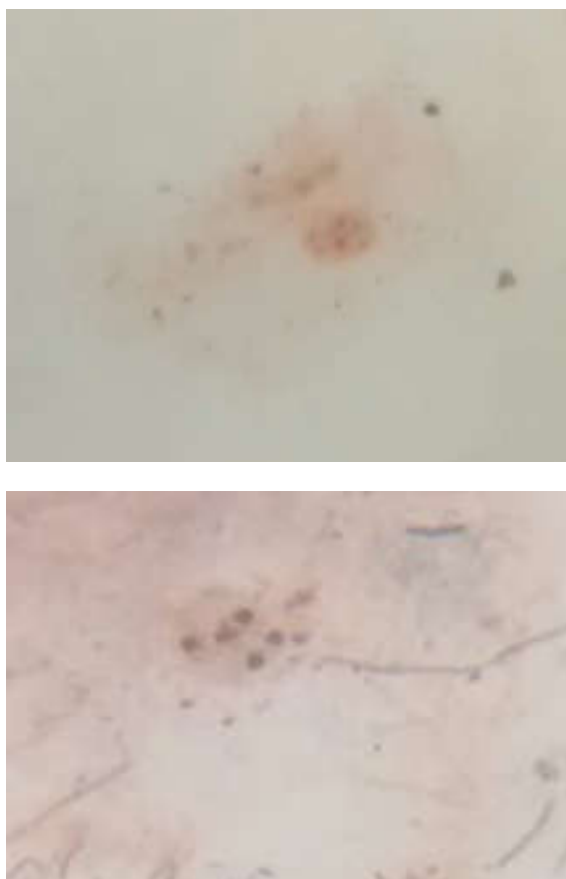
cytology is the microscopic examination of shed or desquamated cells from any epithelial surface usually from the mucous membranes. The sample includes cells collected by scrapping the tissue surface or cells collected from body fluids such as sputum, saliva etc. As oral mucosa exhibits a rapid turnover of cells, these exfoliated cells have a valuable role in diagnosis of certain local and systemic diseases. Thus, it is used as an easy, non-invasive procedure which could be carried to known the nature of any suspicion lesions. (Kaur et al., 2013; Kumaren and Jagannathan, 2014; Rajput and Tupkari, 2010) Nuclear organizer regions (NORs) represent loops of DNA actively transcribing to ribosomal RNA and to ribosome and finally to protein. These regions are associated with acidic, argyrophilic, nonhistonic proteins that can be visualized by using silver-staining AgNOR techniques. The purpose of the present study is to evaluate the number of NOR regions in OSCC patients who were clinically diagnosed or suspicious of cancerous lesion and compared with normal healthy individuals using exfoliative cells.

\*Corresponding author: Hitasree, B. N.

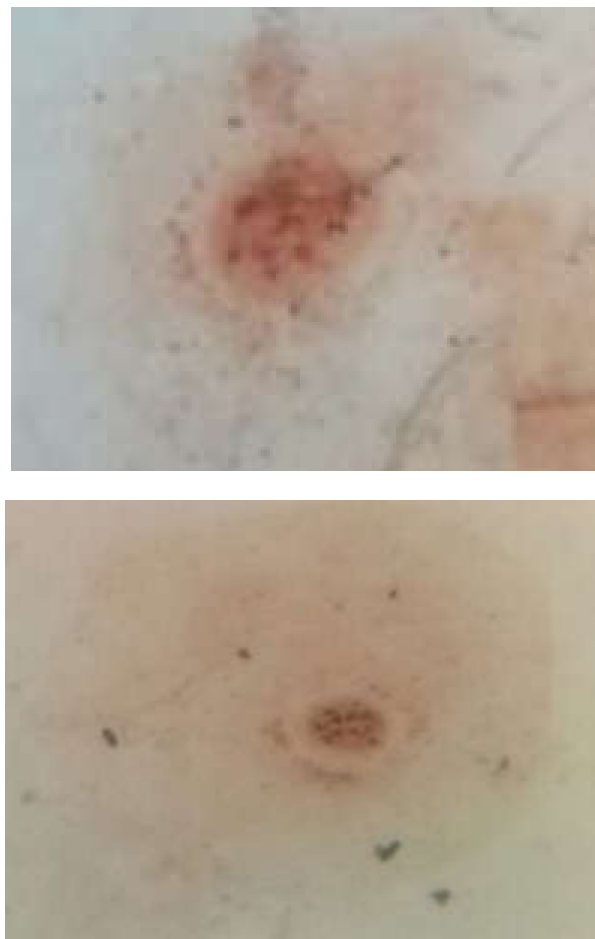
Sri Sai College of Dental Surgery Vikarabad, India

## MATERIALS AND METHODS

The study consisted of 50 cases, of which 25 cases included OSCC patients which were clinically diagnosed or suspicious of cancerous lesions and remaining 25 cases were normal healthy individuals. The exfoliated cells were obtained by using wooden spatula and stained with silver nitrate according to Plotons one-step method. The exfoliated cells were collected and smear was prepared on the glass slide. These smears were fixed in 95% ethanol followed by progressive rehydration and washed in distilled water. The AgNOR staining was carried out by using a solution containing one part of 2% gelatin in 1% aqueous formic acid and two parts of 50% silver nitrate. The smears were flooded with silver-colloidal mixture and were kept under safelight conditions for 55min at room temperature. After staining, the smears were placed in a dark container and washed in three changes of deionized water followed by immersion in 5% sodium thiosulfate solution for 5min. The smears were thoroughly washed in running tap water for 5min and later immersed in hypo eliminator solution for 5min. The smears were then washed in several changes of distilled water followed by increasing grades of dehydration in alcohols, cleared in xylene and mounted with DPX medium. (Rajput and Tupkari, 2010) The slides were examined under 1000X magnification in oil immersion by using a light microscope. 100 randomly selected individual cells were counted per slide in OSCC and control group. On examination, the NORs appeared as brown to black dots or blebs on a pale yellow background of the cells. The number of NOR were counted as individual dots in each cell. Comparison of mean NORs in OSCC and control group was done by using Independent student t- test.



**Fig. 1. The exfoliated cells in control group showing six AgNOR dots in each nucleus**



**Fig. 2. The exfoliated cells in OSCC group showing more than six AgNOR dots in each nucleus**

**Table 1. Statistical correlation between AgNOR counts in different groups**

Group	mAgNOR( $\pm$ SD)	P-value	Statistical significance
Control	2.8456 $\pm$ 0.09412		
OSCC	4.4640 $\pm$ 0.37935	0.0001	Highly significant

## RESULTS

In control group, the number of NORs was found to be ranged from 1 to 6 per nucleus with a mean of 2.8456 $\pm$ 0.09412 (Figure 1). In OSCC group, the number of NORs was found to be ranged from 1-11 per nucleus with a mean of 4.4640 $\pm$ 0.37935 (Figure 2). The p- value obtained was highly significant (0.0001). Thus, in the present study, them AgNORcounts were found to increase in number from control group to OSCC group (Table 1).

## DISCUSSION

OSCC represent more than 50% of all malignancy reported in oral cavity. They constitute a major health problem in developing countries, leading to death. According to WHO, carcinoma of oral cavity in males is sixth most cancer after lung, prostate, colorectal, stomach and bladder cancer whereas in females it is tenth most common cancer after breast, colorectal, lung, stomach, uterus, cervix, ovary, bladder and liver. Even though the oral cavity is more readily accessible to complete examination, it could be used in early detection of cancerous lesions. But due to inaccessibility of medical care,

the disease gets detected in the later stages. Thus, there is a need for improvement in early detection of oral carcinoma because the treatment is more effective in initial stages with minimal morbidity. (Mehrotra and Yadav, 2006) Hence, exfoliative cytology examination should be a suitable method to elucidate the diagnosis of any suspicious lesions much earlier than histology, especially when used with sensitive markers like AgNORs. (Rajput and Tupkari, 2010) Exfoliative cytology is a painless, atraumatic and simple technique for collecting superficial cells which is used extensively as a promising diagnostic tool, as it was thought to have the potential for early detection of malignant lesions. But it is not a substitute for biopsy. Rather, it is a useful essential adjunct in the diagnosis of oral surface lesions due to cancer, viral disease, vesiculobullous dermatoses or fungal infection. Less commonly, it may be employed to confirm a lesion strongly suggestive of cancer on clinical basis when the patient refuses for biopsy. In such cases, cytology is indicated to diagnose oral lesions which cannot be identified clinically, or those lesions which are thought to be benign, or a possible case of carcinoma in situ, or a lesion strongly suggestive of cancer on clinical basis. When an oral lesion cannot be identified clinically, cytological examination may be required when clinician is averse for a seemingly innocuous lesion. For example, a case with large or a small oral ulcer with mild erythema without induration and especially when the lesion is located in a region known to give rise to rapidly proliferating carcinomas with early metastases in the tongue, floor of the mouth and facial regions. If, on the other hand, the physician feels biopsy is in order, cytology may provide useful additional information. Occasionally, carcinoma or carcinoma in situ will be detected in its early stages and most commonly, however, a suspicious lesion will prove to be inflammatory. If the abnormality persists in the face of negative cytology, biopsy is mandatory. When the oral lesion is found to be benign, cytological examination may aid in differential diagnosis. For example, the smear showing the presence of candida may also show cells suspicious or positive for cancer. In such case, a subsequent biopsy or culture is necessary to establish the coexistence of candidiasis and OSCC. In cases of carcinoma in situ or less advanced premalignant lesions, some investigators believe that cytology can detect suspicious or malignant cells regardless of the clinical appearance of the lesion. When an oral lesion is strongly suggestive of cancer on a clinical examination, biopsy is mandatory before initiating definitive therapy. However, cytology is suggestive when patient refuses to biopsy procedure or when an additional proof is required for any referral or for early hospitalization for a confirmatory biopsy just prior to surgery. It also plays an important role in monitoring patients following surgical and radiation therapy. The most common pitfalls in exfoliative cytology include a scanty smear where enough cells do not harvest from the lesion to the glass slide or a poor quality smear showing debris or poor staining smear at the laboratory and improper interpretation. The most common cause for false negative report may be due to cytology performed on keratotic lesion with dysplasia in the deeper layer of the epithelium. In such cases, the cytology of the surface cells may not demonstrate a definitive dysplasia or invasive carcinoma. (Rickles, 1972)

Nucleolus is the location where ribosomal RNA is transcribed. During cell division, the nucleolus localizes at the secondary constriction of acrocentric chromosomes, where the argyrophilic nonhistone proteins namely NORs are also located. NOR are loops of DNA on the short arms of

acrocentric chromosomes namely 13, 14, 15, 21 and 22 that presumably are associated with ribosomal RNA activity, protein synthesis and cell proliferation. The number of NOR increases from the early G<sub>1</sub> phase to late S/G<sub>2</sub> phase. It is observed that higher the amount of NOR, shorter the cell cycle time. (Samadi *et al.*, 2014) On ultrastructure examination, the nucleoli appeared to comprise of fibrillar center, dense fibrillar component and granular component. The fibrillar center is probably the site where the primary r-RNA transcript is generated and contains ribosomal DNA, RNA polymerase I and topoisomerase I. It is equivalent of the interphase NOR seen at light microscopic level. NORs vary in size and shape according to nucleolar transcription and are intimately related to the cell cycle. During prophase the components of fibrillar center disperse and in metaphase these structures exist in constant positions on the short arms of these acrocentric chromosomes. In telophase, tiny granules associate with these NOR bearing chromosomes and these are ultimately arranged into the nucleolar structure. (Egan and Crocker, 1992) In the present study the smears were stained according to ploton *et al.* (1986) one step method. This method is remarkably specific as a means for detection of metaphase and interphase NORs by virtue of their associated proteins. The silver reaction product is seen as discrete black dots at light microscopic level and enumerated using a X 100 oil immersion lens. In the present study, the mean AgNOR count in OSCC was found to be 4.46 per nucleus and in control group was found to be 2.84 per nucleus. Similar results were obtained in various studies.

According to Samadi *et al.* (2014), AgNOR staining was conducted in oral leukoplakia with epithelial dysplasia and OSCC patients using histological sections. The mean AgNOR count per nucleus increased from normal oral mucosa (2.57) to oral leukoplakia with dysplasia (5.60) to OSCC (8.07). (Samadi *et al.*, 2014) According to Khiavi *et al.* (2012) study in OSCC using paraffin sections, the mean AgNOR count per nucleus was found to be increased from normal epithelium (1.58) to precancerous lesion (2.1) to OSCC (2.43). (Moradzadeh Khiavi *et al.*, 2012) According to Hanemann *et al.* (2011), assessed different types of OSCC and quantified number of AgNOR in each type using paraffin sections. They observed differences in AgNOR numeric values in different types of OSCC. (Hanemann *et al.*, 2011)

According to Rajput and Tupkari (2010) study, they compared PAP and AgNOR staining using brush biopsies in OSCC. The observed mean AgNOR count in control and OSCC was found to be 2.56 and 5.38 respectively per nucleus. They concluded that AgNOR staining in brush smears can be used as an adjunct to other routine cytological diagnosis for early detection of cancer. (Rajput and Tupkari, 2010) Since only few studies were conducted in OSCC using exfoliated cells, the present study was undertaken to compare the mean AgNOR count between OSCC group and control group as it is an easy, noninvasive and simple technique used for detecting the clinically diagnosed suspicious oral cancerous lesions.

## Conclusion

AgNOR is a quantitative technique, used to detect NOR associated proteins in a given cell. The number of AgNORs per nucleus is used to distinguish a precancerous lesion from malignancy. Therefore, it is represented as most appropriate prognostic marker for measuring cell proliferation in any suspicious lesions. Thus, the present study suggested that this

technique in conjunction with exfoliative cytology is an easy, non-invasive and accurate screening method for the detection of clinically suspicious oral cancerous lesions. Because of its simplicity and high reliability for cellular proliferation, AgNOR staining with oral smears can be used as an adjunct to the other cytological diagnoses for the early detection of oral cancer.

## REFERENCES

- Egan, MJ. and Crocker, J. 1992. Nucleolar Organiser Regions in Pathology. *Br. J. Cancer*, 65:1-7.
- Feller, L. and Lemmer, J. 2012. Oral Squamous Cell Carcinoma: Epidemiology, Clinical Presentation and Treatment. *J Cancer Ther.*, 3:263-268.
- Hanemann, JAC., Miyazawa, M. and Souza MSGS. 2011. Histologic Grading and Nucleolar Organizer Regions in Oral Squamous Cell Carcinoma. *J Appl Oral Sci.*, 19(3); 280-5.
- Kaur, M., Saxena, S., Samantha, YP., Chawla, G. and Yadav, G. 2013. Usefulness of Oral Exfoliative Cytology in Dental Practice. *J Oral Health Comm Dent*, 7(3):161-165.
- Kumaren, GD. and Jagannathan, N. 2014. Exfoliative Cytology- A Predictive Diagnostic Tool. *Int J Pharm Pharm Sci.*, 6(5):1-3.
- Mehrotra, R. and Yadav, S. 2006. Oral Squamous Cell Carcinoma: Etiology, Pathogenesis and Prognostic value of genomic alterations. *Indian Journal of Cancer*, 43(2):6064.
- Moradzadeh, Khiavi., Sepideh, Vosoughhosseini., Monire, Halimi., Seyyed, Mostafa, Mahmoudi. And Asghar, Yarahmadi., 2012. Nucleolar Organizer Regions in Oral Squamous Cell Carcinoma. *JODDD*, 6(1):17-20.
- Pereira, MC., Oliveira, DT., Landman, G. and Kowalski, LP. 2007. Histologic subtypes of Oral Squamous Cell Carcinoma: Prognostic Relevance. *J Clin Diagn Res.*, 73(4): 339-344.
- Rajendran, R. and Shivapathasundharam, B. 2006. Shafer's textbook of Oral Pathology, 6th ed: India; Elsevier Chapter 2, Benign and Malignant tumors of the Oral Cavity; p-101.
- Rajput, DV. And Tupkari, JV. 2010. Early detection of Oral cancer: PAP and AgNOR staining in brush biopsy. *J Oral and Maxillofacial Path.*, 14(2):52-58.
- Rickles, N.H. 1972. Oral Exfoliative Cytology: An Adjunct to Biopsy. *CA*. 22:163-171.
- Samadi, F M., Sebastian, B T, Singh, A., Chandra, S., Mohammad, S., Singh, A., Halappa, T. and Samadi, F. 2014. Silver Binding Nucleolar Organizer Regions Dots in Oral Leukoplakia with Epithelial Dysplasia and Oral Squamous Cell Carcinoma: An in vitro study. *ISRN Dent*, 1-4.

\*\*\*\*\*