



RESEARCH ARTICLE

LIQUID NITROGEN CRYOTHERAPY IN MANAGEMENT OF ORAL LESIONS

¹Dr. Avinash Akkur, ²Dr. Satya Bhushan, N.V.V., ³Dr. Gokkulakrishnan, S.,
⁴Dr. Chiang, K. C. and ⁵Dr. Bharat Prakash, M.

¹Private Practitioner, Visakhapatnam

²Professor & Head, GITAM Dental College & Hospital, Visakhapatnam

³Professor & Head, Aadiparashakti Dental College, Chennai

⁴Senior Lecturer, GITAM Dental College & Hospital, Visakhapatnam

⁵Post Graduate Student, GITAM Dental College & Hospital, Visakhapatnam

ARTICLE INFO

Article History:

Received 18th March, 2017

Received in revised form

07th April, 2017

Accepted 09th May, 2017

Published online 30th June, 2017

Key words:

Premalignant or precursor lesions,
Liquid nitrogen,
Cotton swab cryotherapy,
Freeze thaw cycles.

ABSTRACT

Potentially malignant disease of the oral mucosa, with the risk of conversion to Oral Squamous cell carcinoma (OSCC) is described as premalignant or precursor lesions. The lesions like leukoplakia, erosive lichen planus, retention cysts like mucocele, and hyperplastic growths like traumatic fibroma are predominantly seen intra orally. A prospective study was done on 10 consenting patients to evaluate the effectiveness of open cryosurgical method in treating intra oral lesions with liquid nitrogen. Cotton swabs, 5-10 mm in diameter, were dipped in liquid nitrogen for 1-2 seconds and applied directly to the lesions after local anesthetic infiltration. Each site was directly exposed to 4 or 5 consecutive freeze-thaw cycles. The patients were examined on the 3rd day, 1st week, 2nd week and one month post operatively, to evaluate the parameters like pain, swelling, erythema, sloughing, formation of granulation tissue and epithelization. Atraumatic bloodless procedures which could give same or better results than surgical technique was introduced in the recent past. Cryosurgery is one of the modalities which fulfills these criteria. This technique provides a bloodless field, causes less pain, decreases operating time and causes minimal surgical morbidity. Cotton swab cryotherapy (CSC) with liquid nitrogen has shown significantly good results in achieving complete regression (CR) of the benign and premalignant lesions of the oral cavity.

Copyright©2017, Dr. Avinash Akkur et al. This is an open access article distributed under the Creative Commons Attribution License, which permits unrestricted use, distribution, and reproduction in any medium, provided the original work is properly cited.

Citation: Dr. Avinash Akkur, Dr. Satya Bhushan, N.V.V., Dr. Gokkulakrishnan, S., Dr. Chiang, K.C. and Dr. Bharat Prakash, M. 2017. "Liquid nitrogen Cryotherapy in management of oral lesions", *International Journal of Current Research*, 9, (06), 53077-53080.

INTRODUCTION

Oral cavity accounts for approximately 3% of all malignancies and is a significant worldwide health problem. Potentially a malignant disease of the oral mucosa, with the risk of conversion to oral squamous cell carcinoma (OSCC) is described as a premalignant or precursor lesion. Satisfactory removal of diseased tissue by the surgeon depends upon the use of the simplest of instruments, the knife. In the present study, oral lesions were treated by open method of Cryosurgery in which nothing is excised, rather the lesion is allowed to undergo freezing and thawing, a certain number of times, by the application of cotton swabs dipped in liquid nitrogen and the resultant necrotic tissue is allowed to slough spontaneously. Perhaps, the absence of bleeding during the procedure, together with complete absence of secondary infection after the procedure, makes it the most suitable procedure for patients of any age and for medically compromised patients.

*Corresponding author: Dr. Avinash Akkur,
Private Practitioner, Visakhapatnam

MATERIALS AND METHODS

A prospective study was done on 30 consenting patients, who were randomly selected from the outpatient department of Oral and Maxillofacial Surgery, GITAM Dental College and Hospital, Visakhapatnam, to evaluate the effectiveness of cryosurgical method of treating oral lesions with liquid nitrogen. Intra oral lesions greater than 1 cm in diameter were included in the study. Cryosurgery basically consists of two methods. An open method in which the cryogen is applied to the lesions by cotton swabs or cryogun and a closed method in which the cryogen is applied to the lesion by using Cryo-probes. In the present study, an open method was used to treat the lesions via direct application of liquid nitrogen with cotton swab. Intra oral lesions like premalignant leukoplakia patches, lichen planus, irritational growths, pleomorphic adenoma and mucoceles were selected. Local anesthetic infiltration was given around the lesion. The cotton swabs, 5-10 mm in diameter, was dipped in liquid nitrogen for 1-2 seconds and applied directly to the lesions with moderate pressure. A swab

which closely corresponds to the size of the lesion was used. The method of application should start from the center to the periphery. Lesions too large to be frozen by single dip of a swab were managed by multiple overlapping applications. Since the oral mucosa was sufficiently moist, no watersoluble gel was required to improve the contact between the cotton swab and the mucosa. Each site was directly exposed to 4 or 5 consecutive freeze-thaw cycles. Freezing time was 30-50 seconds for mucocoeles, erosive lichen planus and 60-70 seconds for fibromas, leukoplakia and pleomorphic adenoma. This was spontaneously followed by Thawing for 30-60 seconds. After the ice ball produced during freezing was completely thawed, the next freezing was performed. High speed suction is necessary during treatment to control visual obstruction of the vapour fog. Secondary treatment was performed after 1 -2 weeks, if any residual lesions remained. Liquid nitrogen being a highly volatile substance must be used instantly from the time of dispensing it. Post operatively the patients were prescribed analgesics. The patients were examined on the 3rd day, 1st week, 2nd week and 1 month post operatively to assess the parameters like pain, swelling, erythema, sloughing, formation of granulation tissue and epithelization. Additional parameters like number of applications per appointment and the total number of appointments were also assessed.

RESULTS

Pain: The pain score was significantly different from post-operative score through 1 week. The post-operative and 3 days pain score was significantly higher than 1 week but there was no significant difference between post-operative and 3 days pain score.

Swelling: In this study 50% of the patients had slight swelling, 40% had mild swelling and 10% had severe swelling on the 3rd post-operative day. One week post operatively 60% of the patients had no swelling and 40% of the patients had slight swelling.

Erythema: Erythema was evaluated immediately after the procedure. 50% of the patients had mild erythema, 40% of the patients had moderate erythema and 10% of the patients had severe erythema.

Sloughing: The presence of sloughing was noted at the end of 1 week as present or absent. 80% of the patients had sloughing at the end of 1 week post operatively and 20% had no sloughing.

Granulation tissue: The formation of granulation tissue was noted between 1st and 2nd weeks. Granulation was rated as GOOD in 50% of the cases, FAIR in 30% and POOR in 20% of the cases.

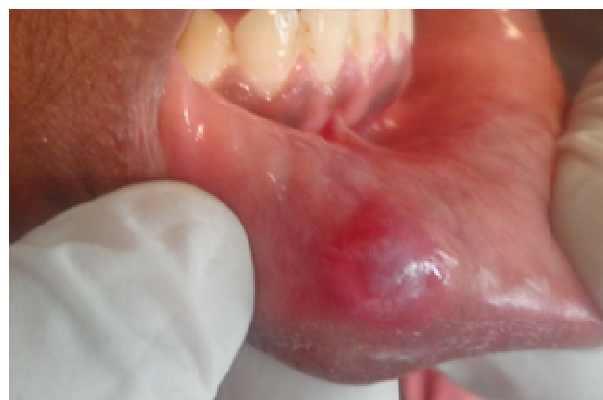Epithelization: Epithelization of the lesion was evaluated after 1 month post-operatively and was rated as GOOD in 70%, FAIR in 10% and POOR in 20% of the cases.

DISCUSSION

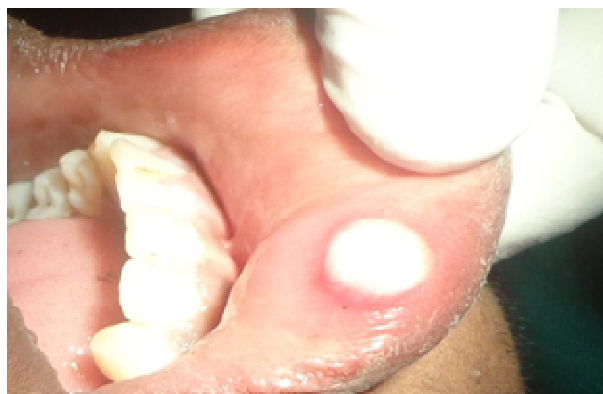Atraumatic bloodless procedures which could give same or better results than surgical technique was introduced in the recent past. Cryosurgery is one of the modalities which fulfills these criteria. The commonly used cryogens are liquid nitrogen

(-191°C), nitrous oxide (-81°C) and carbon dioxide snow (-79°C). Liquid nitrogen is most commonly used as it is the coldest, highly versatile and effective in eradicating soft tissue lesions. Cryotherapy is well accepted by patients due to relative lack of discomfort, as it is a less invasive procedure lower morbidity compared with surgical resection. The absence of bleeding, minimal operating time and complete lack of post-operative infection made cryosurgery a noble alternative to conventional scalpel. Cryosurgery is relatively a painless procedure. This is due to immediate blockage of neural transmission in the area. In this study 90% of the patients had slight pain immediately after the procedure. On the 3rd day post-operatively 70% had slight pain and 20% had moderate pain while 10% of the patients had no pain. At 1 week post-operatively 80% of the patients had no pain while 20% had slight pain. This is in accordance to the study done by *Chin-Jyh Yeh et al.* Localized swelling increased for 1-2 days and remained for 2 -3 days.

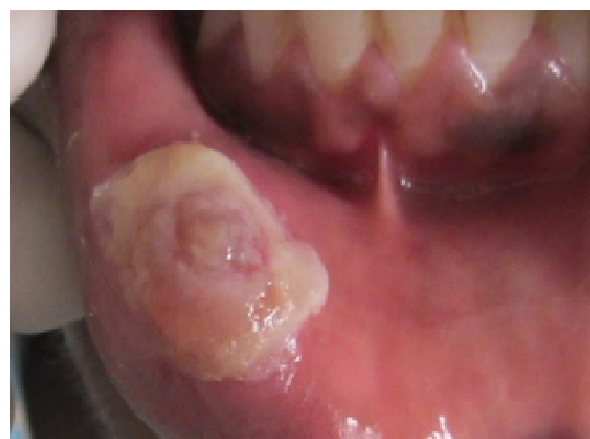
Pre operative photograph



Immediate post operative photograph

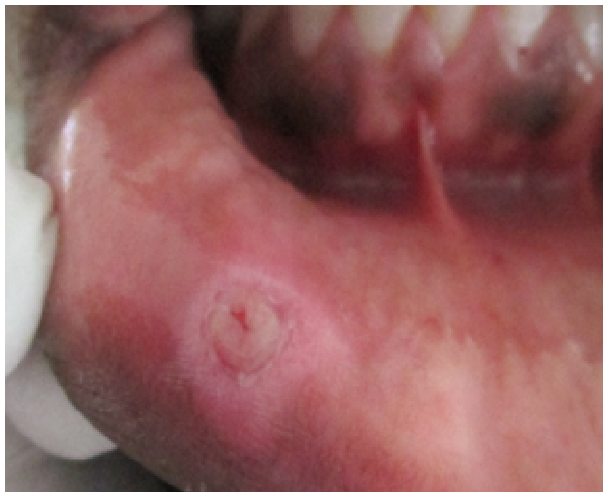

1 Week post operative

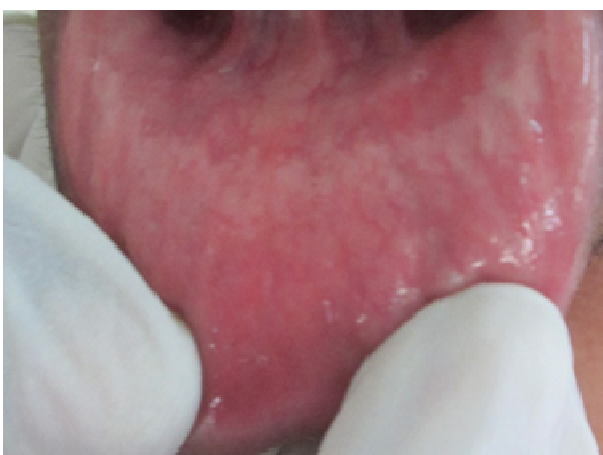

This is due to the difference in the osmotic gradients from the formation of extracellular and intracellular ice crystals. This is in accordance to the study done by *Chin-JyhYeh et al*, *Chuan – Hang Yu et al*, *Manu Prasad* and *Toida et al*. The effect of local vasoconstriction after cryotherapy and reduction in the blood flow results in erythema.

2 week post operative



1 month post operative



During the first hour after freezing and thawing mild erythema developed. In this study 50% of the patients had mild erythema, 40% had moderate and 10% had severe erythema. This is in accordance to the study done by *Toida et al* in which during the first hour after freezing mild erythema developed. The lesion and the overlying mucosa become necrotic and sloughed within 3-5 days following cryosurgery. In this study sloughing was classified as present or absent after 1 week post-operatively. In 80% of the patients sloughing of the lesion occurred at the end of 1st week post-operatively, while in 20% there was no sloughing. This is in accordance to the study done by *C.J. Yeh*, *Chen et al* and *Toida et al*. Formation of granulation tissue is one of the events during the healing period following cryosurgery. In this study formation of granulation tissue postoperatively occurred between the 1st and the 2nd weeks. 50% of the patients had good formation of granulation tissue, 30% had fair and 20% had poor formation of granulation tissue. This is in accordance to the study done by *Chin-JyhYeh et al* and *Toida et al*. Complete epithelization of the oral lesion after cryosurgery is the final step during the uneventful healing process. This process depends on the size and location of the lesion. In this study epithelization of the

mucosa overlying the lesion occurred after 1 month post-operatively. 70% of the patients had good epithelization, 10% had fair and 20% had poor epithelization. This is in accordance to the study done by *Chin-JyhYeh et al*, *Manu Prasad* and *Toida et al*. A nearly finding in clinical cryosurgery was that repeat freezes were more effective than a single freeze. In this study the oral premalignant and benign lesions were treated with an average of 3-4 cycles per appointment depending on the size of the lesion. The average number of appointments was 2-3 per patient. This is in accordance to the study done by *ValappilaNidhin et al*.

Conclusion

Cotton Swab Cryotherapy (CSC) with liquid nitrogen has shown significantly good results in achieving complete regression (CR) of the benign and premalignant lesions of the oral cavity. This technique provides a bloodless field, causes less pain, decreases the operating time and causes minimal surgical morbidity compared to the conventional methods of treating intra-oral lesions. The most common difficulty in this technique is the portability of the cryogenic agent. In this study liquid nitrogen which was used as the cryogen is highly volatile. It requires special storage container for short term storage and canisters for dispensing it from the container during its use. The time difference between dispensing the liquid to its application should be very minimal. This problem can be diligently dealt by planning the procedure very precisely with the help of experienced assistants.

REFERENCES

- Brain, L. Schmidt and M.A.Pogrel; 2004. Neurosurgery changes after Liquid Nitrogen Cryotherapy; *Journal of Oral and Maxillofacial Surgery*; 62; 1183- 1187; 2004.
- Chin-JyhYeh, Cryosurgical treatment of melanin-pigmented gingiva; *Oral Surg Oral Med Oral Pathol Oral RadiolEndod*; 86; 660-663; 1998.
- Chin-JyhYeh; Simple cryosurgical treatment for Oral Lesions; *International Journal of Oral and Maxillofacial Surgery*; 29; 212-216; 2000.
- Chuan- Hang Yu, Hsin- Ming Chen, Chia-Chuan Chang, Hsien -Yen Hung, Chuhsing Kate Hsiao, Chun-Pin Chiang; Cotton –Swab Cryotherapy for Oral Leukoplakia; *Wiley InterScience Journal*; 2008.
- Darbandi, A., AmelShahbaz, N. 2004. Effect of Cryotherapy on Physiologic Pigmentation of Oral Mucosa- A Preliminary Study; *Journal of Dentistry*; Vol- 1; No: 2.
- DariushAmanat, Hooman Ebrahimi, Maryam ZahedZahedani, NasimZalni, Sara Pourshahidi, Zahra Ranjbar; Comparing the effects of cryotherapy with nitrous oxide gas versus topical corticosteroids in the treatment of oral lichen planus; *Indian Journal of Dental Research*, 25(6), 2014.
- Farah, C.S., Savage, N.W. Cryotherapy for treatment of Oral Lesions; *Australian Dental Journal*; 51;2-5;2006.
- HedelsonOdenirlecher Borges, Etienne de Andrade Munhoz, Rosilene Andrea Machado; Clinical use of cryotherapy to treat Oral inflammatory hyperplasia; *International Journal of Clinical Dental Science*; 2(1); 2011.
- Hisn- Ming Chen, Shih-Jung Cheng, Hung-Pin Lin, Chuan-Hang Yu, Yang- Che Wu, Chun- Pin Chiang; Cryogun cryotherapy for Oral Leukoplakia and adjacent melanosis lesions; *Journal of Oral Pathology and Medicine* ;44 ; 607-613;2015.

- Joanna M. Zakrzewska, F.F.Nally; The Role of Cryotherapy (Cryoanalgesia) in the Management of Paroxysmal Trigeminal Neuralgia: A six year experience; *British Journal of Oral and Maxillofacial Surgery*; 26; 18-25; 1988.
- Juniper, R.P., Trigeminal Neuralgia – treatment of the third division by radiologically controlled cryoprobe of the inferior dental nerve at the mandibular lingual: A study of 31 cases; *British Journal of Oral and Maxillofacial Surgery*; 29; 154-158; 1991.
- Kemal Tuncali, Paul R. Morrison, Carl S. Winalski, John A. Carrino, Sridhar Shankar, John E. Ready, Eric vanSonnenberg, Stuart G. Silverman; MRIGuided Percutaneous Cryotherapy for Soft Tissue and Bone Metastases: Initial Experience; *American Journal of Radiology*; 2007.
- Kumari KB, Bhushan NS, Kalyan US, Chiang KC, Saketh GS, Prakash MB. 2016. Evaluation of average distance from mandibular canal to the root apices, cemento-enamel junction and alveolar crest of mandibular molars in coastal Andhra population. *Int.J. Adv. Res.*, 4(12), 2384-2392.
- Kumari, K.B., Bhushan, N.V.V.S., Sunil, T., Kalyan, U.S., Chiang, K.C., Saketh, G.S., Prakash, M.B. 2017. Efficacy of turmeric in the management of oral lichen planus. *International Journal of Current Research Vol. 9, Issue, 03, pp.48119-48124.*
- Leonardo Toniello, Hedelson Odenir, Carlos Alberto, Daniela Nascimento; Enucleation and Liquid Nitrogen Cryotherapy in the Treatment of Keratocystic Odontogenic Tumors: A Case Series; 112-117; 2011.
- M. Anthony Pogrel; The use of Liquid Nitrogen Cryotherapy in the Management of Locally Aggressive Bone Lesions; *Journal of Oral and Maxillofacial Surgery*; 51; 269-273; 1993.
- MacDonald, D.G. Critchlow, H.A. Effect of 2 episodes of cryosurgery on carcinogen-treated hamster cheek pouch; *International Journal of Oral and Maxillofacial Surgery*; 16; 90-94; 1987.
- Manu Prasad, Tejraj P Kale, Rajshekhar Halli, Kotrashetti SM, Baliga SD; Liquid nitrogen Cryotherapy in the management of Oral Lesions: a retrospective clinical study; *Journal of Maxillofacial and Oral Surgery*; 8(1); 40-42; 2009.
- Marcos Martins, Luciano Dib, Decio Santos Pinto; Management of solid ameloblastoma of Jaws with Liquid Nitrogen spray cryosurgery. *Oral Surg Oral Med Oral Pathol Oral Radiol Endod*; 84; 339-344; 1997.
- Paul F. Bradley; Cryosurgery of the Maxillofacial Region; Clinical Application to Malignant Lesions and Comparison with Lasers; Volume 2.
- Pogrel, M.A., J.A. Regezi, B. Fong, Z. Hakim Faal, M. Rohrer, C. Tran, T. Schiff; Effects of Liquid Nitrogen cryotherapy and bone grafting on artificial bone defects in minipigs: a preliminary study; *International Journal of Oral and Maxillofacial Surgery*; 31; 283-293; 2002.
- Pradel, W., Hlawitschka, M. Eckelt, U., Herzog, R., Koch, K. 2002. Cryosurgical treatment of genuine trigeminal neuralgia; *British Journal of Oral and Maxillofacial Surgery*; 40; 244-247.
- Prakash, M.B., Bhushan, N.S., Kalyan, U.S., Chiang, K.C., Saketh, G.S., Kumari, K.B. 2017. Evaluation of bite force among different age groups in Visakhapatnam district. *Int.J. Adv. Res.*, 5(1), 402-407.
- Prakash, M.B., Bhushan, N.S., Kalyan, U.S., Chiang, K.C., Saketh, G.S., Kumari, K.B. 2017. Evaluation of bite forces in patients with mandibular fractures treated with locking miniplates. *International Journal of Current Research Vol. 9, Issue, 03, pp.47620-47623.*
21. Ravi Narula, Bhavna Malik; Role of Cryosurgery in the Management of Benign and Premalignant lesions of the Maxillofacial region; *Indian journal of Dental Sciences*; Issue:2; Vol:4; 2012.
- Saketh, G.S., Bhushan, N.S., Kalyan, U.S., Chiang, K.C., Prakash, M.B., Kumari, K.B. 2016. Culture sensitivity of odontogenic infections in the head and neck region. *Int.J. Adv. Res.*, 4(12), 2377-2383.
- Saketh, G.S., Bhushan, N.V.V.S., Ravindranath, K.V., Kalyan, U.S., Chiang, K.C., Kumari, K.B., Prakash, M.B. 2017. Immediate placement of implants in infected extraction sockets. *International Journal of Current Research Vol. 9, Issue, 03, pp.48125-48129.*
25. Paul F. Bradley; Cryosurgery of the Maxillofacial Region; General Principles and Clinical application to Benign Lesions; Volume 1.
- Toida, M., Ishimaru, J.I., Hobo, N. A simple cryosurgical method for treatment of Oral Mucous cysts; *International Journal of Oral and Maxillofacial Surgery*; 22; 353-355; 1993.
- Valappila Nidhin, J., Ganapathi, K.S., Saddu Shweta; Cryosurgery as a Treatment Modality in Leukoplakia- A Pilot Study; *Unique Journal of Medical and Dental Sciences*; 01; 31-34; 2013.
- Yeh, C.J. 2003. Treatment of Verrucous hyperplasia and verrucous carcinoma by shave excision and simple cryosurgery; *International Journal of Oral and Maxillofacial Surgery*; 32; 280-283; 2003.
- Yiu, W., Basco, M.T., Aruny, J.E., Cheng, S.W.K., Sumpio; B.E. 2007. Cryosurgery: A review; *International journal of Angiology*; 16(1): 1-6.
