



CASE REPORT

DEPIGMENTATION- A REVIEW AND CASE REPORT

Dr. Mitul Mishra, *Dr. Grishmi Niswade, Dr. Jasmeet Chandhok and Dr. Arihant Bathiya

Department of Periodontology, Swargiya Dadasaheb Kalmegh Smruti Dental College and Hospital, Nagpur

ARTICLE INFO

Article History:

Received 23rd March, 2017

Received in revised form

09th April, 2017

Accepted 21st May, 2017

Published online 30th June, 2017

ABSTRACT

The gingival facade and health are critical components of an attractive smile. Oral pigmentation is a discoloration of oral mucosa or gingival associated with several exogenous and endogenous factors. "Black gums" are an aesthetic problem especially those with a gummy smile. The reason for dark colour of gingival is the hyperactivity of melanocytes. Depigmentation is a procedure of removing or reducing gingival hyperpigmentation. This article focuses on literature related to various techniques used for treatment.

Key words:

Depigmentation, Gingiva, Melanin,
Melanocytes, Proliferation, Epithelium.

Copyright©2017, Dr. Mitul Mishra, et al. This is an open access article distributed under the Creative Commons Attribution License, which permits unrestricted use, distribution, and reproduction in any medium, provided the original work is properly cited.

Citation: Dr. Mitul Mishra, Dr. Grishmi Niswade, Dr. Jasmeet Chandhok and Dr. Arihant Bathiya, 2017. "Depigmentation- a review and case report", International Journal of Current Research, 9, (06), 52571-52575.

INTRODUCTION

Pigmentation is defined as the process of deposition of pigments in tissues. Pigmentation lesions of the oral cavity are due to intensification of melanin production, amplified number of melanocytes or deposition of accidentally introduced exogenous materials (Kauzman *et al.*, 2004 and Greenberg *et al.*, 2003). Oral pigmentation may be physiologic or pathologic in nature. Pathologic pigmentation is further classified into exogenous and endogenous based upon the cause. Causes of exogenous pigmentation include drugs, tobacco/smoking, amalgam tattoo or deposition of heavy metals. Causes of endogenous pigmentation include pigmentation associated with endocrine disorders, syndromes, infections, chronic irritation, reactive or neoplastic. Gingiva is the most commonly affected site for hyperpigmentation. Various factors are responsible for maintaining the normal colour of gingival such as number and size of blood vessels, thickness of the epithelium, degree of keratinisation and quantity of pigments. The most common cause of endogenous pigmentation of gingiva is melanin, which is a brown pigment. This pigmentation is caused by melanin granules present in gingival, which are produced by melanosomes of melanocytes. Melanocytes are present in the basal and suprabasal layers of epithelium (Greenberg, 2003).

Classification of oral pigmentation (Greenberg *et al.*, 2002)

- Physiologic- racial
- Pathologic
- Exogenous- drug induced, tobacco chewed, smoking, heavy metals, amalgam tattoo
- Endogenous –
- Endocrine disorders such as Addison's disease, diabetes, hyperthyroidism
- syndrome associated such as Peutz-Jegher syndrome, Macune Albright syndrome, neurofibromatosis
- Infections such as HIV, tuberculosis, candidiasis
- chronic irritation including post-traumatic and post-inflammatory (lichen planus, pemphigus)
- Reactive- oral melanocytic macule, oral melanoacanthoma
- Neoplastic- benign and malignant

Melanin

In all four pigments are responsible for maintaining normal colour of skin and mucosa, that include melanin, carotenoids, reduced haemoglobin and oxygenated haemoglobin. Melanin is an endogenous nonhematogenous pigment that is produced by melanocytes in the basal layer of the epithelium. It is transferred to adjacent keratinocytes via membrane bound organelles called melanosomes. Pigmentation induced by melanin can be black, gray, blue or brown in color (Eisen,

*Corresponding author: Dr. Grishmi Niswade,
Senior lecturer, Department of Periodontology, Swargiya Dadasaheb
Kalmegh Smruti Dental College and Hospital, Nagpur

2000 and Barrett, 1994). It is more prevalent in dark skinned African population and in Asians between 30 % and 80% (Anil Kumar, 2015). Different types of melanin are eumelanin, pheomelanin, neuromelanin, oxymelanin and mixed type melanin.

Treatment of gingival hyperpigmentation

Chemical cauterization (Hirshfield and Hirshfield) (Hirschfeld, 1951): These methods are no longer in use because of the destructive nature and difficulty in controlling the depth of their penetration. A mixture of 90% phenol and 90% alcohol was used earlier.

Gingivectomy (Dummett CO) (Dummett, 1963)

Scalpel technique- After administration of local anesthesia, the uppermost layer of gingival is scraped using a 15 number blade. The blade is held parallel to the long axis of the teeth with minimal pressure. Bleeding from the tissues is controlled by pressure pack with the help of sterile pieces of gauze. Post-operatively the operated area is covered with a periodontal pack. The periodontal pack is usually removed within one week.

Bur method (Pal et al., 1994): In this technique, depigmentation is carried out with the help of a round bur. It is used in feather light strokes without any pressure. Thermal trauma and trauma to the underlying tissues should be avoided by placing the bur for a long time in one place. Bleeding should be controlled using pressure pack and damage to the adjacent teeth should also be avoided.

Electrosurgery- After administration of local anaesthesia, a needle electrode is applied in a sweeping motion on the gingival tissues in a cervico-apical direction. The operated filed is kept clean with pieces of sterile gauze piece. The operated area is covered with periodontal pack. Electrosurgery uses electric energy to cause molecular disintegration of melanin cells of operated and surrounding sites, as explained by Olinger's "Exploding cell theory".

Laser (Trelles et al., 1993): Depigmentation can be done with the help of a laser such as Nd:YAG, Er:YAG, CO2 using light brushing strokes on the gingival tissues. Nd:YAG laser has a high affinity for dark pigments making it particularly suitable for depigmentation. The radiation energy of lasers is transformed into ablation energy, resulting in cellular rupture and vaporization with minimal heating of surrounding tissue. Remnants of the ablated tissue are removed using sterile gauze dampened with saline solution. The procedure is repeated until the desired depth of tissue removal is achieved. Advantage of using laser for depigmentation is that it produces a bloodless field, causes minimum damage to the periosteum and underlying bone and the treated area often does not need a periodontal dressing.

Cryosurgery (Tal Haim et al., 1987; Chin - Jyh Yeh, 1998): Gingival depigmentation can be performed using liquid nitrogen and a gas expansion system. Cryosurgery procedure is reported as simple, easy to implement, and cost effective, it could cause a wide range of side effects. Whereas some of these complications are predictable and minimal, despite immediate healing, others can be observed in the long-term follow up. Cryosurgery may cause some immediate

complications (headache, pain, and subcutaneous emphysema) and delayed (infection, haemorrhage, and excessive granulation) and prolonged (hyperpigmentation, hypopigmentation, hypertrophic scars, alopecia, and atrophy) effects.

Free gingival grafts (Tamizi and Taheri, 1996): FGG was first described by Bjorn in 1963. They are primarily used to increase the width of attached gingival and in root coverage procedures.

Acellular dermal matrix allografts (Novaes et al., 2002): After local anesthesia administration, two vertical incisions are performed on the non pigmented tissue both mesial and distal to the pigmented area using a #15 scalpel blade. A horizontal sulcular incision is needed to reflect a partial thickness flap containing pigmented area. After adequate hemostasis, the graft should be prepared according to the manufacturer's instructions and trimmed to fit the recipient site. Graft should be secured to adjacent attached gingival with lateral bio-absorbable sutures.

Indices on Gingival Pigmentation (Gulati, 2016)

- Dummet and Gupta (1964) proposed Oral pigmentation index (DOPI)
- Hedin (1977) proposed Melanin index.
- Hanioka (2005) proposed Melanin pigmentation index.
- Kumar (2012) proposed Gingival pigmentation index.
- Peeran et al. (2014) proposed a new improved classification for gingival pigmentation and pigmented lesions.

Case Report

A 30 year old, non-smoking, systemically healthy, dark skinned male patient was referred to Department of Periodontology with aesthetic complaints in January 2017. The patient had generalized gingival pigmentation extending buccally from molar to molar in the maxillary arch and canine to canine in the mandibular arch (Figure 1). The pigmentation was more prominent in the maxillary arch due to high smile line. Therefore, depigmentation was decided for the maxillary arch. Among all the treatment modalities available for treatment of gingival melanin pigmentation, the conventional scalpel method was preferred. There are various factors which the treatment modality to be used, such as type of pigmentation, skin complexion, aesthetic importance and patient's acceptance for treatment. The advantage of scalpel technique is that it is less expensive and no sophisticated instruments are required. After achieving local anaesthesia, the outline was initially marked with a 15 BP blade. With the help of a blade, the entire pigmented epithelium was removed along with a layer of connective tissue (Figure 2 and 3). The surgical area around the marginal gingival was operated carefully to prevent gingival recession. Bleeding was controlled by the application of pressure with sterile gauze. After the procedure was completed, the operated area was covered with a periodontal pack (Figure 4). The patient was then prescribed antibiotics and anti-inflammatory drugs for 5 days. Pain and discomfort was noticed by the patient on the 2nd day. The pack was removed on 7th day (Figure 5). Within the first 14 days, initial healing was observed. Re-epithelisation was complete by 1 month and gingiva appeared healthy without pigmentation at the end of 3 months.

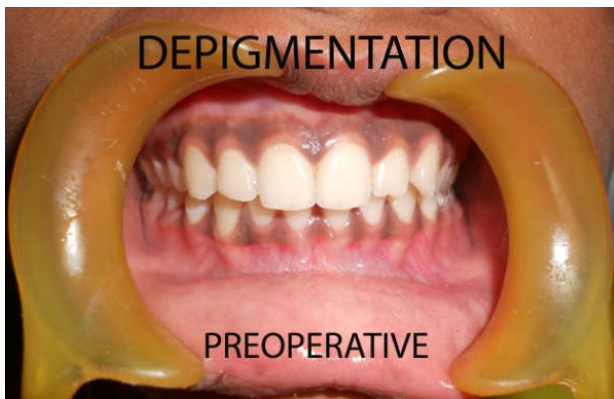


Figure 1. Pre-operative view

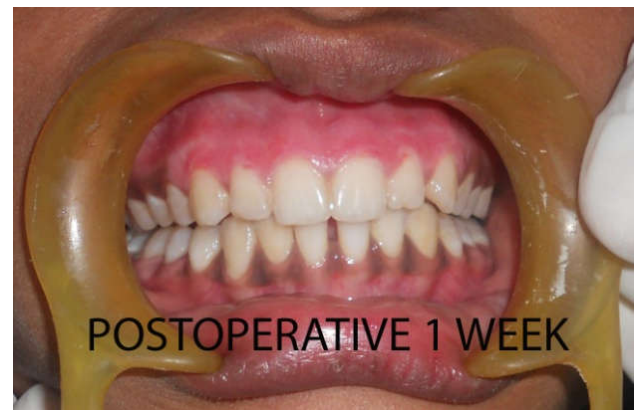

Figure 5. Follow up after 1 week

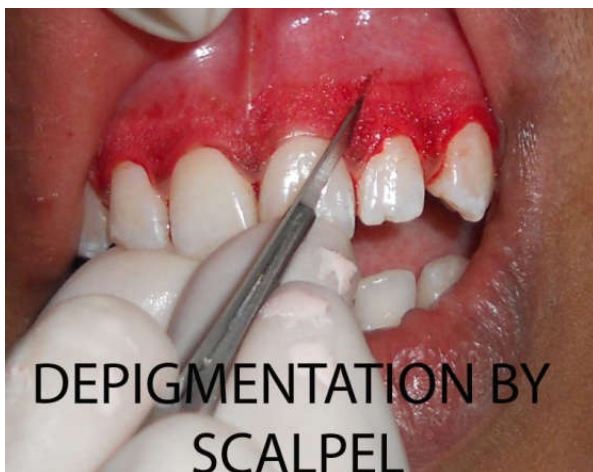

Figure 2. Epithelium and a layer a connective tissue removed

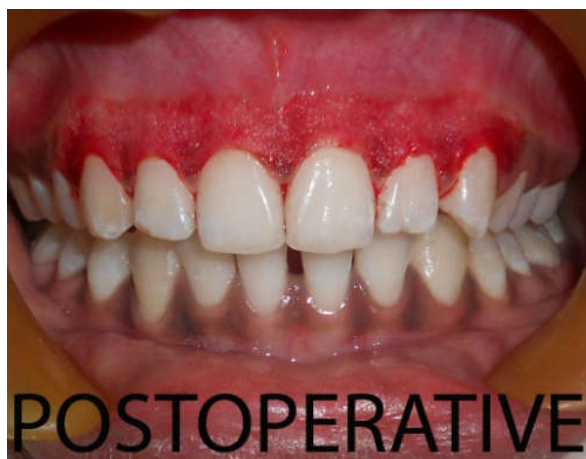

Figure 3. After complete removal of epithelium

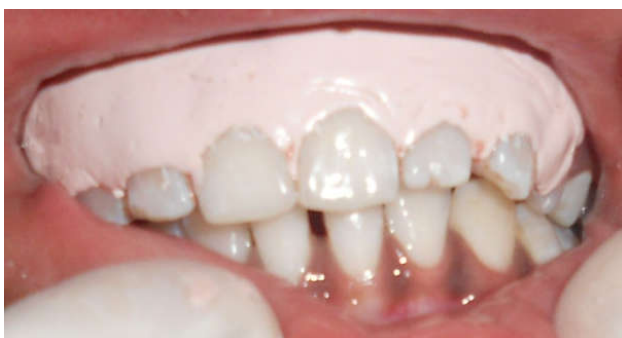

Figure 4. Placement of periodontal pack

DISCUSSION

Gingiva is the most commonly pigmented intraoral tissue. Melanin is an elementary pigment colouring the tissues. A variety of techniques are available for the treatment of gingival hyperpigmentation.

Scalpel technique: According to Almas and Sadiq (2002), the scalpel wound heals faster than that in other techniques. But scalpel surgery causes unpleasant bleeding during and after the operation. It is also necessary to cover the exposed lamina propria with periodontal dressing for 7–10 days (Almas, 2002).

Electrocautery: Cicek (2003) reported that there is no bleeding and there is minimal patient discomfort while using electrocautery. But electrosurgery also has its own limitations in that its repeated and prolonged use induces heat accumulation and undesired tissue destruction (Cicek, 2003).

Laser: Sharon *et al.* tested the efficacy of CO₂ laser. It was found to be effective in eliminating the pigmented areas in all tissues treated and no recurrence of melanin was detected in either the oral mucosa or gingival (Sharon, 2000). Tal *et al.* in their study in 10 patients with pigmented gingival used Er: YAG laser. The brush technique was applied until the gingival surface appeared clinically free of pigmentation. The esthetic results were pleasing and healing was reported to be uneventful (Tal, 2003).

Free gingival graft: Fowler *et al.* used the free gingival graft technique to eliminate an aberrant maxillary labial frenum and to increase melanin pigmentation at the surgical site. For that purpose, they utilized a graft from a donor site rich in melanin pigmentation.¹Tamizi M and Taheri M in 1996 documented the treatment of physiologic gingival pigmentation with free gingival autografts. No evidence of re-pigmentation was found 4.5 years postoperatively during the study (Tamizi, 1996).

Cryosurgery: Tal *et al.* reported the use of a gas expansion cryoprobe cooled to -81oC and applied to the pigmented gingiva for 10 seconds. Gingiva was thawed spontaneously within 1 minute, and necrosis became apparent within 1 week. Healing and keratinization was complete within 3-4 weeks and depigmentation was successful 20 months postoperatively. The gaseous fluorocarbon tetrafluoroethane (TFE), used in the field of endodontics for cold pulp testing, is readily available and has also been tested for gingival melanin depigmentation (Tal *et al.*, 1985).

Cryosurgery vs Bur abrasion: Santosh Kumar *et al.* 2013 conducted a study for comparative evaluation of the gingival depigmentation by using Tetrafluoroethane cryosurgery and the gingival abrasion technique – 2 years of follow up. The study included 10 systemically healthy patients. The study suggested that the use of cryogen Tetrafluoroethane is easy, practical and inexpensive as compared to gingival abrasion, due to its high rate of recurrence. Hence, it is more acceptable to the patients and the operator (Santhosh Kumar, 2013).

Alloderm vs deepithelialization: Pontes *et al.* Compared the use of alloderm vs deepithelialization of the gingiva in fifteen patients." In the alloderm sites, partial thickness flaps were reflected and excised at the base, and the alloderm was sutured over the periosteum. In the contralateral sites, the connective tissue was denuded with a diamond bur. The authors reported superior results and minimal repigmentation in sites treated with alloderm 12 months postoperatively compared to deepithelialization (Pontes, 2006).

Systematic Review: Lin *et al.* 2014 conducted a systematic review for various treatment modalities used for depigmentation. The systematic review showed that cryosurgery exhibits the optimal predictability for depigmentation of the gingiva among all procedures examined, followed by electrosurgery and laser techniques (Lin, 2014).

Future Advances

Now- a-days newer non-invasive methods i.e. formulations are gaining their place which may decrease melanin pigmentation and lightens colour of skin as well as oral epithelium.

1. Kojic acid,
2. Placenta extract,
3. Vitamin C derivatives (Shimada, 2009)

Their intraoral formulations are still under research.

Conclusion

The aesthetic display of gingival is critical for a pleasant and confident smile. A variety of surgical techniques are available for the treatment of gingival melanin hyperpigmentation including free gingival grafts, dermal allografts, lasers, cryosurgery, scalpel method and bur abrasion method. Long term randomized controlled clinical trials are necessary to establish the effectiveness of these procedures.

REFERENCES

- Almas K, Sadiq W. Surgical Treatment of Melanin-Pigmented Gingiva: An Esthetic Approach. *Indian J Dent Res.* 2002; 13:70–3. [PubMed]
- Anil Kumar N, Divya P. Adverse drug effects in mouth. *International Journal Of Medical And Applied Sciences.* 2015; 4:82–91
- Barrett AW, Scully C. Human oral mucosal melanocytes: A review. *J Oral Pathol Med.* 1994; 23:97–103. [PubMed]
- Chin – Jyh. Yeh. Cryosurgical treatment of melanin-pigmented gingiva. *Oral Surg Oral Med Oral Pathol Oral Radiol Endod.* 1998;86(6):660–63. [PubMed]
- Cicek Y, Ertas U. The normal and pathological pigmentation of oral mucous membrane: A review. *J Contemp Dent Pract.* 2003; 4:76–86. [PubMed]
- Dummett CO, Bolden TE. Post surgical clinical repigmentation of the gingiva. *Oral Surg Oral Med Oral Pathol Oral Radiol Endod.* 1963;16:353–65
- Eisen D. Disorders of pigmentation in the oral cavity. *Clin Dermatol.* 2000; 18:579–87. [PubMed]
- Fowler EB, Breault LG, Galvin BG. Enhancing physiologic pigmentation utilizing a free gingiva! graft. *Pract Periodontics Aesthet Dent* 2000; 12:193–96.
- Greenberg M, Glick M. *Burkets oral medicine diagnosis and treatment.* 10th ed. Hamilton, Ontario: B. C. Decker; 2003. pp. 126–36.
- Gulati N, Dutt P, Gupta N, Tyagi P. Gingival Pigmentation: Revisited. *J Adv Med Dent Scie Res* 2016;4(1):48-57.
- Hirschfeld I, Hirschfeld L. Oral pigmentation and method of removing it. *Oral Surg Oral Med Oral Pathol Oral Radiol Endod.* 1951;4:1012.
- Kauzman A, Pavone M, Blanas N, Bradley G. Pigmented lesions of the oral cavity: Review, differential diagnosis, and case presentations. *J Can Dent Assoc.* 2004;70:682–3. [PubMed]
- Lin YH *et al.* Systematic review of treatment modalities for gingival depigmentation: a random-effects poisson regression analysis. *J Esthet Restor Dent.* 2014 May-Jun; 26(3):162-78
- Novaes AB Jr *et al.* he use of acellular dermal matrix allograft for the elimination of gingival melanin pigmentation: case presentation with 2 years of follow-up. *Practical Procedures & Aesthetic Dentistry: PPAAD* [01 Oct 2002, 14(8):619-23; quiz 624]
- Pal TK, Kapoor KK, Parel CC, Mukherjee K. Gingival melanin pigmentation – A study on its removal for esthetic. *J Indian Soc of Periodontology.* 1994;(special Issue 3):52–54.24.
- Pontes AE, Pontes CC, Souza SL, Novaes AB Jr, Grisi MF, Taba M Jr. Evaluation of the efficacy of the acellular dermal matrix allograft with partial thickness flap in the elimination of gingival melanin pigmentation. A comparative clinical study with 12 months of follow-up. *J Esthet Restor Dent* 2006, 18:135-43.
- Santhosh Kumar *et al.* Comparative Evaluation of Gingival Depigmentation using Tetrafluoroethane Cryosurgery and Gingival Abrasion Technique: Two Years Follow Up. *J Clin Diagn Res.* 2013 Feb; 7(2): 389–394.
- Sharon E, Azaz B. Vaporisation of melanin in oral tissues and skin with a CO2 laser: A canine study. *J Oral Maxillofac Surg* 2000; 58: 1387-1393.
- Shimada Y, Tai H, Tanaka A, Suzuki IL, Takai K, Yoshida Y, Yoshie H. Effects of ascorbic acid in gingival melanin pigmentation in vitro and in vivo. *J Periodontol* 2009; 80: 317-323.
- Tal H, Oegieesser D, Tal M. Gingival depigmentation by Er:YAG Laser. Clinical observations and patient's responses. *J Periodontol* 2003; 74: 1660-1667.
- Tal H, Stahl SS. Elimination of epithelium from healing postsurgical periodontal wounds by ultralow temperature - Initial observation. *JPeriodontol.* 1985;56(8):488–91. [PubMed]
- Tal Haim, Landsberg Jacob, Kozlovsky Avital. Cryosurgical depigmentation of the gingiva - A case report. *J Clin Periodontol.* 1987;14:614–17. [PubMed]
- Tamizi M, Taheri M. Treatment of severe physiologic gingival pigmentation with free gingival autograft. *Quintessence Int.* 1996 Aug; 27(8):555-8.

Tamizi M, Taheri M. Treatment of severe physiologic gingival pigmentation with free gingival autograft. *Quintessence Int.* 1996;27(8):555–58. [PubMed]

Trelles MA, Verkruyesse W, Segui JM, Udeata A. Treatment of melanotic spots in the gingiva by argon laser. *J Oral Maxillofac Surg.* 1993 July;51(7):759–61. [PubMed]
