



## CASE STUDY

### ASYMMETRIC UNILATERAL EXTRACTION

<sup>1</sup>Dr. Pinal Jain, <sup>2</sup>Dr. Prabhuraj B. Kambalyal and <sup>1</sup>Dr. Gaurav Sharma

<sup>1</sup>Department of Orthodontics and Dentofacial Orthopaedics, Pacific Dental College and Hospital, Udaipur

<sup>2</sup>Department of Orthodontics and Dentofacial Orthopaedics, Darshan Dental College and Hospital, Udaipur

#### ARTICLE INFO

##### Article History:

Received 23<sup>rd</sup> March, 2017

Received in revised form

19<sup>th</sup> April, 2017

Accepted 08<sup>th</sup> May, 2017

Published online 20<sup>th</sup> June, 2017

##### Key words:

Arch length – tooth material discrepancy,  
Arch asymmetries, Unilateral extraction,  
Borderline case.

Copyright©2017, Dr. Pinal Jain et al. This is an open access article distributed under the Creative Commons Attribution License, which permits unrestricted use, distribution, and reproduction in any medium, provided the original work is properly cited.

Citation: Dr. Pinal Jain, Dr. Prabhuraj B. Kambalyal and Dr. Gaurav Sharma, 2017. "Asymmetric unilateral extraction", *International Journal of Current Research*, 9, (06), 52023-52028.

#### ABSTRACT

Management of orthodontic cases often requires extraction of permanent teeth. The decision to extract the teeth or not depends upon the arch length tooth material discrepancies, the growth pattern, general profile, and arch asymmetries. Earlier, non-extraction approach or an approach involving the extraction of all four first premolars was the primary basis of treatment planning in orthodontics. However, an alternative orthodontic treatment modality involving the unilateral extraction of premolar in borderline cases has gained popularity nowadays. The present report describes a case with unilateral placed buccally blocked out canine and crowding in upper and lower arch, for which unilateral asymmetric premolar extractions were performed to achieve aesthetic and functionally stable occlusion.

#### INTRODUCTION

Obtaining a ideal relationship of the teeth with facial structures is the main objective of orthodontic treatment. Edward H. Angle emphasized that to achieve good facial balance, harmony and aesthetics, preservation of all dental units is necessary. However, in order to correct certain types of malocclusions and to maintain the stability of treatment, subsequent studies pointed the necessity of teeth extractions. While planning for extraction of the teeth, factors like the arch length-tooth material discrepancies, the growth pattern, general profile, and arch asymmetries should be taken into consideration. (Tayer, 1992) Also, the orthodontists should decide which tooth should be extracted for the best aesthetic/functional benefit of the patient. It has been suggested that asymmetric extractions correct midline deviation, favours unilateral movement of the posterior teeth, facilitate orthodontic mechanics and reduce treatment time, thus obtaining more stable and functional results. The orthodontist should have total control and knowledge of the mechanics used to achieve the best final results at the end of the treatment. (Melgaço et al., 2012; Gaur et al., 2016) The present case report describes a case with unilateral buccally blocked out canine and crowding in lower arch, for which unilateral asymmetric

premolar extraction was performed to achieve aesthetic and functionally stable occlusion.

#### Case report

A 13-year-old female presented with a chief complain of "irregularly placed upper and lower front teeth". Clinical examination revealed competent lips, a straight profile, and non-consonant smile arc. On clinical examination, the molar and canine relationships were Class I. She has crowding in upper and lower arch with buccally placed upper left canine and lingually inclined lower left second premolar. It was observed that maxillary and mandibular midline was shifted towards left. Model analysis revealed crowding of 7 mm in the both upper and lower arch. Patient has normal over jet and overbite.

#### Smile photograph of the patient

The cephalometric findings revealed a normodivergent growth pattern with a Class I skeletal base. An orthopantomogram was also recorded which showed erupting third molars in all four quadrants.

#### Treatment Objectives

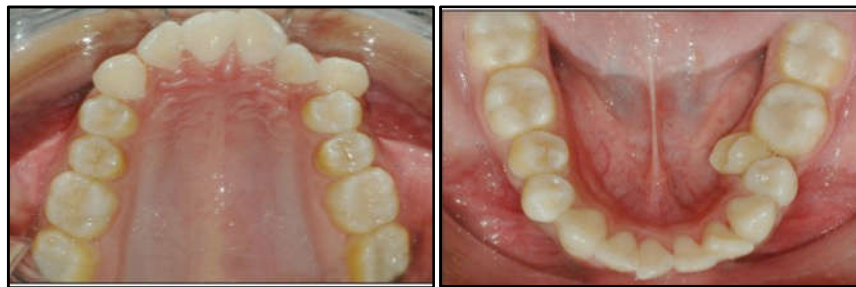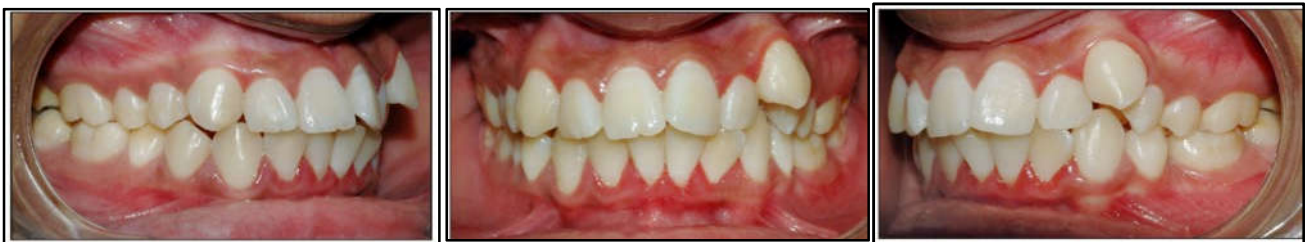1. Relieving of upper and lower anterior crowding.
2. Good and stable dentoalveolar changes.

\*Corresponding author: Dr. Pinal Jain,

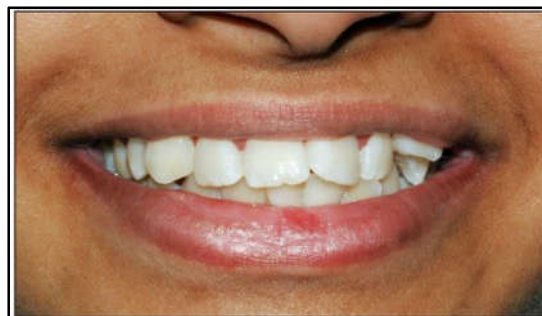Department of Orthodontics and Dentofacial Orthopaedics, Pacific Dental College and Hospital, Udaipur

3. Maintenance of class I canine and molar relation.
4. To achieve ideal over jet and overbite.
5. Maintenance of good profile.

- Initial alignment was done using 0.014 NiTi wire without involving the blocked out canine into the continuous wire and giving light tractional force to highly placed canine.



Pretreatment extra oral and intra oral photographs of the patient



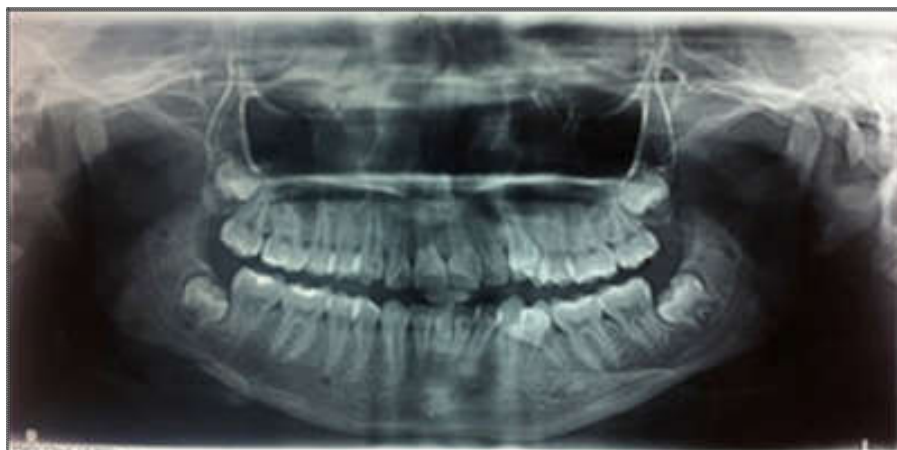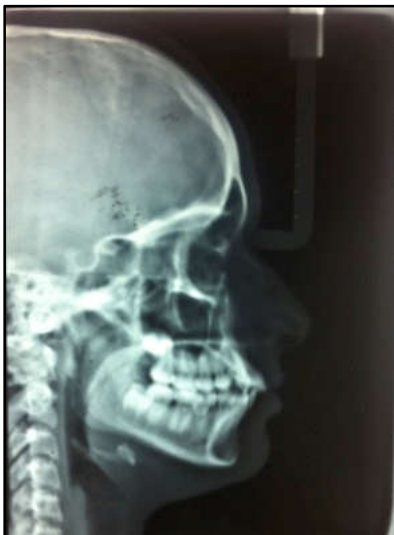Smile photograph of the patient

### Treatment Plan

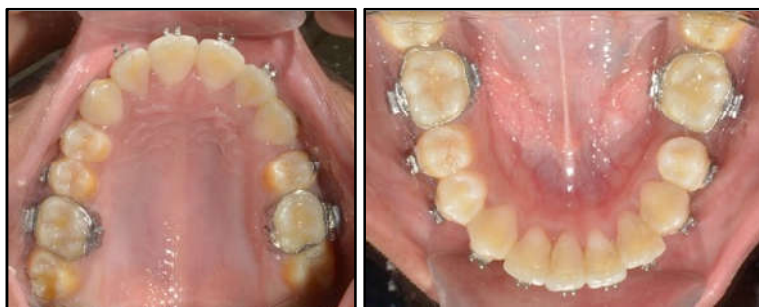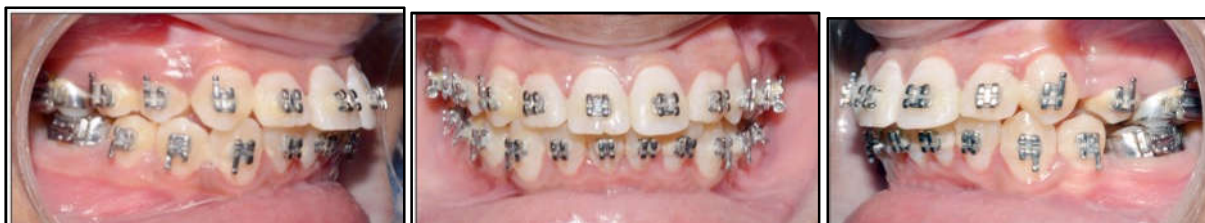On considering the diagnostic criteria, we planned to go with fixed mechanotherapy with unilateral asymmetric extraction of first premolar in upper arch (24) and second premolar in lower arch (35) and Proximal stripping on right side in both upper and lower arch was planned with alignment of dentition into the arches and correction of crowding in upper and lower arch.

### Treatment Progress

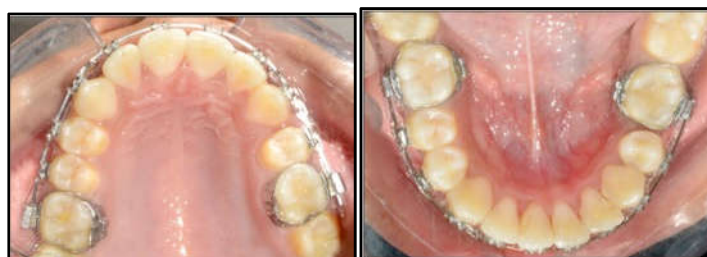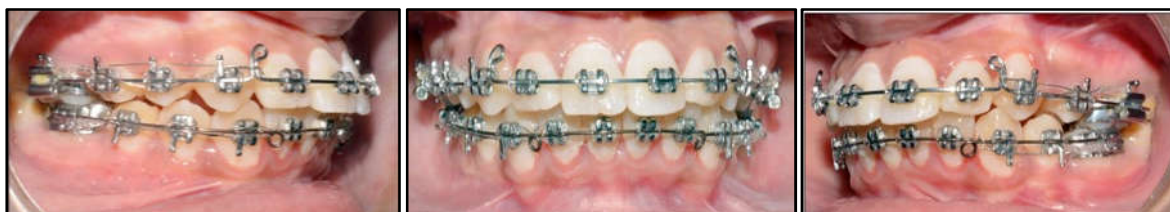- Preadjusted edgewise MBT.022 slot brackets were bonded in both arches.
- Anchorage reinforcement with transpalatal arch in upper and lingual arch in lower.
- After the canine was brought into arch 0.018 NiTi was placed followed by 0.018" stainless steel and leveling was done with 0.019"×0.025" NiTi.
- 0.019"×0.025" stainless steel was placed in the upper and lower arch for torque expression and closure of spaces.
- Second order bend was given for 11,12 and 21 on 0.016" x 0.022" SS wire for correcting tooth angulation.
- Settling of occlusion was done on 0.014 SS wire and M elastics with a tail.
- Total treatment duration of the patient was 18 months.



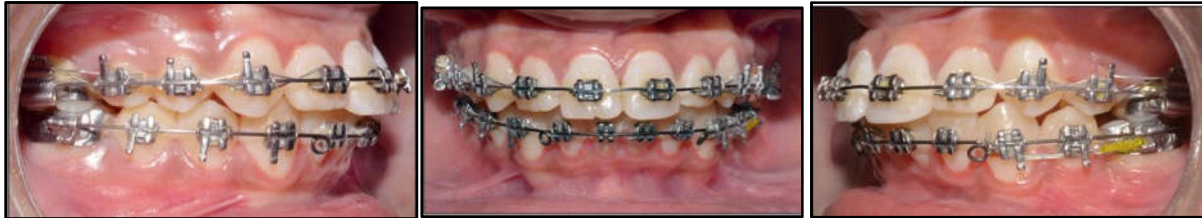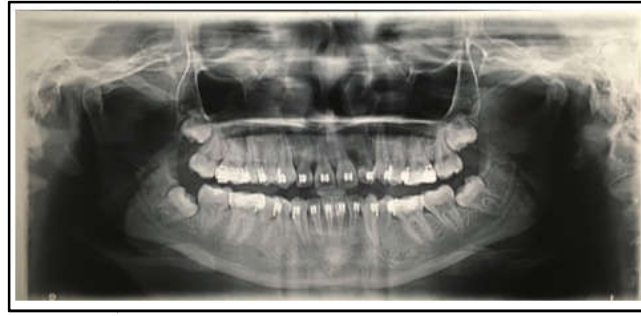Pre treatment radiographs (Lateral Cephalogram and OPG) of the patient



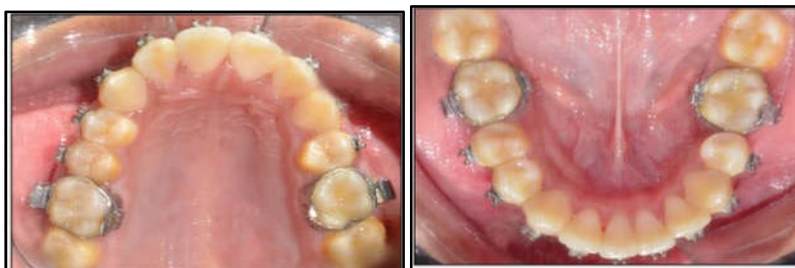
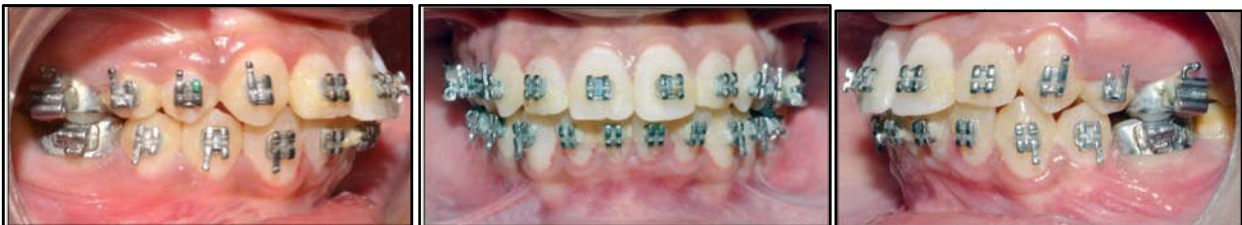After initial alignment and leveling



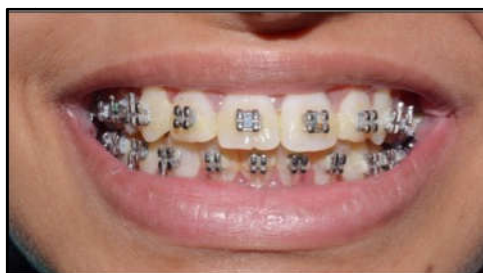Space closure done on 19\*25 SS in upper and 0.018 SS lower arch



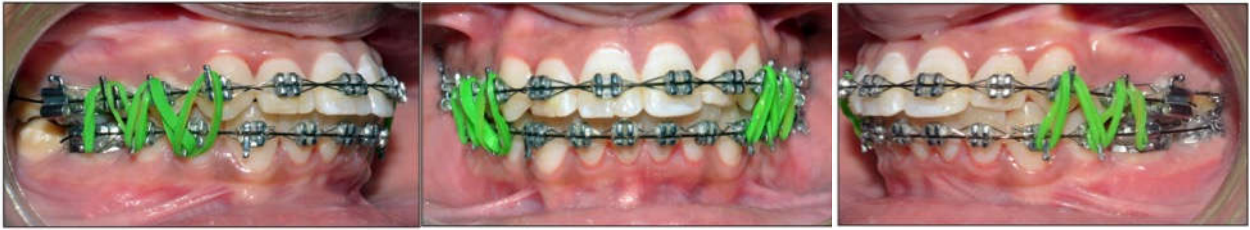
Repositioning was done for 11,21 and 12



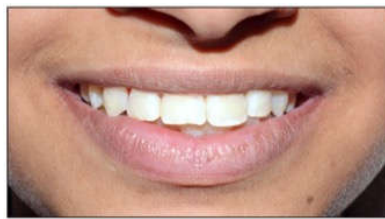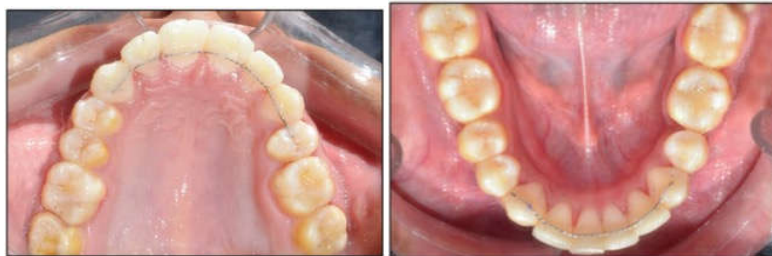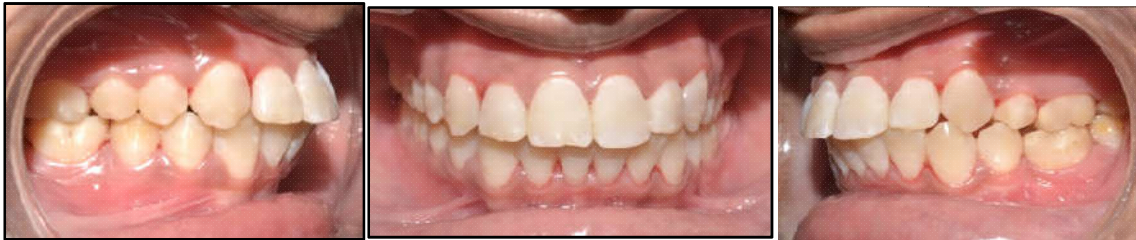Finishing stage



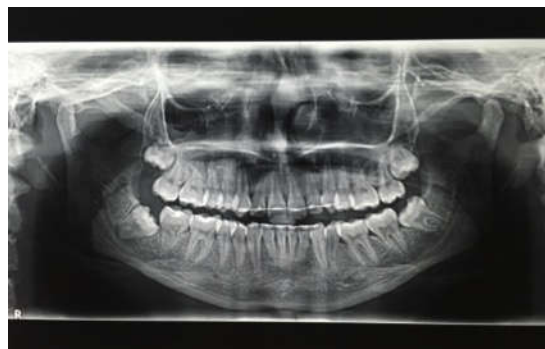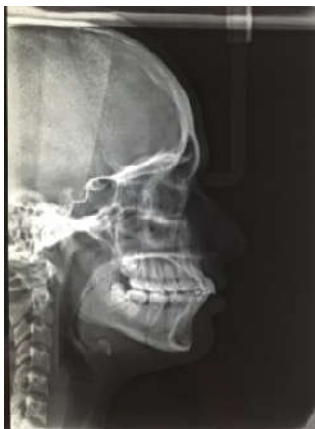Smile photograph of the patient



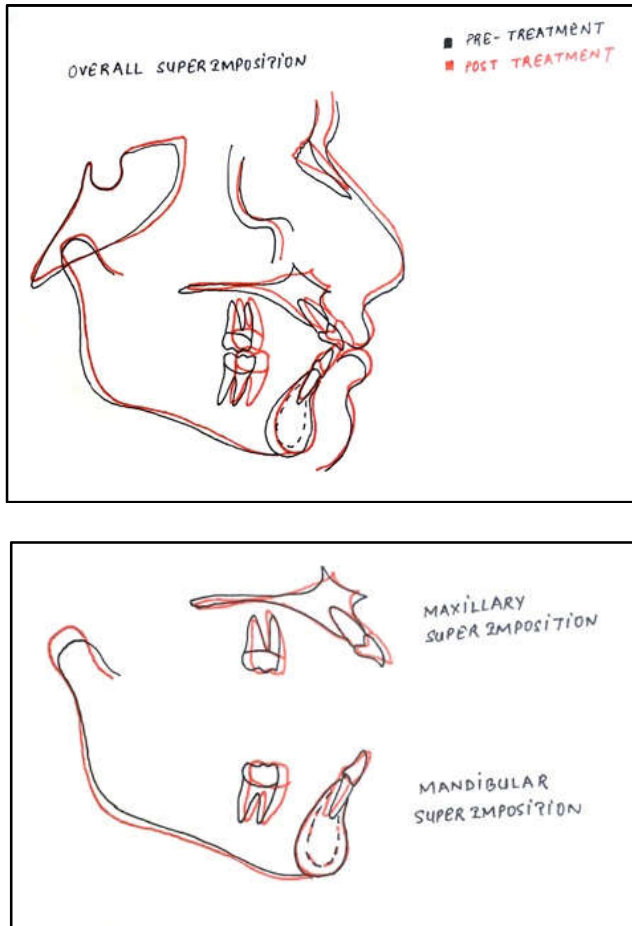
Settling (0.014 ss upper and lower arch with M with a tail elastics)



Post treatment



Post treatment (lateral cephalogram and OPG)



Cephalometric superimposition

### Treatment results

An ideal Class I occlusion was maintained in the patient with a positive overjet and overbite. The smile appearance improved and the esthetic profile of the patient was maintained. The main aim of the treatment was to maintain the straight profile of the patient with minimum possible extraction, giving her the stable occlusion, relieving the crowding.

Cephalometric measures	Pretreatment	Post treatment
SNA	80°	82°
SNB	77°	79°
ANB	3°	3°
N-A-POG	6°	7°
SN-GO-GN	28°	30°
FACIAL AXIS	94°	94°
U1-SN	119°	120°
L1-MP	100°	100°
U1-NA	38°, 7mm	38°, 7mm
L1-NB	31°, 7mm	32°, 7mm
NASOLABIAL ANGLE	105°	102°
LIP STRAIN	5 MM	5 MM

### DISCUSSION

The present case is of a non-growing female patient with buccally placed canine and crowding in upper and lower arch. Malocclusions with ectopically erupted canines are often treated by first premolar extractions. The extraction or non-extraction treatment plan for the patient is usually decided on the basis of the amount of arch length tooth material

discrepancy and the facial profile of the patient. According to Proffit and Fields (1995), extraction is rarely required in tooth size-arch length discrepancies below 4mm, whereas a discrepancy between 5 mm and 9 mm comes under borderline case. In our patient, the tooth size-arch length discrepancy was 7mm in the maxillary arch and 7 mm in the mandibular arch. Thus, it did not indicate extraction of all first premolars as is routinely followed in cases with ectopic canines. Furthermore, the facial profile of the patient is an important factor in determining the need for extractions. According to Ramos et al., the upper lip retracts by 0.75 mm and lower lip retracts 0.6 mm in 1 mm of retraction of the upper and lower incisor (Ramos et al., 2005; Kusnoto et al., 2001). Thus, space closure performed by retracting anterior teeth tends to render the profile more convex. In our case, the patient had a pleasing and straight profile. Thus, it did not indicate extraction of all four first premolars, which would have resulted in a retrusive profile. A treatment plan was devised such that space could be created for the blocked out canine along with midline correction. Extraction of premolar in the upper arch was performed on the same side of the buccally displaced canine for space creation and maintenance of a canine guided occlusion while in lower arch second premolar was extracted as it was completely blocked out. Highly placed canine should not be engaged in the continuous wire so as to avoid the intrusive side effect on the adjacent dentition. Once the canine is brought close to the occlusal plane, it can be aligned into the arch using continuous mechanics. Excessive midline shift can occur as a result of unilateral extractions; thus, coordination of midlines should be undertaken carefully in such cases.

### Conclusion

Unilateral extractions can give excellent aesthetic results with stable occlusion. Care must be taken to prevent midline shift and development of arch asymmetry during such treatment methods. An ideal Class I occlusion was maintained in the case with improved smile aesthetics while maintaining the pleasing profile of the patient.

### REFERENCES

- Gaur A, Maheshwari S, Verma SK, Mohd. Tariq. 2016. Orthodontic management of a borderline case with ectopic maxillary canine by unilateral premolar extractions. *Contemporary Clinical Dentistry*, 7(1):103-106.
- Kusnoto J. and Kusnoto H. 2001. The effect of anterior tooth retraction on lip position of orthodontically treated adult Indonesians. *Am J Orthod Dentofacial Orthop.*, 120:304-7.
- Melgaço, Camilo Aquino, and Mônica Tirre de Souza Araújo. 2012. "Asymmetric extractions in orthodontics." *Dental Press Journal of Orthodontics*, 17.2; 151-156.
- Proffit WR, Fields JR. 3rd ed. 1995. Rio de Janeiro: Guanabara Koogan; Contemporary Orthodontics.
- Ramos AL, Sakima MT, Pinto Ados S, Bowman SJ. 2005. Upper lip changes correlated to maxillary incisor retraction – A metallic implant study. *Angle Orthod.*, 75:499-505.
- Shroff B, Siegel SM. 1998. Treatment of patients with asymmetries using asymmetric mechanics. *Semin Orthod.*, 4(3):165-79.
- Tayer BH. 1992. The asymmetric extraction decision. *Angle Orthod.*, 62(4):291-7.

\*\*\*\*\*