



RESEARCH ARTICLE

MODIFIED A LINE: A NEW GUIDE TO POSITION MAXILLARY CENTRAL INCISOR

¹*Dr. Pallavi S. More, ²Dr. Amit Nehete, ³Dr. Nitin Gulve, ⁴Dr. Sheetal Patani and
⁵Dr. Shivpriya Aher

¹Post Graduate student, Dept. of Orthodontics and Dentofacial Orthopaedics, M.G.V.'s K.B.H.
Dental College and Hospital, Panchavati, Nashik- 422002

²Professor, Dept. of Orthodontics and Dentofacial Orthopaedics, M.G.V.'s K.B.H.
Dental College and Hospital, Nashik, India

³Professor and Head, Dept. of Orthodontics and Dentofacial Orthopaedics, M.G.V.'s K.B.H.
Dental College and Hospital, Nashik, India

⁴Professor, Dept. of Orthodontics and Dentofacial Orthopaedics, M.G.V.'s K.B.H.
Dental College and Hospital, Nashik, India

⁵Lecturer, Dept. of Orthodontics and Dentofacial Orthopaedics, M.G.V.'s K.B.H.
Dental College and Hospital, Nashik, India

ARTICLE INFO

Article History:

Received 11th April, 2018
Received in revised form
18th May, 2018
Accepted 15th June, 2018
Published online 30th July, 2018

Key words:

Maxillary Central Incisor,
Modified A line. Cephalometric Study.

ABSTRACT

Introduction - The aim of the study is to identify the ideal position of maxillary central incisor as defined by soft tissue thickness of the upper lip, using modified A-line. **Materials and methods**-30 standardized lateral cephalograms of adult orthodontically treated patients were studied. Patients with esthetically pleasing profile, competent lips, average growth pattern, ANB range in 2-4° and Angle's class I molar relationship were selected. Cephalometric landmarks were located and U1 position with respect to modified A line, A-Pog line, N-Pog line and SN plane was studied. **Results**-The mean value of U1 to modified A- line is -0.5mm. The observed mean values for U1 to A-Pog, U1 to N-Pog and U1 to SN plane are 5.98mm, 6.98mm and 103.78° respectively. **Conclusion**-The modified A- line, based on horizontal plane (HP) and soft tissue thickness of the upper lip at point A can be used as an objective cephalometric tool for positioning maxillary central incisor.

Copyright © 2018, Pallavi S. More, et al. This is an open access article distributed under the Creative Commons Attribution License, which permits unrestricted use, distribution, and reproduction in any medium, provided the original work is properly cited.

Citation: Dr. Pallavi S. More, Dr. Amit Nehete, Dr. Nitin Gulve, Dr. Sheetal Patani and Dr. Shivpriya Aher. 2018. "Modified a line: a new guide to position maxillary central incisor", *International Journal of Current Research*, 10, (07), 71382-71385.

INTRODUCTION

A person's ability to recognize a beautiful face is natural, but translating this into specific treatment goals is difficult. Artists and health professionals have attempted to define and recreate an ideal. With the advent of cephalometric radiographs, various analyses were developed in an attempt to qualitate and quantitate esthetic facial profiles. The cephalometric analysis has been used as the standard because of the ease of procuring, measuring, and comparing (superimposition) hard tissue structures and the belief that treating to cephalometric hard tissue norms results in an esthetic face. These perceived advantages of cephalometric analysis have led to reliance on cephalometry in all aspects of orthodontic treatment. For many years researchers have traced, measured and compared number of lines, angles and dimensions on head radiographs for evaluating the facial esthetics (Arnett, 1993).

*Corresponding author: Dr. Pallavi S. More

Post Graduate student, Dept. of Orthodontics and Dentofacial Orthopaedics, M.G.V.'s K.B.H. Dental College and Hospital, Panchavati, Nashik-422002

Case believed the facial outline should be regarded as an important guide in determining treatment when correcting a malocclusion. Angle related esthetics to the position of the maxillary incisor (Arnett, 1993). McNamara studied the cephalometric evaluation of incisor position. In evaluating facial beauty, Tweed, Steiner, Williams and Ricketts concentrated on the position and inclination of the mandibular incisors in relation to the basal bone. According to these authors, proper mandibular incisor positioning leads to stability of results. While many have studied the various features that might contribute to the stability of results and no association was found between proclination of lower incisors and instability. Holdaway and Creekmore concentrated on the position of maxillary incisors. According to Alvarez, if building the occlusion around the mandibular incisors offers neither stability nor predictable esthetics, perhaps it is time to reconsider a treatment-planning regimen based upon the maxillary incisors. Here we have evaluated the position of the maxillary central incisor using the modified A line along with

N-Pog line and U1 to SN plane in orthodontically treated patients.

Aim: To identify and define the position of the maxillary central incisors with respect to upper lip thickness using modified A-line and other commonly used measurements like A-Pog line, N-Pog line and SN plane.

MATERIALS AND METHODS

In this study, post treatment lateral cephalograms of the 30 adult patients treated in the department of the orthodontics were selected.

Selection criteria for the sample were as follow

- All exhibited esthetically pleasant profile with competent lips.
- Age range was 18 to 25 years.
- All exhibited average growth pattern.
- Angle ANB was 2-4°
- All exhibited Angle's class I molar relationship with average overjet and overbite.

The tracing of lateral cephalogram was done by single investigator and crosschecked.

The landmarks used in this cephalometric analysis are the following:

- Sella (S), the centre of the pituitary fossa.
- Nasion (N), the most anterior point of the nasofrontal suture in the midsagittal plane.
- Subspinale (A), the deepest point in the midsagittal plane between the anterior nasal spine and prosthion
- Pogonion (Pog), the most anterior point in the midsagittal plane of the contour of the chin.

The planes and lines used are:

- SN plane: plane formed by joining points Sella and Nasion.
- Horizontal plane (HP)⁴: it is a constructed plane, which is a surrogate Frankfort plane, constructed by drawing a line 7° from SN plane.
- A-Pog line: line drawn by joining point A and pogonion.
- N-Pog line: line drawn by joining points Nasion and pogonion.
- Modified A line²: This is marked by drawing a line parallel to the HP from point A on the maxilla to the soft tissue of upper lip, then divided into thirds. Modified A line is perpendicular to this line from one-third mark nearest osseous point A. (Refer Fig.)

Following linear and angular measurements were used.

- U1 to modified A line (linear)
- U1 to A-Pog line (linear)
- U1 to N-Pog line (linear)
- U1 to SN plane (angular)

RESULTS

For modified A line, the mean of the values obtained for the samples in this study was calculated. The calculated mean is -0.54 with standard deviation of 2.617709. To compare the observed values of U1 to A-Pog line with the expected mean value of 2.7 mm the 't' test for specified value of population mean is used at 95% confidence level and 29 degrees of freedom. Similarly the observed values of U1 to N-Pog line are compared with the mean expected value of 3 mm. Also, the angle between U1 to SN plane is compared with the expected average angle of 102°. The results obtained are shown in the Tables 1 and 2. Aesthetically it is expected that the mean value of U1 to A-Pog line should be 2.7mm. In the observed patients the values obtained are different and the difference between mean and observed values is statistically significant. Similarly the mean value of U1 to N-Pog line should be 3 mm. In the patients it is observed that there is significant difference between expected and observed. While for the value of U1 and SN plane (angular), obtained values are not statistically different from the established mean angle of 102°. Thus it can be seen that measurement U1 to A-Pog line differs from the expected mean value but the measurement U1 to N-Pog line does not differ from the expected mean value significantly.

DISCUSSION

With the paradigm shift, a soft-tissue profile esthetics play a significant role in modern orthodontics. Treatment methods are sometimes chosen or modified based on the goal of improving, or at least not compromising the esthetics.⁷ The discovery of a diagnostic method that can relate incisor position with the soft tissue it supports may encourage clinicians who would like to move away from diagnostic lines and angles based on osseous projections. Because the maxillary incisors support the upper and lower lips, they are one of the main determinants of profile acceptability that orthodontists can control with their therapies. Hence in this study position of the maxillary incisor is been evaluated for the esthetics and facial harmony (Alvarez, 2001). The greatest value of cephalometrics is in the field of comparative studies, such comparisons divulge and demonstrate changes that have occurred and strongly indicate responses to orthodontic therapy that has been employed. The lateral cephalogram provides information on the positions of the maxillary incisors, maxilla, mandibular incisors and mandible. The determination of incisor position is a part of most cephalometric analyses. Downs (1948, 1952 and 1956), Steiner (1953, 1959 and 1960), Tweed (1953 and 1954), Ricketts (1960, 1972 and 1981), Riedel (1952) and McNamara (1986) all present specific measures of incisor position (Ellis, 1986).

Various authors have studied the profile esthetics using the lateral cephalogram taken in natural head position as the best photographs from which to evaluate the profile are taken with the patient relaxed and looking straight ahead (Viazis, 1991; Viazis, 1991). Traditional cephalometric analyses use the sella-nasion or Frankfort horizontal planes as reference lines. A number of investigations have expressed concerns about the use of these planes. Ellis and McNamara have recommended the use of Frankfort horizontal line. But, reliance on numbers, lines, and angles has always held some diagnostic limitations for clinicians. The current diagnostic confusion has developed because of the unreliability of so many of our commonly taught systems.

Table 1.

Sr. No.	Measurement	Obtained Mean Values
1.	U1 to Modified A line	-0.5 mm
2.	U1 to A-Pog line	5.9833 mm
3.	U1 to N-Pog line	6.9833 mm
4.	U1 to SN plane	103.78°

Table 2.

Measurement	Established Norms (Downs, 1956; Alam, 2012; Graber, 1997)	Mean value	S.D.	S.E.	t value	p value	Remark
U1 to Modified A line		-0.5	2.617				
U1 to A-Pog line (linear)	2.7 mm	5.9833	2.065	0.3771	8.7057	0.000	Significant
U1 to N-Pog line (linear)	3mm	6.9833	2.916	0.5326	7.4797	0.000	Significant
U1 to SN plane (angular)	102°	103.783	6.575	1.2005	1.485	0.148	Insignificant

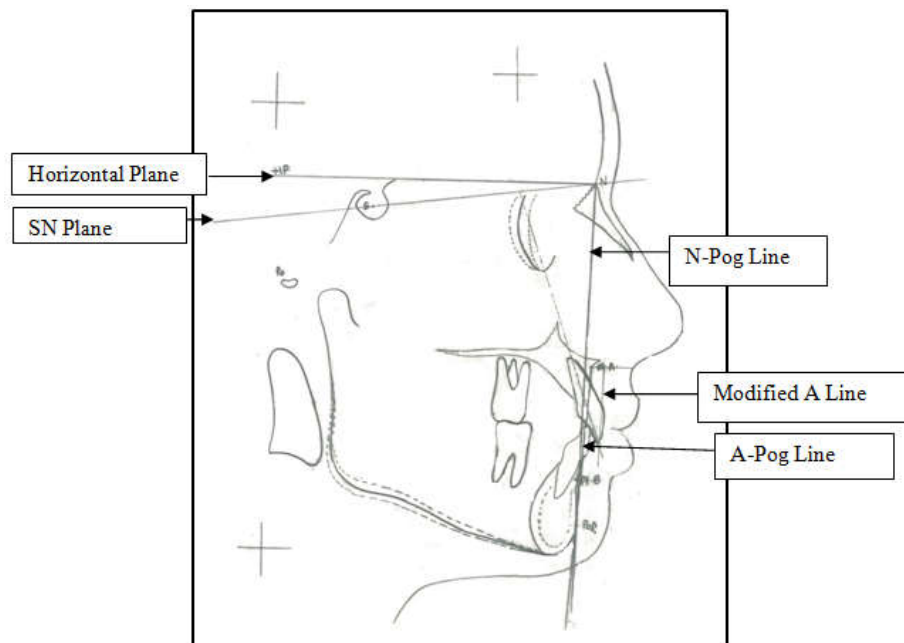


Figure 1. Modified a line

These systems often function well enough for patients who fall within a narrow range of “normal”, but are much less useful for those patients whose characteristics lie outside those restricted boundaries. Clinicians hesitate to use unfamiliar data, and that may explain their reluctance to endorse more recent diagnostic and treatment-planning guides (Alvarez, 2001). In this study, evaluation of the maxillary incisor position is done with the modified A line and other traditional measurements in 30 orthodontically treated cases. Modified ‘A’ line used in this study is the modification of the A line. The A line is originally suggested by Alfredo Alvarez (Alvarez, 2001). He used true horizontal as a horizontal reference plane to draw “A line” and suggested that this “A line” should touch or pass within 1 mm of the facial surface of the maxillary central incisor. In this study constructed horizontal plane (HP) (Burstone et al., 1978) is used hence we designate this line as Modified A line. As modified A line is used here, mean value was calculated for the samples. Results showed that the mean value for modified

A line is -0.54 mm (S.D. 2.62) in orthodontically treated patients with esthetically pleasing profile. This line takes into consideration the soft tissue thickness of the upper lip at point A. Very few studies have been done to include this criteria for the positioning of maxillary central incisor. As this line has used soft tissue thickness of upper lip at point A; it can allow clinician to position the maxillary central incisor more labially in case of thicker lips for harmonious results. Results with traditional measurements showed that the linear parameters U1 to A-Pog line and U1 to N-Pog line were significantly different than recommended mean values. This supports the opinion by earlier researchers that clinician can’t always rely on these parameters for positioning of maxillary central incisors. Whereas, the difference between the mean and observed values for the angle U1 to SN plane was statistically insignificant. As soft tissue thickness of the upper lip is considered, racial and gender factor can also be taken into consideration. There is a further scope for increasing the sample size to determine the

population. Also, the selection criteria for this study were concise. Hence it is suggested to further include samples of different skeletal growth patterns and Angle's class II, class III molar relationships and this new measurement should be reevaluated for them.

Conclusion

The modified A line, based on horizontal line and the soft tissue of the upper lip, emphasizes esthetic features that are important to both patient and doctor. This study shows that maxillary central incisors should be placed just behind (0.5mm) the modified A line for harmonious results. Hence it can be stated that the modified A line offers clinicians a more objective, predictable and useful diagnostic system for positioning maxillary central incisors.

REFERENCES

- Alam MK. 2012. Determining Cephalometric Norms for Bangladeshi Adults Using Bjork-Jarabak's Analysis. *Int Med J.*, 19(4):329-32.
- Alvarez AT. 2001. The A Line: A new guide for diagnosis and treatment planning. *J Clin Orthod.* 35: 556-69.
- Arnett GW, Bergaman RT. 1993. Facial keys to orthodontic diagnosis and treatment planning. *Am J Orthod Dentofac Orthop.* 103: 299-312.
- Burstone CJ, James RB, Lewgan H, Murphy GA, Norton LA. Cephalometrics for orthognathic surgery. *J Oral Surg* 1978; 36:269.
- Downs WB. 1956. Analysis of dentofacial profile. *Angle Orthod.*, 26:191-211.
- Ellis, E.1986. 3rd, McNamara JA Jr. Cephalometric evaluation of incisor position. *Angle Orthod.*, 56:324-44.
- Graber TM, Rakosi T, Petrovic AG. 1997. Dentofacial orthopedics with functional appliances. 2nd edition. Mosby-Year Book, St. Louis.
- Viazis AD. 1991. A cephalometric analysis based on natural head position. *J Clin Orthod.*, 25: 172-81.
- Viazis AD. 1991. A new measurement of profile esthetics. *J Clin. Orthod.*, 25:15-20.
