



ISSN: 0975-833X

## RESEARCH ARTICLE

### CASE REPORT-FAMILIAL CASE OF CROUZON'S SYNDROME WITH PRIMARY OPTIC ATROPHY

**1\*Dr. Atula Yadav, 2Dr. Dhan Singh Meena, 3Dr. Ashok Kumar Bairwa and 4Dr. Pooja Sharma**

<sup>1</sup>Resident, RNT Medical College, Udaipur

<sup>2</sup>Associate professor, RNT Medical College, Udaipur

<sup>3</sup>Professor & Head RNT Medical College, Udaipur

<sup>4</sup>Resident, RNT Medical College, Udaipur

#### ARTICLE INFO

##### Article History:

Received 16<sup>th</sup> July, 2017

Received in revised form

09<sup>th</sup> August, 2017

Accepted 19<sup>th</sup> September, 2017

Published online 31<sup>st</sup> October, 2017

##### Key words:

Craniosynostosis,  
Crouzon Syndrome,  
Familial,  
Mandibular Prognathism,  
Optic Atrophy.

#### ABSTRACT

This report and review of literature aimed to report a rare case of Familial Crouzon syndrome with primary optic nerve atrophy. It is characterized by premature closure of cranial sutures, cranial deformities, midface hypoplasia, relative mandibular prognathism, hypertelorism, proptosis, strabismus and short upper lip, crowding of teeth and primary optic atrophy. We hereby report a familial case of a 16yr old girl and her father along with pedigree analysis of the trait. Our patient showed characteristic features of Crouzon syndrome and was reported very late though had signs of raised intracranial pressure with primary optic atrophy.

*Copyright©2017, Atula Yadav et al. This is an open access article distributed under the Creative Commons Attribution License, which permits unrestricted use, distribution, and reproduction in any medium, provided the original work is properly cited.*

**Citation: Dr. Atula Yadav, Dr. Dhan Singh Meena, Dr. Ashok Kumar Bairwa and Dr. Pooja Sharma, 2017. "Case report-Familial case of Crouzon's syndrome with primary optic atrophy", International Journal of Current Research, 9, (10), 59248-59250.**

## INTRODUCTION

Crouzon's syndrome (CS) was described as one of the varieties of craniosynostosis caused by premature obliteration and ossification of two or more sutures. In 1912 a French neurologist, Octave Crouzon (1874-1938) first described a hereditary syndrome of craniofacial dysostosis in a mother and her daughter which included a triad-cranial deformities, facial anomalies and exophthalmos (Crouzon, 1921). It may be transmitted as an autosomal dominant inheritance but 25% of cases represent a fresh mutations (Al-Qattan, 1997). It accounts for approximately 4.8% of all cases of craniosynostosis with the prevalence of approximately 1 per 25,000 live births worldwide and has no sex or race predilection (Bowling, 2006; Kaur et al., 2006; Cohen, 1987). It is characterized by deformities of skull, facial hypoplasia and ocular proptosis. More than 90% of cases occur due to mutations in fibroblast growth factor gene (FGFR2) (Malcolm et al., 1996). The most common ocular abnormalities are shallow orbits, ocular proptosis, hypertelorism, strabismus, papilloedema, optic atrophy, exposure keratitis and visual loss.

Oral abnormalities include short upper lip, hypoplastic maxilla, relative mandibular prognathism, cleft palate and bifid uvula<sup>7</sup>. Various test like MRI, genetic testing, X-rays and CT-scans can be used to confirm the diagnosis. Management of such patients requires multidisciplinary approach and early diagnosis is important. Increased intracranial pressure leading to optic atrophy may occur, which produce blindness if the condition is not treated.

#### Case description

A 16 year-old girl accompanied with her parents presented to our departmental OPD with complaint of diminution of vision and outward protrusion of both eyes since birth. Since the girl's facial appearance was not normal, family and medical history was taken in detail. Review of medical history was unremarkable, specifically, the mother reported normal labor and delivery. Parents notice abnormal shape of skull at the time of birth. There was no history of consanguinity in parents. Patient's father and some other members of paternal family had history of similar facies as depicted in pedigree analysis.

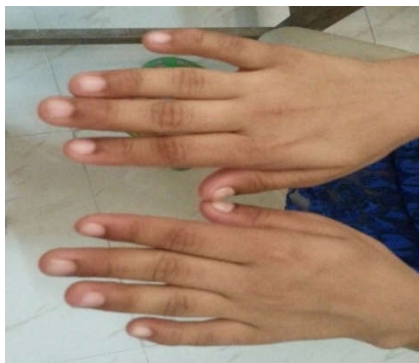**General examination:** Enlarged cranial vault with frontal bossing, maxillary hypoplasia and a relative mandibular

\*Corresponding author: Dr. Atula Yadav,  
Resident, RNT Medical College, Udaipur.

prognathism, short upper lip due retruded maxilla, under developed malar prominence was found (Fig.1). Her hands and feet found to be normal. Syndactyly was absent (Fig.2). No obvious dermatological finding such as acanthosis nigricans was observed

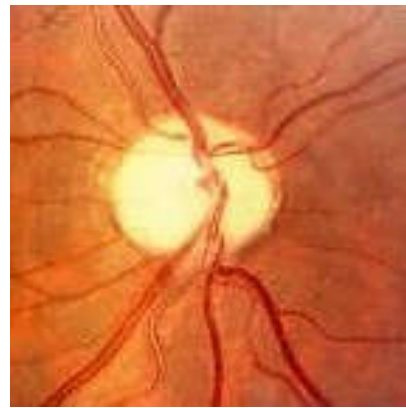
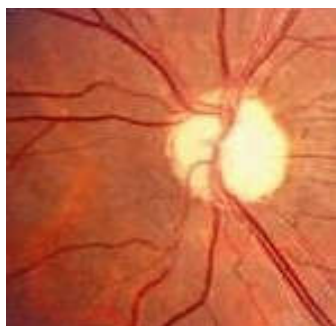


**Fig.1:** (a)Front and (b) Profile view of face showing ocular proptosis, strabismus, hypertelorism, mid facial hypoplasia, maxillary deficiency with relative prognathism



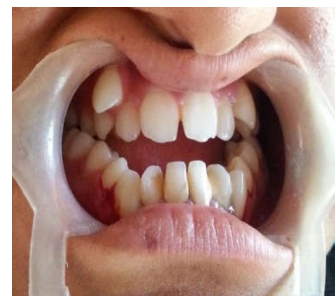
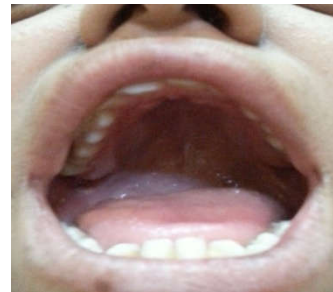
**Fig.2:** No syndactyly

**Ocular examination:** Visual acuity was Counting Finger (CF) 1 Ft in both eye. Ocular manifestations such as shallow orbits, hypertelorism, bilateral proptosis, and strabismus were present (Fig.1). Fundus examination revealed bilateral optic atrophy (Fig.3)

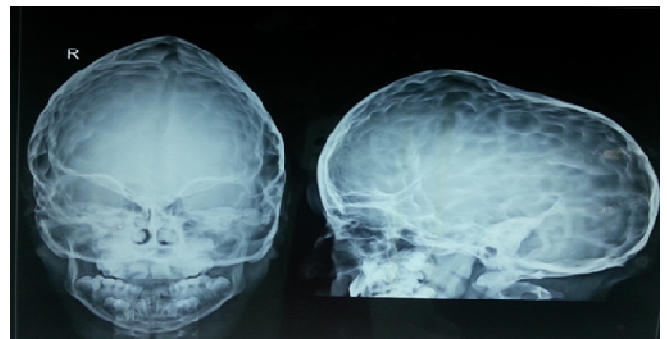


**Fig.3:** Primary optic atrophy both eyes

**Intraoral examination:** high-arched palate and , retruded maxilla with a relatively large mandible were found. Her oral hygiene was poor with crowding of upper and lower teeth, malocclusion of teeth class-III (Fig.4).



**Fig.4.** intraoral examination shows high-arched palat, crowding and malocclusion of teeth.



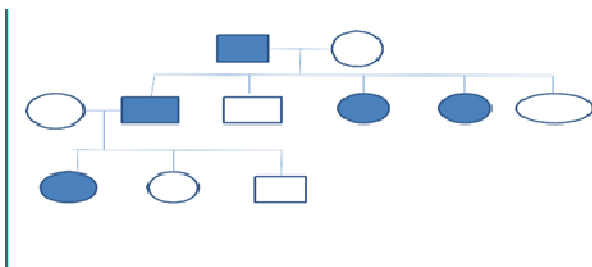
**Fig. 5.** Skull is pointed at vertex, maxillary sinuses appear hypoplastic, lateral skull radiograph showed beaten metal appearance

**Radiographic examination:** Revealed presence of supernumerary teeth with misalignment. skull is pointed at vertex known as turricephaly. Bilateral maxillary sinuses appear hypoplastic or small in size. The lateral skull radiograph showed beaten metal appearance secondary to raised ICT (Fig.5)

Patient was accompanied by her father who also showed typical facial features. Father had mild proptosis, midfacial hypoplasia and relative mandibular prognathism (Fig.6). Mother was normal and couple's elder son and daughter also had no such features. Patient's paternal family had history of similar facies as depicted in pedigree analysis. (Fig.7) Pedigree showing the trait depicted as dark paternal family of patient.



**Fig. 6. Father's front and profile view showing proptosis, midfacial hypoplasia and mandibular prognathism**



**Figure 7. Pedigree analysis**

## DISCUSSION

The differential diagnosis of Crouzon syndrome includes Apert syndrome, Saethre-Chatzen syndrome, Carpenters syndrome, Pfeiffer syndrome. There is lack of hand or foot abnormalities in Crouzon's syndrome which distinguish it from other craniosynostosis syndromes (Regezi, 1999). The correct identification of a craniosynostosis syndrome necessitates an extensive physical and radiographic examination to detect all the associated anomalies. Craniosynostosis commonly begins during the first year of life and is usually completed by the age of 2–3 years (Gorlin, 1997). Premature fusion of synchondroses of cranial base, subsequent lack of bone growth

perpendicular to the synchondroses and cranial base produces characteristic cranial shapes like brachycephaly, trigonocephaly, and scaphocephaly. Exophthalmosis is stated to be a prerequisite for Crouzon syndrome (Singer, 1997; Pharaoh, 2005) and is said to be caused by a lack of forward sutural growth in the temporal and cranial base region. This produces a relative prominence of eyeball, which sometimes results in blindness due to increased intracranial pressure. The cases reported above showed prominent exophthalmosis with decreased vision. In Crouzon syndrome, maxilla is hypoplastic which causes relative mandibular prognathism. Underdevelopment of maxilla is most severe in premaxillary area, causing crowding in the maxillary anterior teeth region. Both of our cases showed these features. Cranial markings, a normal finding in growing individuals, are seen more prominently in patients with Crouzon syndrome because of increased intracranial pressure from the growing brain.<sup>10,11</sup> These markings may be seen as multiple radiolucencies giving a beaten metal appearance in the periphery, which was classically seen in our case (Singer, 1997; Pharaoh, 2005). By the early recognition of the syndrome, the sutures can be guided before their fusion or artificial sutures can be placed to allow for the growth of brain.

## Conclusion

Early detection of Crouzon syndrome and prevention of ocular complications is required to reduce the associated visual loss as optic atrophy remains an important cause of visual impairment in these patients. Timely decompression may prevent optic neuropathy and any visual loss.

## REFERENCES

- Al-Qattan, M.M., Phillips, J.H. 1997. Clinical features of Crouzon's syndrome patients with and without a positive family history of Crouzon's syndrome. *J Craniofac Surg.*, 8(1):11–13.
- Bowling, E.L., Burstein, F.D. 2006. Crouzon syndrome. *Optometry.* 77(5):217–222.
- Cohen, M.M., Jr 1988. Craniosynostosis update 1987. *Am J Med Genet Suppl.* 4:99–148.
- Crouzon O. 1921. Dysostose cranio-faciale hereditaire. *Bull Mem Soc Med Hop Paris.* 33:545–555.
- Gorlin, R.J., Cohen, N.M. Jr, Hennekam, R. 2001. Syndromes of Head & Neck. 4th ed. pp. 658–9.
- Hlongwa, P. 2009. Early orthodontic management of Crouzon Syndrome: A case report. *J Maxillofac Oral Surg.*, 8:74–6.
- Kaur, H., Waraich, H.S., Sharma, C.M. 2006. Crouzon syndrome: A case report and review of literature. *Indian J Otolaryngology Head Neck Surg.*, 58(4):381–382.
- Malcolm, S., Reardon, W. 1996. Fibroblast growth factor receptor-2 mutations in craniosynostosis. *Ann NY Acad Sci.* 1996; 785:164–70. doi: 10.1111/j.1749-6632.tb56255.x.
- Pharaoh, W. 2005. Oral radiology principles & interpretation. 5th ed. Mosby: Elsevier.
- Regezi, J.A., Sciubba, J.J. 1999. 4th ed. Philadelphia: W.B. Saunders co. Oral pathology–Clinical pathologic correlations; pp. 477–8.
- Singer, S.L., Walpole, I., Brogan, W.F., Goldblatt, J. 1997. Dentofacial features of a family with Crouzon Syndrome. Case reports. *Aust Dent J.*, 42:11–7.