



RESEARCH ARTICLE

MALIGNANT MELANOMA OF THE ORAL CAVITY: A CASE REPORT

¹Dr. Pradeep Christopher, ²Dr. Senthilnathan, K.P., ³Dr. Poorna Devadoss and
^{*4}Dr. Santhosh Kumar, M.P.

¹Professor, Department of Oral & Maxillofacial Surgery, Thai Moogambigai Dental College, Chennai, Tamilnadu

²Professor, Department of Oral & Maxillofacial Surgery, Saveetha Dental College, Chennai, Tamilnadu

³Reader, Department of Orthodontia, Thai Moogambigai Dental College, Chennai, Tamilnadu

^{*4}Reader, Department of Oral & Maxillofacial Surgery, Saveetha Dental College, Chennai, Tamilnadu

ARTICLE INFO

Article History:

Received 22nd July, 2017

Received in revised form

07th August, 2017

Accepted 27th September, 2017

Published online 17th October, 2017

Key words:

Malignant melanoma,
Hyperpigmentation, Hard palate,
Oral cavity, Maxillary gingival.

ABSTRACT

Malignant melanoma of the oral cavity is a very rare clinical entity. We report a case of 40 year old male patient who presented with a pigmented growth in anterior maxillary palatal region. Clinical features, Histopathological findings and Immunohistochemical studies were consistent with the diagnosis of malignant melanoma. Malignant melanoma of the oral cavity has very poor prognosis, because of its rapid tendency for regional and distant metastasis and multiple local recurrences after surgical excision. Early diagnosis and aggressive treatment improves prognosis. Complete excision with adequate negative margins is the treatment of choice. Our patient was planned for surgical removal of the entire primary lesion with neck dissection for regional lymph node metastasis followed by chemotherapy with Dacarbazine. Owing to the rarity of the lesion, In this article we present and discuss a case of oral malignant melanoma in the hard palate.

Copyright©2017, Dr. Pradeep Christopher et al. This is an open access article distributed under the Creative Commons Attribution License, which permits unrestricted use, distribution, and reproduction in any medium, provided the original work is properly cited.

Citation: Dr. Pradeep Christopher et al. 2017. "Malignant melanoma of the oral cavity: A case report", *International Journal of Current Research*, 9, (10), 58799-58802.

INTRODUCTION

Oral malignant melanomas are rare neoplasm arising from melanotic cells that are present in the basal layer of the oral mucosa. Oral mucosal melanomas were first described by Weber in 1859. They represent less than 2% of all melanomas with approximately 0.05% of all oral malignancies. 55% of mucosal melanomas occur in the head and neck region (Hicks and Flaitz, 2000). Though their occurrence is very less when compared to cutaneous melanomas, they are very aggressive tumours with poor prognosis. Cutaneous melanomas may present with horizontal or vertical growth pattern, whereas oral melanomas usually presents typically with vertical growth, thus spreading to contiguous sites early (Östman et al., 1995). Incidence of oral malignant melanoma is higher in India, Japan and Africa than in Western countries and is common in males (Takagi et al., 1974; Broomhall and Lewis, 1967). Most cases occur between the fourth and the seventh decade of life, with an average of 55-75 years and are extremely rare below 30 yrs (Rapini et al., 1985). Primary sites of occurrence are hard palate (40%) followed by maxillary gingiva. Less common locations in order of decreasing incidence are buccal mucosa,

mandibular gingiva, lips, tongue and floor of the mouth (Snow et al., 1986). Most of the available information about Oral malignant melanoma is from a small series of cases owing to the rarity of this lesion. Hence the knowledge of features of this pathology from a larger data will be of greater meaning in understanding this lesion and formulating a strategical treatment protocol for better prognosis. Thus in this report, we discuss a case of primary oral malignant melanoma of hard palate in a 40 year old male.

CASE REPORT

A 40 year old male patient reported to a Private Dental Hospital in Chennai, with a chief complaint of pain and swelling over the upper front tooth region. Swelling was present since past 6 months which was gradually increasing in size and pain since past 15 days. There was no significant past medical history and past surgical history. Patient had no previous personal or familial history of primary oral or cutaneous melanoma. Patient gave a history of smoking, drinking, tobacco and pan chewing for the past two decades. Extraoral swelling was seen on the maxillary anterior region. Intraoral examination revealed a pigmented growth of 2*2 cm in size in anterior portion of the hard palate extending from 14 region to 23 region, crossing the midline [Fig 1]. It was bluish-

*Corresponding author: Dr. Santhosh Kumar, M.P.

Saveetha Dental College and hospital, Saveetha University, 162, Poonamallee high road, Velappanchavadi, Chennai, Tamilnadu 600077 India.

black in colour, ulcerated with irregular borders, soft in consistency with mild bleeding and tender on palpation. On physical examination, no clinically atypical or suspicious nevi were observed on the skin or scalp. Teeth in the area of growth were mobile and in malocclusion. On palpation of the neck, enlarged regional lymph nodes were detected. Based on the history and clinical features, the lesion was provisionally diagnosed as primary mucosal malignant melanoma involving the hard palate. Routine blood investigations were done which were within normal limits. Incisional biopsy was done and histopathology report confirmed the diagnosis of malignant mucosal melanoma. Immunohistochemical analysis revealed that the lesion was positive for HMB-45, Melan-A, S-100 further confirming the diagnosis of malignant melanoma. Computerized tomography [CT] scan revealed the extent of lesion in maxilla in all the planes with bony destruction and showed presence of regional lymph node involvement [Fig 2, Fig 3].

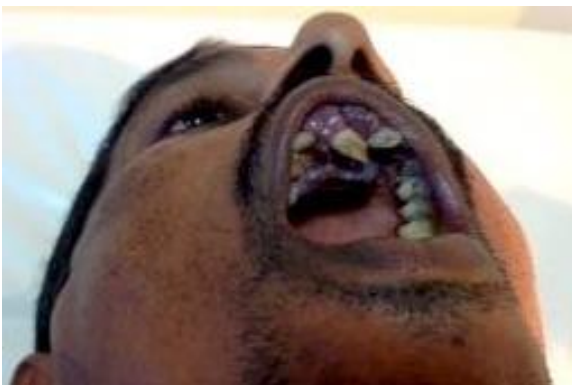

Fig. 1. Intraoral view of melanoma

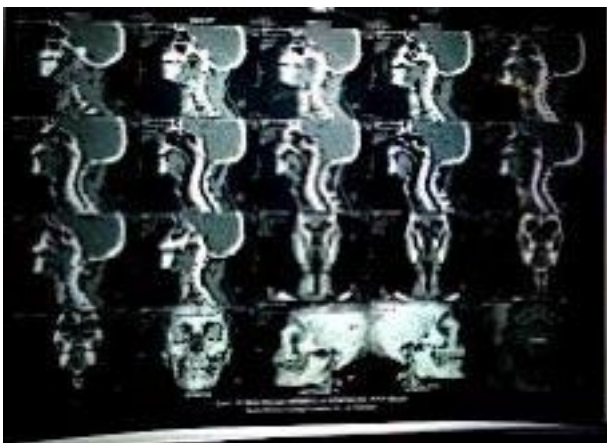

Fig. 2. Sagittal section of CT Scan showing lesion in maxilla

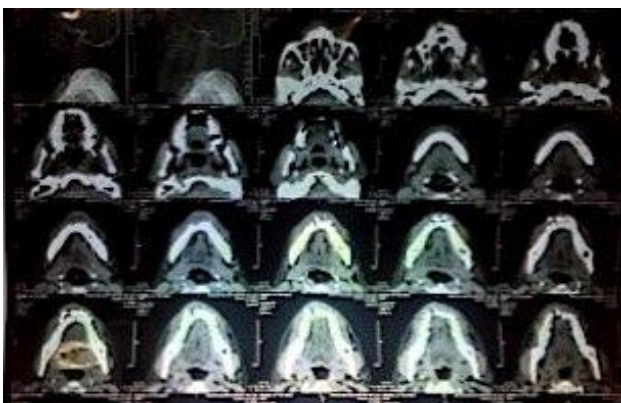


Fig. 3. Axial section of CT Scan showing lesion in maxilla

Chest x-ray examination excluded metastases in the lungs. The patient was planned for surgical removal of the entire primary lesion with neck dissection for regional lymph node metastasis followed by chemotherapy with Dacarbazine.

DISCUSSION

Etiology of oral malignant melanoma is unknown, although risk factors identified are tobacco, betel nuts, mechanical trauma from ill-fitting dentures and formaldehyde /nitrosamine exposure (Gu *et al.*, 2003). Our patient has a long history of smoking, tobacco and pan chewing. Oral melanomas can occur in normal mucosa or may arise from pre-existing pigmented [melanotic] areas (Takagi *et al.*, 1974). Based on clinical appearance Tanaka *et al.* classified oral malignant melanoma into five types: pigmented nodular, non-pigmented nodular, pigmented macular, pigmented mixed and non-pigmented mixed (Tanaka *et al.*, 2001). It can be solitary or multiple. The colour varies from bluish-black to tan brown (Tanaka *et al.*, 1994) or it can be amelanotic (Notani *et al.*, 2002). In our case the pigmented growth was seen in hard palate which is the most common site for the occurrence of malignant melanoma in the oral cavity. The lesion is asymptomatic in early stages, which contributes for the delay in diagnosis. Manifestations present in advanced lesions are bleeding, pain, swelling, growth, ulceration, extensive destruction of the underlying bone and loosening of teeth which makes the patient seek for treatment (Meleti *et al.*, 2007). However prognosis is poor at this stage and our patient had all these clinical features. Mucosal melanoma can be primary or metastatic. According to the criteria given by Greene *et al.* (1953) for the diagnosis of primary oral mucosal melanoma, our case was a primary lesion as we could not identify any melanoma elsewhere in the body.

Oral malignant melanoma resembles many other pigmented lesions of the oral cavity. Differential diagnosis for oral melanomas includes oral melanotic macule, smoking-associated melanosis, melanoplakia, pituitary-based Cushing's syndrome, post inflammatory pigmentation, melanocanthoma, melanocytic nevi of the oral mucosa, blue nevi, spitz nevi, Addison's disease, Peutz-Jeghers syndrome, neurofibromatosis, polyostotic fibrous dysplasia, amalgam tattoo, Kaposi's sarcoma and physiologic pigmentation (Femiano *et al.*, 2008; Pour *et al.*, 2008). Histopathological report is the key to the confirmation of the malignant melanoma. We performed an incisional biopsy which confirmed the diagnosis of mucosal malignant melanoma. Oral malignant melanoma is histologically classified into 1) in situ melanoma 2) invasive melanoma 3) combination of invasive melanomas with an in situ pattern (Barker *et al.*, 1997). Due to varied histomorphology of oral malignant melanoma, additional Immunohistochemical analysis becomes essential for confirmation of the pathology. S-100 a sensitive marker, Melan-A, tyrosinase or HMB45 which are more specific markers can confirm the diagnosis (Ohashi *et al.*, 1992; Umeda *et al.*, 2002). In our case all these markers were positive for the lesion. We used CT scans, chest X-ray to explore the extension of the lesion and to rule out metastasis. CT scan showed presence of regional lymph node involvement, hence categorized as stage II lesion (Prasad *et al.*, 2004). The primary mode of treatment is surgical excision with at least 1cm safety margins and adjuvant chemotherapy (Notani *et al.*, 2002). Other adjuvant therapies include immunotherapy and radiotherapy. Ipilimumab is now approved by the US food and drug administration (FDA) for unresectable or metastatic

melanoma (Hodi *et al.*, 2010). Vemurafenib is recommended for patients with untreated metastatic melanoma (Chapman *et al.*, 2011). Although oral malignant melanomas are not radio-sensitive, radiation therapy can be used when surgery is contraindicated in medically compromised patients or after surgery if adequate margins cannot be achieved (Pour, 2008). Lymph node dissection must be done along with excision of primary tumour when there is nodal involvement. Chemotherapy should always be considered as a supplemental treatment with surgery to achieve better prognosis (Umeda and Shimada, 1994). Many chemotherapeutic agents have been used for malignant melanomas but Dacarbazine was reported to have the best response rate. Since this tumour is very aggressive, multimodal treatment is necessary to prevent recurrence and metastasis. Hence our patient was planned for surgical removal of the entire primary lesion with neck dissection for regional lymph node metastasis followed by chemotherapy with Dacarbazine. Periodic long-term follow up is essential as recurrences can occur even after 10-15 years (Aggarwal *et al.*, 2016). Prognosis of oral melanoma are very poor compared to cutaneous melanomas and other oral cancers. Regardless of location, the prognosis for oral melanomas is poor, with an overall 5-year survival rate of 15% (Hicks and Flaitz, 2000). Reasons attributed are delay in diagnosis, difficult anatomy, increased vascularity of the oral mucosa, aggressive biologic behaviour of the oral malignant melanoma and absence of standardized treatment protocols due to rarity of this disease. Important factors governing prognosis are tumour thickness, regional lymph node dissemination and distant metastasis (Meleti *et al.*, 2007). In our case there was regional lymph node metastasis, hence prognosis will be poor even after surgical removal with adequate margins. From the review of literature, it is evident that early detection and lifelong periodic follow-up of oral malignant melanoma is important in the management of this aggressive neoplasm (Kaul and Kumar, 2013).

Conclusion

Oral malignant melanoma resembles many other pigmented, non-malignant lesions of the oral cavity. Hence any pigmented lesion in the oral cavity must be seriously looked upon and biopsied to rule out malignancy. Oral mucosal malignant melanoma is more aggressive and has grave prognosis than cutaneous malignant melanoma. Since they are asymptomatic, early diagnosis and aggressive management are vital for improving prognosis of the patients. Owing to rarity of these lesions, definite treatment protocols are lacking. Thus, multimodal therapy would be the best option. Despite of multimodal treatment, oral malignant melanoma has poor prognosis and less survival rate.

REFERENCES

- Aggarwal H, Kumar P, Alvi HA. 2016. Significance of follow-up surveillance in oral malignant melanoma. *South Asian Journal of Cancer*, 5(1):32.
- Barker BF, Carpenter WM, Daniels TE, Kahn MA, Leider AS, Lozada-Nur F, Lynch DP, Melrose R, Merrell P, Morton T, Peters E. 1997. Oral mucosal melanomas: The WESTOP Banff workshop proceedings. *Oral Surgery, Oral Medicine, Oral Pathology, Oral Radiology, and Endodontology*, Jun 30;83(6):672-9.
- Broomhall, C, Lewis MG. 1967. Malignant melanoma of the oral cavity in Ugandan Africans. *British Journal of Surgery*, 1;54(7):581-4.
- Chapman PB, Hauschild A, Robert C, Haanen JB, Ascierto P, Larkin J, Dummer R, Garbe C, Testori A, Maio M, Hogg D. 2011. Improved survival with vemurafenib in melanoma with BRAF V600E mutation. *New England Journal of Medicine*, 30;364(26):2507-16.
- Femiano F, Lanza A, Buonaiuto C, Gombos F, Di Spirito F, Cirillo N. 2008. Oral malignant melanoma: a review of the literature. *Journal of oral pathology & medicine*, 1;37(7):383-8.
- Greene GW, Haynes JW, Dozier M, Blumberg JM, Bernier JL. 1953. Primary malignant melanoma of the oral mucosa. *Oral Surgery, Oral Medicine, Oral Pathology*, 1;6(12): 1435-43.
- Gu GM, Epstein JB, Morton TH. 2003. Intraoral melanoma: long-term follow-up and implication for dental clinicians. A case report and literature review. *Oral Surgery, Oral Medicine, Oral Pathology, Oral Radiology, and Endodontology*, 31;96(4):404-13.
- Hicks MJ, Flaitz CM. 2000. Oral mucosal melanoma: epidemiology and pathobiology. *Oral Oncology*, Mar 31;36(2):152-69.
- Hodi FS, O'day SJ, McDermott DF, Weber RW, Sosman JA, Haanen JB, Gonzalez R, Robert C, Schadendorf D, Hassel JC, Akerley W. 2010. Improved survival with ipilimumab in patients with metastatic melanoma. *N Engl J Med.*, Aug 19, (363):711-23.
- Kaul S, Kumar P. 2013. Significance of early detection of oral malignant melanoma in improving prognosis. *South Asian Journal of Cancer*, 2(4):199.
- Meleti M, Leemans CR, Mooi WJ, Vescovi P, van der Waal I. 2007. Oral malignant melanoma: a review of the literature. *Oral oncology*, 28;43(2):116-21.
- Notani K, Shindoh M, Yamazaki Y, Nakamura H, Watanabe M, Kogoh T, Ferguson MM, Fukuda H. 2002. Amelanotic malignant melanomas of the oral mucosa. *British Journal of Oral and Maxillofacial Surgery*, 30;40(3):195-200.
- Ohashi K, Kasuga T, Tanaka N, Enomoto S, Horiuchi J, Okada N. 1992. Malignant melanomas of the oral cavity: heterogeneity of pathological and clinical features. *Virchows Archiv*, 1;420(1):43-50.
- Östman J, Anneroth G, Gustafsson H, Tavelin B. 1995. Malignant oral tumours in Sweden 1960–1989—an epidemiological study. *European Journal of Cancer Part B: Oral Oncology*, 1;31(2):106-12.
- Pour MH. 2008. Malignant melanoma of the oral cavity: a review of literature. *Indian Journal of Dental Research*, 1;19(1):47.
- Prasad ML, Patel SG, Huvos AG, Shah JP, Busam KJ. 2004. Primary mucosal melanoma of the head and neck. *Cancer*, 15;100(8):1657-64.
- Rapini RP, Golitz LE, Greer RO, Krekorian EA, Poulson T. 1985. Primary malignant melanoma of the oral cavity. A review of 177 cases. *Cancer*, 1;55(7):1543-51.
- Snow GB, Van der Waal I. 1986. Mucosal melanomas of the head and neck. *Otolaryngologic clinics of North America*, 19(3):537-47.
- Takagi M, Ishikawa G, Mori W. 1974. Primary malignant melanoma of the oral cavity in Japan. With special reference to mucosal melanosis. *Cancer*, Aug 1;34(2):358-70.

- Tanaka N, Amagasa T, Iwaki H, Shioda S, Takeda M, Ohashi K, Reck SF. 1994. Oral malignant melanoma in Japan. Oral surgery, *Oral medicine, oral pathology*, 1;78(1):81-90.
- Tanaka N, Mimura M, Ichinose S, Odajima T. 2001. Malignant melanoma in the oral region: ultrastructural and immunohistochemical studies. *Medical Electron Microscopy*, 1;34(3):198-205.
- Umeda M, Komatsubara H, Shibuya Y, Yokoo S, Komori T. 2002. Premalignant melanocytic dysplasia and malignant melanoma of the oral mucosa. *Oral oncology*, Oct 31; 38(7):714-22.
- Umeda M, Shimada K. 1994. Primary malignant melanoma of the oral cavity—its histological classification and treatment. *British Journal of Oral and Maxillofacial Surgery*, 1;32(1):39-47.
