



ISSN: 0975-833X

Available online at <http://www.journalcra.com>

International Journal of Current Research
Vol. 9, Issue, 10, pp.59279-59284, October, 2017

INTERNATIONAL JOURNAL
OF CURRENT RESEARCH

RESEARCH ARTICLE

EVALUATION OF THE CHANGES IN THE UPPER CENTRAL INCISORS AFTER RAPID MAXILLARY EXPANSION

¹Roberta Lopes Gomes Cesário, ²FauzeRamez Badreddine, ³Eduardo Guimarães Moreira Mangolin, ³Marcio da Rocha Carvalho, ⁴Lucia Hatsue Yamamoto Nagai, ⁵Mario Cappellette Jr

¹MDS, Faculdade São Leopoldo Mandic, ORCID: 0000-0001-7437-4759

²MDS, Universidade Federal de São Paulo, São Paulo, Brazil

³MDS, Faculdade São Leopoldo Mandic

⁴Dr Orthodontist, Universidade Federal de São Paulo, São Paulo, Brazil

⁵D.D.S., Ph.D., Universidade Federal de São Paulo, São Paulo, Brazil

ARTICLE INFO

Article History:

Received 10th July, 2017

Received in revised form

04th August, 2017

Accepted 14th September, 2017

Published online 31st October, 2017

Key words:

Maxillary Deficiency;
Maxillary Expansion;
Computed Tomography.

ABSTRACT

Objective: Short-term evaluation of the changes in the position of permanent upper central incisors after rapid maxillary expansion.

Method: This research study comprised 33 mouth-breather patients with maxillary atresia, 9.51-year-old average age, 2.32 standard deviation and age ranging from 6.5 to 14.7 years of age. Patients underwent computed tomography in two stages: (T1) before rapid maxillary expansion and (T2) three months after rapid maxillary expansion. Five linear variables (I-NA, I-N, I-Cli, I-ENP, (ENA-N)-I) and five angular variables (SN.I, N-S.Cli-I, SN.(axis)I, N.ENA.ENP, Rhi-I.ENA-ENP) were analyzed, all of them coming out from the incisal edge of the buccal inclined upper central incisor. With the data collected through the OsirixMD imaging program, the evaluations of individual changes, before and after rapid maxillary expansion procedures, were performed accordingly.

Results: Significant increase was found in the I-N (+0.96mm, +1.3%, p=0.003) and in the I-Clinoid (+1.26mm, +1.3%, p<0.001) linear variables and a decrease was found in the SN.I (-1.61mm, -1.5%, p=0.034) angular variable. The remaining variables have not shown significant variables between stages T1 and T2.

Conclusion: It can be concluded that there is significant protrusion and lingual inclination of the permanent upper central incisor teeth after rapid maxillary expansion in a short-term evaluation analysis.

Copyright©2017, Roberta Lopes Gomes Cesário et al. This is an open access article distributed under the Creative Commons Attribution License, which permits unrestricted use, distribution, and reproduction in any medium, provided the original work is properly cited.

Citation: Roberta Lopes Gomes Cesário, FauzeRamez Badreddine, Eduardo Guimarães Moreira Mangolin, Marcio da Rocha Carvalho, Lucia Hatsue Yamamoto Nagai, Mario Cappellette Jr. 2017. "Evaluation of the changes in the upper central incisors after rapid maxillary expansion", *International Journal of Current Research*, 9, (10), 59279-59284.

INTRODUCTION

Maxillary atresia is a very common early established malocclusion that does not present self-correction (Angell, 1860; Angell et al., 1860 and Wertz, 1970) which justifies the indication of rapid maxillary expansion (RME) by several orthodontists (Haas, 1959; Haas, 1961; Haas, 1970 and Lagravere, 2005). There are several dental-skeletal effects caused by RME, in which the main ones are the increase of the transverse dimension of the maxilla and buccal inclination of the upper dentoalveolar region (Haas, 1959; Haas, 1961; Cappellette Jr., 2008; Kartalian, 2010), the opening of the midpalatal suture (Garrett, 2008; Ballanti, 2010); alterations

*Corresponding author: Roberta Lopes Gomes Cesário, MDS. Associação Brasileira de Odontologia, ORCID: 0000-0001-7437-4759

in the nose size (Cappellette, 2008), and clockwise rotation of the maxilla with a consequent increase of the facial height (Kartalian, 2010). However, one of the main changes occur in the position of the permanent upper incisors in relation to the bone bases and surrounding soft tissues. These changes should be taken in consideration during the diagnosis, planning and treatment progress, aiming at achieving facial balance and harmony with long-term stable results (Ballanti, 2010; Silva, 2010; Canuto, 2010; Habeeb, 2013; Cabrera, 2004). The method of analysis most commonly used to evaluate the transversal effects caused by rapid maxillary expansion was the posteroanterior cephalometric radiographs (PA) and, to evaluate the upper central incisors, lateral cephalograms were used for such purpose bidimensional images were used to evaluate the tridimensional structures (Wertz, 1970; Lagravere, 2005; Chung, 2004), making it difficult, in some opportunities,

to identify and properly locate the craniofacial structures (Ballanti, 2010). Currently, computed tomographies (CT scans) have become a more accurate tool to obtain a correct diagnosis, being considered a reliable method providing high precision information and data accuracy, producing real size anatomical images 1:17,10,17. This research study aimed at evaluating the changes in the position of permanent upper central incisors after rapid maxillary expansion by computed tomography in mouth-breather patients with maxillary atresia.

MATERIALS AND METHODS

A retrospective study was conducted and approved by the Research Ethics Committee under number 1.076.724, with the sample comprised 33 patients (18 male subjects and 15 female subjects), 9.51-year-old average age, 2.32 standard deviation and age ranging from 6.5 to 14.7 years of age. Patients were mouth breathers, showing maxillary atresia, with clinical evaluation of the RME. All of them were clinically evaluated by an otolaryngologist (mouth breathing evaluation) and by an orthodontist (maxillary atresia evaluation).

in relation to the Frankfurt plane, and, vertically in relation to the median sagittal plane (Cevidanes, 2009; Hassan, 2013) correcting any deviations of the head position that could interfere in the measurements of interest. The craniometric points used in this research study (Hassan, 2013; Rhine, 1981; Mutinelli, 2008; Tedeshi-Oliveira, 2009 and Cavanagh, 2011), already consecrated and widely used in world literature are described in Table 1 and were marked based on the buccal inclined permanent upper central incisor. The evaluated linear variables are described in Table 2 (Figure 2) and the angular variables in Table 3 (Figure 3).

Statistical Analysis

The statistical analysis was performed using the *Statistical Packag for the Social Sciences* (SPSS) program, version 22 for Windows. A 5% significance level was considered for the statistical tests. Linear (mm) and angular (degrees) measurements are characterized by the minimum (Min), maximum (Max), mean (M) and standard deviation (SD). For the analysis of the method of error, all variables were

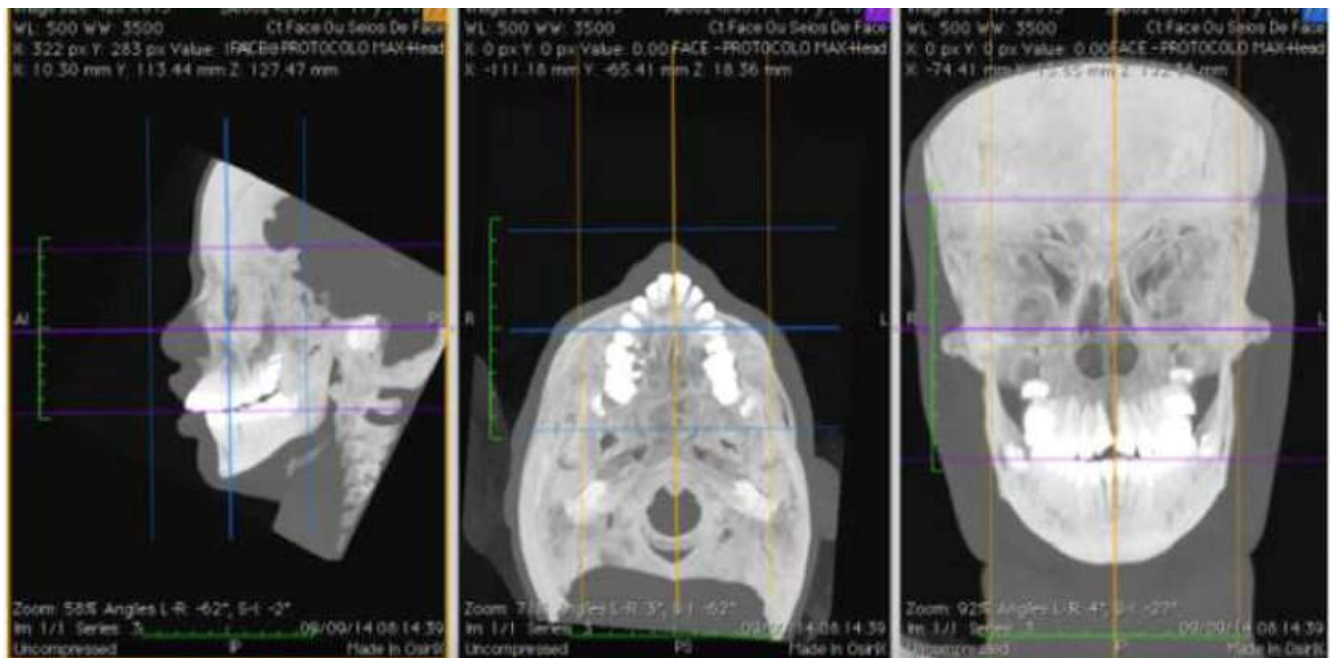


Figure 1. 3D reconstruction window of multiplanar sections (sagittal, axial and coronal) with the head properly repositioned in relation to the Frankfurt plane and the median sagittal plane

During CT scan procedures, the device was properly adjusted according to the skull size, with the KVp dose and the mAs respecting the ALARA principle. CT scans were taken in two stages: (T1) before RME and (T2) three months after RME. The activation protocol of the expansion appliances (Hyrax – Morelli® Brand) was 6/4 initial activation, with 2/4 activations daily, until achieving the necessary amount of expansion observed clinically by the position of the upper buccal bone plate in relation to the lower portion of the Wala board, allowing the control of the upper arch overcorrection when compared to the lower arch. Comparisons between T1 and T2 were carried out with the aid of the *OsiriX MD image manipulation program* (FDA approved, version 1.4.2; Pixmeo, Geneva, Switzerland). With the tools provided by the program, images of multiplanar windows were generated (sagittal, axial and coronal) and used for the desired measurements (Figure 1). In order to standardize the head between T1 and T2, the CT images were aligned horizontally

measured twice by two observers, at 30-day intervals between the first and the second measurement. The Student's T Test was applied for paired samples as well as the Intraclass Correlation Coefficient (ICC). The test results have shown no significant differences ($p > 0.05$) when comparing the initial measurements to the repetitions, neither on the repetitions made by the same evaluator (intraevaluator), nor on the ones made by the second evaluator (inter-evaluator). ICC values were all above 0.90, indicating excellent consistency when comparing the intra-evaluator measurements to the inter-evaluator measurements. Therefore, the Student's T Test and the ICC results indicate excellent consistency and reliability of the measurements, ensuring that there is no error neither on the intra-evaluator measurements, nor on the inter-evaluator measurements. In order to verify the sample size, the Student's T test was applied for paired samples, allowing to identify the differences of small/median dimension ($d = 0.44$) no GE ($n = 33$) as significant ones, with 80% test power and 5%

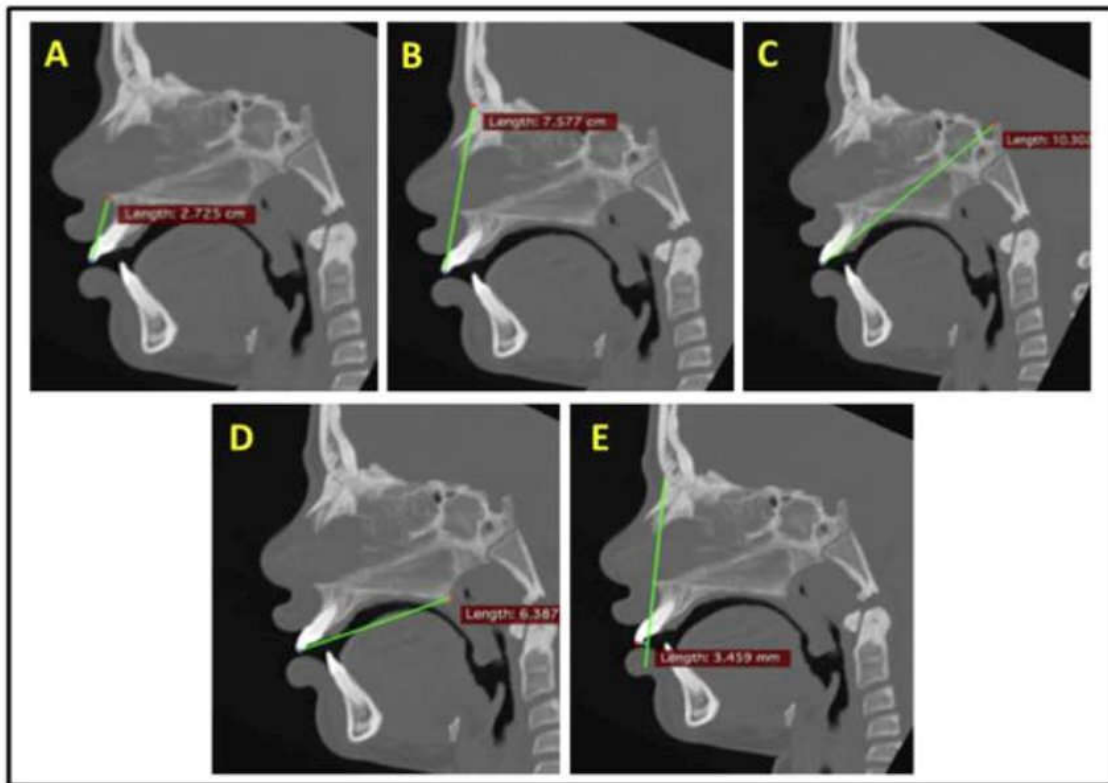


Figure 2. Linear Variables – (A) 1-ENA; (B) 1-N; (C) 1-Cli;(D) 1-ENP; (E) (ENA-N)-1

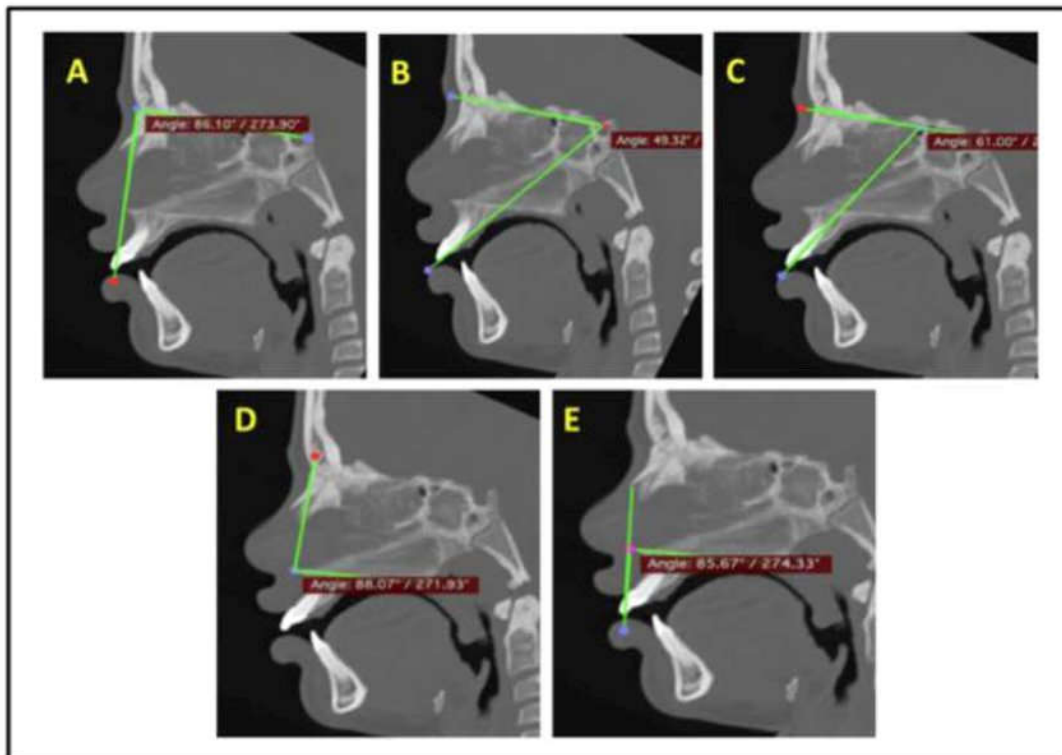


Figure 3. Angular variables – (A) SN.1; (B) N-S.Cli-1; (C) SN. (EIXO)1(D)N.ENA.ENP;(E)Rhi-1.ENA-ENP

significance level, confirming that this sample is enough to validate the results obtained by this research study. The results of the Shapiro-Wilk test have shown that for the studied variables the significance levels were higher than 0.05 ($p > 0.05$) in all measurements (1st measurement, intra-evaluator repetition and inter-evaluator repetition), both before RME and after RME, indicating that the data studied presents a normal distribution.

RESULTS

Pre and post-RME measurement results are described in Table 4. As for the linear variables, 1-ENA mean values have increased from 26.89 to 27.32 (+1.6%), however, such differences have not shown to be significant ones ($p = 0.095$). Significant changes have been seen in 1-N ($p = 0.003$, +0.96mm, +1.3%) and in the 1-Clinoid ($p < 0.001$, +1.25mm

+1.3%). As for the 1-ENP ($p = 0.624$) and the (ENA-N)-1 ($p = 0.369$), there were not statistically significant differences between the pre and post-RME measurements. Considering the (ENA-N)-1, there was a 14.7% change in the mean values between the pre and post-RME procedures.

DISCUSSION

When conducting this research study, a major concern was to ensure that the sample used was reliable and adequate, so as not to camouflage or change the interpretation of results.

Table 1. Cephalometric points based on the most buccally inclined upper central incisor

POINT	DEFINITION
1	Incisal edge of the permanent upper central incisor
ENA	Anterior nasal spine
ENP	Posterior nasal spine
N	Nasion
Cli	Posterior clinoid process
Axis 1	Long axis of the permanent upper central incisor
Rhi	Rhinio

Table 2. Linear variable

Figure	Variable	Definition
2A	1-ENA	In the sagittal window, it is located the ENA points and the incisal edge of the upper central incisor (1). The linear distance between the points corresponds to the 1-ENA value.
2B	1-N	In the sagittal window, it is located the incisal edge of the upper central incisor (1) and the Nasion point. The linear distance between the points corresponds to the 1-N value.
2C	1-Clinóide	In the sagittal window, it is located the points of the incisal edge of the upper central incisors (1) and the sella turcica most posterior, which is called Posterior Clinoid Process. The linear distance between the points corresponds to the 1-Cli value.
2D	1-ENP	In the sagittal window, it is located the incisal edge points of the upper central incisor (1) and the most posterior point of maxilla nasal spine, which is called Posterior Nasal Spine. The linear distance between the points corresponds to the linear distance between the points corresponds to the 1-ENP value.
2E	(ENA-N)-1	Firstly, a line is drawn connecting the Anterior Nasal Spine (ENA) and the Nasion Point (N). Then, the distance between the incisal edge of the upper central incisor (1) to the extension of such line is linearly measured.

Table 3. Angular Variable

Figure	Variable	Definition
3a	SN.1	Angle formed between the incisal edge of the Upper Central Incisor (1), the Nasion point (N) and the Sella (S)
3b	N-S.Cli-1	Angle formed by the lines passing through the N point (Nasion), the S (Sella turcica) and the incisal edge of the upper central incisor (1) and the Posterior Clinoid Process (Cli)
3c	SN.(axis)1	Angle formed by the lines passing through the N point (Nasion), S point (Sella turcica) and upper central incisor long axis (axis 1)
3d	N.ENA.ENP	Angle formed by points Posterior Nasal Spine (ENP), Anterior Nasal Spine (ENA) and Nasion (N)
3e	Rhi-1.ENA-ENP	Angle formed by lines passing through the ENA (Anterior Nasal Spine), ENP (Posterior Nasal Spine), incisal edge of the upper central incisor (1) and Rhinio point (Rhi)

Table 4. Characterization and comparison of pre-and post-RME (n=33)

Variables	Pre-rme				Post-rme				Diference		$P^{(1)}$
	Min	Max	M	Dp	Min	Max	M	Dp	M	%	
Linear											
1-ena	21.68	35.49	26.89	3.01	20.26	36.53	27.32	3.22	0.43	1.60%	0.095
1-n	60.29	86.44	72.72	5.82	60.14	87.22	73.68	5.9	0.96	1.30%	0.003
1-cli	78.28	109.61	94.79	6.88	79.61	110.01	96.04	6.65	1.25	1.30%	< 0.001
1-pne	42.73	63.87	52.31	5.2	39.02	63.91	52.13	5.3	-0.18	-0.40%	0.624
(ane-n)-1	-8.25	5.2	-3.7	3.12	-8.17	6.27	-3.16	4.17	0.54	14.70%	0.369
Angular											
S.n.1	66.73	94.41	84.91	5.34	65.87	92.53	85.18	5.66	0.27	0.30%	0.423
N-s.cli-1	45.89	59.09	52.37	3.48	47.14	60.67	52.89	3.69	0.52	1.00%	0.14
Sn.(eixo)1	93.6	119.29	106.7	6.79	90.12	118.33	105	7.2	-1.61	-1.50%	0.034
N.ane.pne	81.19	93.23	86.63	3.03	80.84	93.75	86.42	3.14	-0.21	-0.20%	0.478
Rhi-1.ane-pne	71.77	91.9	82.37	4.52	74.14	94.65	82.12	4.6	-0.26	-0.30%	0.539

⁽¹⁾ p – Significant values of the t Student test for paired samples

Regarding the angular variables, significant differences were only seen when comparing the pre and post-RME procedures in the SN variable (axis)1 ($p = 0.034$). For such variable, the mean value has decreased from 106.65 to 105.03 (-1.61mm, -1.5%). In the S.N.1 ($p = 0.423$), N-S.CLI-1 ($p = 0.140$), N.ENA.ENP ($p = 0.478$) and Rhi-1.ENA-ENP ($p = 0.539$), the pre and post-RME differences were not significant.

By applying the inclusion and exclusion criteria, it was possible to obtain a sample of 33 subjects, which was larger than any of the samples analyzed by Bazargani et al. 24. The analysis of the sample calculation for the sample size showed 80% power at 5% significance level, showing that this sample was adequate to validate this study. Another concern was with the reproducibility of the method, attempting to conduct a simple and reproducible methodology. The method of error analysis to

check the intra and inter-observer reliability has shown that the results have indicated excellent reliability and consistency for both the intra and inter-observer measurements, ensuring that there is no error, with $p > 0.05$ and ICC above 0.90. In conducting the data normality tests, it was noted that all measures evaluated present normal distribution ($p > 0.05$). All intra and interobserver evaluations were performed using the same program (*Osirix*– Dias *et al.*, 2013) and with computers from the same brand, specification and with the same screen configuration to avoid differences in images as advised by Baratieri, *et al.* 25 With the great variety of displays available in the market, a suggestion is to have new studies on screen standardization, because in an analysis of image quality and sharpness, this would be very important to avoid possible bias in the works. The selected cephalometric points were taken from relevant scientific articles (Lagravere, 2005; Habeeb, 2013; Hassan, 2013; Rhine, 1980; Mutinelli, 2008 and Tedeshi-Oliveira, 2009). In order to properly mark the selected points on the CT scans to avoid errors or distortions during the interpretation of results, the head was repositioned in all CT scans before marking the cephalometric points. According to Cevidanes *et al.* and Hassan *et al.* the standardization of the head position before the analysis is very important to confirm the accuracy and reliability of results, as small changes in the head positioning can cause distortions. Once we were sure that we had an adequate sample and a reliable methodology, then, we decided to conduct a research study that would evaluate the changes in the inclination of permanent central incisors after RME, by CT scans, in mouth-breather patients with maxillary atresia. This research study was motivated by the lack of data in the literature on the subject in terms of values accuracy. Therefore, a great approach was needed on the measurements of the topics in question.

The indication of undergoing a patient to CT scan examinations should be made with great care, only when the benefits of the diagnosis and treatment outweigh the risks of a higher dose of radiation 27. All patients who have participated in this research study have undergone CT scan examination by medical indication, respecting the ALARA principle. Therefore, no human being was exposed to ionizing radiation for the sole purpose of the study. In this research study, the evaluation of the linear dental changes showed that there was a protrusion of the permanent upper central incisors by the increase in the I-N = +0.96mm measurement (+1.3%), comparing T1 to T2, and in the I-Cli measurement, that has increased by +1.25mm (+1.3%). Both 8 results have shown to be significant with $p = 0.003$ and < 0.001 respectively. Considering the angular analysis, the SN. (axis 1) measurement has decreased by 1.62° (-1.5%) with $p = 0.034$, showing a simultaneous lingual inclination of the incisor teeth. Similar results were observed by several authors (Haas, 1959; Haas, 1961; Silva, 2010; Habeeb, 2013; Gurel, 2010; Miner, 2012) and Silva Filho *et al.* (2010), relating the behavior of the central incisors with RME. This was reported in a study conducted with 20 children, observing the spacing of the crowns with the greatest separation in the anterior region, in which the buccal inclination of the incisors has not shown clinical significance. Gurel *et al.* (2010), reported that the RME significantly decreases the overbite, increasing the overjet, showing statistically significant decrease of both the overjet and the overbite during the post-retention evaluation. However, Kartalian *et al.* (2010), reported an increase in all dimensions but showed no significant amount of dental inclination post-

RME. Regarding the alveolar inclination, it was observed some significance when comparing the studied group to the control group. The fact that justifies the simultaneous protrusion and lingual inclination of the incisor teeth is that the RME promotes a shift of the maxilla forwards and down wards (Wertz, 1970; Cappellette, 2008; Habeeb, 2013; Moss, 1968; Moss, 1968; Beaini, 2013 and Leri, 2015) and, consequently, the upper lip exerts pressure over the incisors causing lingual inclination (Haas, 1959; Haas; Haas, 1961; Silva Filho, 2010; Habeeb, 2013). Miner *et al.* (Miner, 2012) have investigated the relationship in the transverse dimension in 241 patients, carrying out dental and skeletal evaluation and, in one of their conclusions, have admitted that there are dental compensations both in the maxilla and in the mandible. Short-term results lead us to believe that the changes in the position of the permanent upper central incisors are minor, occurring solely by the RME procedure that moves the maxilla forward and downward, with greater participation of the labial muscles over these teeth. These data corroborate to the findings of further authors regarding the effect of the maxillary expansion (Kartalian, 2010; Cabrera, 2013; Baratieri, 2010; Miner, 2012; Phatouros, 2008 and Toklu, 2015). Long-term studies should be conducted to verify the stability of the incisor teeth over the time, remembering that these changes should be taken into consideration during the diagnosis, planning and treatment progress stages, aiming at achieving the maximum balance and facial harmony with the maximum possible stability.

Conclusion

According to the results achieved in this research study, the comparisons between the pre and post-RME for the studied variables allow us to conclude that there was a slight protrusion and lingual inclination of the permanent upper central incisor after RME.

REFERENCES

- Angell, E.H. 1860. Treatment of irregularity of the permanent or adult teeth. Part I. *Dental Cosmos.*, 1:540-544.
- Angell, E.H. 1860. Treatment of irregularity of the permanent or adult teeth. Part II. *Dental Cosmos.*, 1: 599-601.
- Ballanti, F., Lione, R., Baccett, T., Franchi, L. and Cozza, P. 2010. Treatment and posttreatment skeletal effects of rapid maxillary expansion investigated with low-dose computed tomography in growing subjects. *AMJ Orthod Dent Orthop Sept.*, 138(3):311-7.
- Baratieri C, Nojima LI, Alves Jr M, Souza MMG, Nojima MG. Transverse effects of rapid maxillary expansion in Class II malocclusion patients: A Cone-Beam Tomography study. *Dental Press J Orthod.* 2010. Sept-Oct, 15(5):89-97.
- Bazargani F, Feldmann I, Bondemark L. Three-dimensional analysis of effects of rapid maxillary expansion on facial sutures and bones. A systematic review. *Angle Orthod.* 2013; 83(6):1074-1082
- Beaini TL. Espessura de tecidos moles nos diferentes tipos faciais: Estudo em tomografias computadorizadas cone-beam [tese]. São Paulo: Universidade de São Paulo; 2013.
- Cabrera LC, Retamoso, LB, Mei RMS, Tanaka O. *Dental Press J Orthod.* 2013 Mar-Apr; 18(2):30-5.
- Canuto, L.F.G., Freitas, M.R., Janson, G., Freitas, K.M.S., 2010. Martins PP. Influence of rapid palatal expansion on maxillary incisor alignment stability. *Am J Orthod Dentofacial Orthop.* 137:164.e1-164.e6.

- Cappellette, Jr. M, Cruz, O.L., Carlini, D., Weckx, L.L., Pignatari, S.S. 2008. Evaluation of nasal capacity before and after rapid maxillary expansion. *Am J Rhinol.* Jan-Feb; 22(1):74-7.
- Cavanagh D, Steyn M. 2011. Facial reconstruction: Soft tissue thickness values for South African black females. *Forensic Science International.* 206:215.e1-215.e7.
- Cevindanes L, Oliveira AEF, Motta, Phillips C, Burke B, Tyndall D. 2009. Head orientation in CBCT-generated cephalograms. *Angle Orthodontist.*, 79(5):971-77.
- Chung CH, Font B. 2004. Skeletal and dental changes in the sagittal, vertical, and transverse dimensions after rapid palatal expansion. *Am J Orthod Dentofacial Orthop.* 126:569-75.
- Garib, D.G., Calil, L.R., Leal, C.R., Guilherme Janson, G. 2014. Is there a consensus for CBCT use in Orthodontics? *Dental Press J Orthod.*, Sept-Oct;19(5):136-49
- Garrett, B.J., Caruso, J.M., Rungcharassaeng, K., Farrage, J.R., Kim, J.S., Taylor, G.D. 2008. Skeletal effects to the maxilla after rapid maxillary expansion assessed with cone-beam computed tomography. *Am J Orthod Dentofac Orthoped.* Jul.; 134(1):8e1-8e11.
- Gurel, Hg; Badel, M; Erkan, M; Sukurica, Y. Long-Term Effects of Rapid Maxillary Expansion Followed by Fixed Appliances. *Angle Orthod.* 2010. 80(1):5-9.
- Haas, A. J. 1959. Gross reactions to the widening of the maxillary dental arch of the pig by splitting the hard palate. *Am J Orthodontics.* 45(11):868-69.
- Haas, A. J. 1961. Rapid expansion of the maxillary dental arch and nasal cavity by opening the midpalatal suture. *Angle Orthod.*, 31(2):73-90.
- Haas, A.J. 1970. Palatal expansion: Just the beginning of dentofacial orthopedics. *Am J Orthod.* March; 57(3):219-255.
- Habeeb M, Boucher N and Chung C. 2013. Effects of rapid palatal expansion on the sagittal and vertical dimensions of the maxilla: A study on cephalograms derived from cone-beam computed tomography. *Am J Orthod Dentofacial Orthop.* 144(3):398-403.
- Hassan B, Nijkamp P, Verheij J, Taire J, Vink C, Van Der Stelt P, et al. 2013. Precision identifying cephalometric landmarks with cone beam computed tomography in vivo. *Eur J Orthod.* Feb.;35(1):38-44.
- Kartalian, A., Gohl, E., Adamian, M., Reyes, E. 2010. Cone-beam computerized tomography evaluation of the maxillary dentoskeletal complex after rapid palatal expansion. *Am J Orthod Dentofac Orthop.* Oct; 138(4):486-492.
- Lagravere, M.O., Major, P.W., Flores-Mir, C. 2005. Long-term skeletal changes with Rapid Maxillary Expansion: A Systematic Review. *Angle Orthod.*, 75:1046-1052.
- LLeri Z, Basciftci FA. 2015. Asymmetric rapid maxillary expansion in true unilateral crossbite malocclusion: A prospective controlled clinical study. *Angle Orthod.*, 85:245-253.
- Mah JK, Huang JC, Choo H. 2010. Practical applications of cone-beam computed tomography in orthodontics. *Journal of the American Dental Association.* 141(3):7S-13S.
- Miner, R. M., Qabandi, S. A., Rigali, P. H., and Will, L. A. 2012. Cone-beam computed tomography transverse analysis. Part I: Normative data. *Am J Orthod Dentofacial Orthop.*, 142(3):300-7.
- Moss JP. 1968. Rapid expansion of the maxillary arch. Part I. *J Pract Orthod.* 2(5):165-71.
- Moss JP. 1968. Rapid expansion of the maxillary arch. Part II. *J Pract Orthod.* 2. (5):215-223.
- Mutinelli S, Cozzani M, Manfredi M, Bee M, Siciliani G. Dental arch changes following rapid maxillary expansion. *European Journal of Orthodontics.* 2008; 30:469-476.
- Phatouros A; 2008. Goonewardene MS. Morphologic changes of palate after rapid maxillary expansion: A 3-dimensional computed tomography evaluation. *Am J Orthod Dentofac Orthop.* Jul.; 134(1):117-124.
- Rhine JS, Campbell HR. 1980. *Journal of Forensic Sciences,* JFSCA, Oct;25(4):847-858.
- Silva Filho, O.G., Silva, V.B., Lauris, R.C.M.C. 2010. Comportamento dos incisivos centrais permanentes superiores frente à expansão rápida da maxila – estudo com tomografia computadorizada. *Rev Ortodontia SPO.*, 43(4):377.
- Tedeshi-Oliveira SV, Melani RFH, Almeida NH, Paiva LAS. 2009. *Forensic Science International.* 193:127.e1-127.e7.
- Toklu MG, Germec-Cakan D, Tozlu M. Periodontal, dentoalveolar, and skeletal effects of tooth-borne and tooth-bone-borne expansion appliances. *Am J Orthod Dentofacial Orthop.* 2015;148(1):97-109.
- Wertz, R.A. 1970. Skeletal and dental changes accompanying rapid midpalatal suture opening. *Am J Orthod.* July 58(1): 41-63.
