



RESEARCH ARTICLE

EVALUATION OF INCIDENCE OF CYSTOID MACULAR OEDEMA (CME) USING SPECTRAL DOMAIN OPTICAL COHERENCE TOMOGRAPHY (SD-OCT) AFTER UNEVENTFUL PHACOEMULSIFICATION

Piyush Tewari, \*Raji Kurumkattil, Anil Kumar Upadhyay and Shrikant Waikar

Department of Ophthalmology, Army Hospital (R&R) Delhi Cantt., Pin 110010

ARTICLE INFO

Article History:

Received 23<sup>rd</sup> July, 2017  
Received in revised form  
26<sup>th</sup> August, 2017  
Accepted 18<sup>th</sup> September, 2017  
Published online 31<sup>st</sup> October, 2017

Key words:

Cystoid macular oedema,  
Cataract,  
Phacoemulsification,  
Optical coherence tomography.

ABSTRACT

**Purpose:** To evaluate the occurrence of cystoid macular oedema (CME) and to identify changes in the thickness in the central macula (CMT) using spectral domain optical coherence tomography (SD-OCT) after uneventful phacoemulsification surgery.

**Method:** In this prospective study, 150 patients of cataract, were subjected to examination by SD-OCT one day before and 1, 4, and 12 week post operatively to detect any changes in foveal thickness and presence of cystoid macular oedema. The results were analyzed and correlated with the visual acuity.

**Results:** 150 patients were included in this study. Out of these 150 patients, 86(57.33%) were males and 64(42.67%) were females, with mean age being 65.33±6.82 years. None of them had any pre-existing ocular pathology. The average central macular thickness (CMT) measured preoperatively was 243.35± 19.508. Out of 150 patients, 5 (3.33%) patients were detected to have post operative CME. Decline in visual acuity was noticed in those patients who developed post operative macular oedema, and improvement was noted by the end of 12 weeks. Mild increase in macular thickness (±35µ) was noticed even in those eyes which did not develop macular oedema.

**Conclusion:** CME can develop even in patients who had undergone uncomplicated cataract surgery. SD OCT is a reliable and non invasive method to detect the changes in the macula at early stage and helps in accurate diagnosis.

Copyright©2017, Piyush Tewari et al. This is an open access article distributed under the Creative Commons Attribution License, which permits unrestricted use, distribution, and reproduction in any medium, provided the original work is properly cited.

Citation: Piyush Tewari, Raji Kurumkattil, Anil Kumar Upadhyay and Shrikant Waikar, 2017. "Evaluation of incidence of Cystoid Macular Oedema (CME) using Spectral Domain Optical Coherence Tomography (SD-OCT) after uneventful Phacoemulsification", *International Journal of Current Research*, 9, (10), 59934-59937.

INTRODUCTION

Phacoemulsification with intraocular lens (IOL) implantation is the commonly performed surgery for cataract in the world (Desai et al., 1999). The visual outcome after surgery depend upon factors like expertise of the surgeon, surgical method used, any pre-existing ocular pathology or occurrence of intra operative or postoperative complications. To assess the potential for good visual recovery, patients should be subjected to various clinical tests like measurement of visual acuity, intra ocular pressure, slit lamp biomicroscopy, and examination of retina. Some patients may require special tests like specular microscopy and optical coherence tomography to rule out any corneal and retinal pathology. Postoperative cystoid macular edema (CME) is a well-known entity associated with a variety of intraocular operations and the commonest cause for suboptimal vision after cataract surgery (Mentes et al., 2003). The various modalities used in everyday practice for diagnosis of macular pathologies include slit lamp biomicroscopy, fundus

fluorescein angiography (FFA) and fundus autofluorescence. Optical Coherence Tomography (OCT) offers a non-invasive imaging technique that provides high resolution cross sectional images of the macula (Mentes et al., 2003; Sahin et al., 2013). The current study was carried out to evaluate the incidence of cystoid macular oedema (CME) and to identify changes in the thickness in the central macula (CMT) using (SD- OCT after uneventful phacoemulsification surgery and correlate the findings with the visual recovery postoperatively.

MATERIALS AND METHODS

After obtaining clearance from the institutional ethical committee one hundred and fifty patients undergoing uncomplicated phacoemulsification were considered for this study. Written informed consent was taken from all patients. Patients with sufficient media clarity to permit preoperative OCT examination were eligible for inclusion in the study. Single eye from each patient (both sexes within the age group of 50-75yrs) were included. Patients on prostaglandin analogues, topical or systemic steroids or non steroidal anti-inflammatory drugs, history of uveitis, prior intraocular

\*Corresponding author: Raji Kurumkattil,  
Department of Ophthalmology, Army Hospital (R&R) Delhi Cantt., Pin 110010

injections or surgery, past or pre-existing retinal and choroidal diseases that could affect retinal thickness were excluded from the study. Diabetic retinopathy or maculopathy, retinal vein occlusion, age-related macular degeneration, radiation retinopathy and previous laser treatment and subjects with abnormal macula based on clinical examination and preoperative macular OCT scans were also excluded from this study. A comprehensive ocular examination was performed before including the patients in this study. The examination profile was as follows: visual acuity by Snellen's chart, refraction, intraocular pressure by applanation tonometry, slit lamp biomicroscopic examination, and a detailed fundus examination. Macular thickness was measured using SD-OCT (Cirrus - Carl Zeiss Meditech, Inc, Jena, Germany). All of them had sufficient media clarity (Signal strength more than 6) to permit preoperative OCT for measuring the central macular thickness. Preoperatively patients were given eye drop moxifloxacin 0.5% and pupils were dilated using tropicamide 1% and phenyl ephrine 5%. Phacoemulsification with posterior chamber foldable intra ocular lens implantation was performed by experienced surgeons. None of the patients were given topical non steroidal or steroidal eye drops preoperatively. They were followed up at 1<sup>st</sup> postoperative day, 1<sup>st</sup>, 4<sup>th</sup> and 12<sup>th</sup> week post operatively. Visual acuity and OCT was repeated during each visit. The changes in foveal thickness and morphology were studied using optical coherence tomography (OCT). Eyes with post operative mean macular thickness >300µ or an increase of >50µ from preoperative baseline value, with or without cystoid changes, sub foveal neurosensory detachment (based on OCT) were considered to have CME. The data is analyzed using statistical software (SPSS, version 19.0, SPSS Inc, Chicago, Illinois, USA).

## RESULTS

We evaluated a total of one hundred and fifty patients without any predisposing ocular or systemic illnesses, other than cataract. Out of 150 patients, 86 were males and 64 were females (Fig. 1) with a mean age of 65.33 ±6.82 years (Fig. 2). Preoperative visual acuity ranged from 3/60 to 6/9. They underwent uneventful phacoemulsification and in-the-bag intraocular lens implantation. Out of 150 patients, OCT revealed CME in 5 patients (Fig. 3 &4). CME was clinically visible on clinical examination in two patients and on FFA all 5 cases showed leakage on macula. Rest all cases (145) were normal. Three patients developed CME at the end of 1<sup>st</sup> week, whereas other two were detected to have CME at the end of 4 weeks. The mean central macular thickness changes noticed in the cases which developed CME was 246µ preoperatively and 406µ, 475µ and 386µ at 1<sup>st</sup>, 4<sup>th</sup> and 12<sup>th</sup> week respectively (Table 1 & Figure 4). Mean central macular thickness in patients without CME was 242µ preoperatively, which was almost same as those who developed postoperative CME, while it was noted to be 248µ, 250µ and 247µ at 1<sup>st</sup>, 4<sup>th</sup> and 12<sup>th</sup> weeks during postoperative follow up period. Among the five patients who developed CME, Cystoid spaces were noted in 3 patients (Figure 3 & 4), 2 had diffuse spongiform oedema. The incidence of CME in our study was 2%, 3.3% and 2.7% at 1 week, 4weeks and 12 weeks postoperatively respectively which was comparable with other studies. In those patients who developed post operative macular oedema, a decline in visual acuity was noticed, which was maximum at 04 weeks and it was corresponding to maximum CMT which was also noticed at the same time. Patients who had CME were treated with Eye Drop Nepafenac 0.1% and all of them had responded

to treatment. Visual improvement was noted by the end of 12 weeks in all 5 patients. Whereas those who did not develop CME, there was a steady improvement in the vision throughout the period of observation

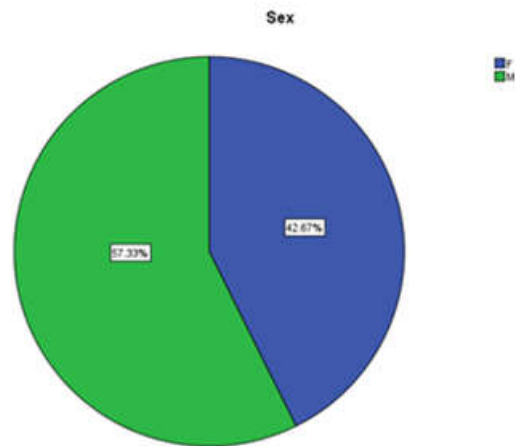


Fig. 1. Sex Distribution

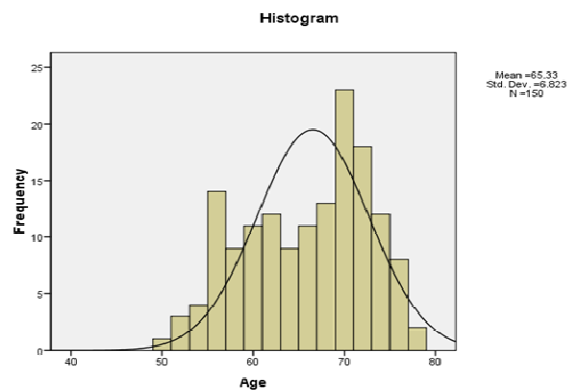


Fig. 2. Age Distribution

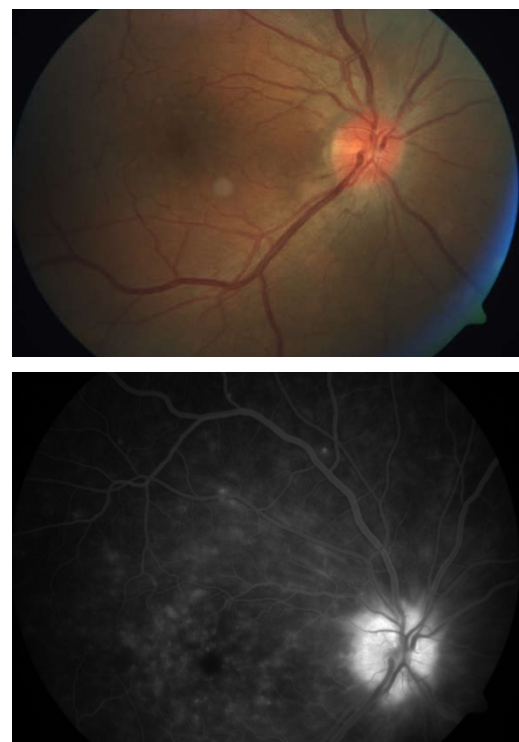

Fig.3. Fundus pictures showing cystoid macular oedema, FFA in late phase shows a flower petal pattern of hyperfluorescence on macula and disc leak

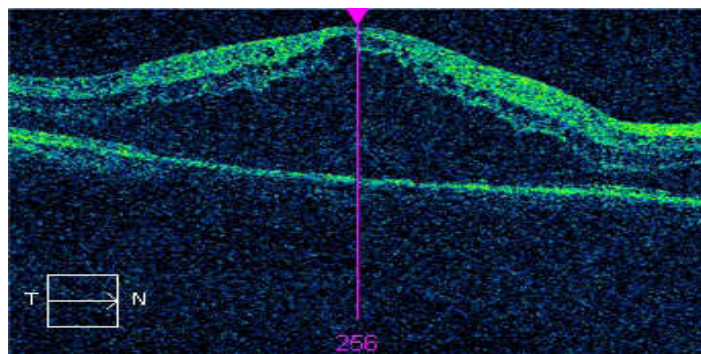


Fig 4. OCT image showing Postoperative cystoid macular oedema. Notice the collection of hyporeflective spaces within the retina, the increased macular thickness and the loss of the foveal depression

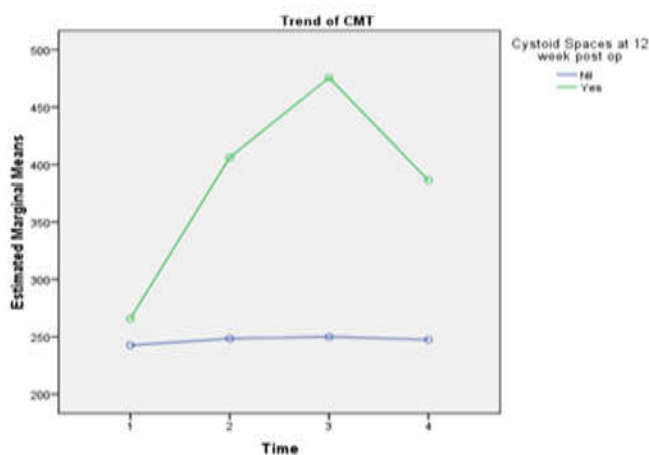


Fig. 3. Variation in CMT

Table 1. Variation central macular thickness

	CME present		CME absent		Total	
	Mean	SD	Mean	SD	Mean	SD
Pre Op	265.80	7.190	242.58	19.345	243.35	19.508
Post Op 1 week	406.20	246.181	248.42	17.729	253.68	52.329
Post Op 4 weeks	475.60	139.851	250.05	17.918	257.57	49.856
Post Op 12 weeks	386.20	58.947	247.52	17.523	252.14	31.842

Table 2. Pattern of variation in visual acuity

	CME present		CME absent		Total	
	Mean	SD	Mean	SD	Mean	SD
Pre Op	0.3820	0.11256	0.3950	0.12856	0.3945	0.12774
Post Op 1 week	0.5500	0.29908	0.8245	0.17896	0.8153	0.18920
Post Op 4 weeks	0.4840	0.34100	0.8748	0.16068	0.8618	0.18173
Post Op 12 weeks	0.6680	0.23690	0.8885	0.15663	0.8811	0.16369

Table 3. Incidence of CME observed at 1 week, 4 weeks and 12 weeks postoperatively

	No of cases with CME	Incidence
Pre-operative	Nil	Nil
1 week post operative period	3	2
4 weeks post operative period	5	3.3*
12 weeks post operative period	4	2.7

\*Peak incidence of CME observed at 4 weeks postoperatively

**DISCUSSION**

OCT examination is a reliable and non invasive procedure that helps in accurate diagnosis of macular diseases (Sahin *et al.*, 2013; Schmitz Valckenberg *et al.*, 2008; Adhi *et al.*, 2012; Massin *et al.*, 2000). OCT is a helpful tool for close monitoring of all cases and aided in picking up CME early (Trichonas and

Kaiser, 2014; Schuman *et al.*, 1995). OCT helped in measuring retinal thickness, especially CMT in all patients. The range of reported incidence rate of CME is (0.10-2.35%). CME become clinically important when it causes visual impairment. (Russo *et al.*, 2013(added)?; Ersoy *et al.*, 2013; Loewenstein and Zur, 2010) In our study preoperative examination did not reveal any macular abnormality. OCT aided in picking up CME early in

the post operative period. Mild increase in macular thickness (mean increase in thickness  $\pm 35\mu$ ) was noticed in all eyes, even in those cases which did not develop macular oedema. However, there was no difference between male or female patients. Correa *et al* observed CMT of patients who were operated for cataract and reported a steady increase in CMT till 30 days postoperatively. Fluorescein angiography is the gold standard for diagnosing CME but it is an invasive procedure with complications ranging from urticaria, vomiting and pain at injection site to anaphylactic reactions and rarely death. OCT is a quick, non-invasive and quantitative procedure with no side effects. In a comparative study by Mitne *et al.* they found 88% correlation between the two methods. (Mitne *et al.*, 2003) Ancliff *et al.* reported in their study that sensitivity and specificity of OCT was 96% and 100%. (Ancliff *et al.*, 2000; Ancliff *et al.*, 2001) To study the effects of phacoemulsification on macula Subramanian and associates conducted a prospective trial in which 81 eyes of 61 subjects were studied. Postoperatively they found that eight eyes (9.87%) demonstrated angiographic CME (Subramanian *et al.*, 2009). In their studies, they did not make any exclusion with respect to existing systemic illness such as diabetes, hypertension or coronary artery disease. If there is a high incidence of CME, it warrants investigation in uncomplicated cases. We noticed in our study that there was a moderate increase in CMT in all patients even in those patients who did not develop CME in the 1st month though it did not cause a drop in visual acuity and the mean central macular thickness reverted back to pre-operative values by 12 weeks postoperatively. Incidence of postoperative CME in our study was 3.33% (5 out of 150 cases). In cases which showed CME, an initial reduction in visual acuity was noticed with increased macular thickness. Mean macular thickness gradually reduced along with disappearance of cystic spaces over 12 weeks period. Incidence of CME was 2%, 3.3% and 2.7% during 1 week, 4weeks and 12 weeks postoperative visits respectively in our study which is comparable to the results given by Cheng *et al.* (2002) and Perenté *et al.*

## Conclusion

Post operative CME can develop even after uneventful phacoemulsification. We believe that OCT is playing a considerable clinical role in evaluation of macular thickness and analyzing the morphology, especially in post operative cases. Our results support the conclusion that OCT is more useful as compared fluorescein angiography in the diagnosis and management of the cases of CME since it is fast and non invasive method and can be repeated. OCT examination should be a part of preoperative evaluation, before any intraocular surgery.

## REFERENCES

Adhi M, Aziz S, Mohammad K, Mohammad I. 2012. Macular Thickness by age and gender in healthy eyes using SD-OCT. DOI.1371-72.

- Ancliff RJ, Spalton DJ, Stanford MR, Chauhan DS, Graham EM, Ffytche TJ, Marshall J. 2001. Intravitreal triamcinolone for uveitic cystoid macular edema: an optical coherence tomography study. *Ophthalmol.*, 108:765-772.
- Ancliff RJ, Stanford MR, Chauhan DS, Graham EM, Spalton DJ, Shilling JS, Ffytche TJ, *et al.* 2000. Comparison between optical coherence tomography and fundus Fluorescein angiography for detection of cystoid macular edema in patients with uveitis. *Ophthalmol.*, 107:593-599.
- Cheng B, LuX, Ge J, *et al.* 2002. Macular changes of optical coherence tomography after phacoemulsification. *Zhonghua Yan Ke Za Zhi.*, 38(5): 265-267.
- Desai, P., DC Minassian and A Reidy, 1999. National cataract surgery survey 1997-8: a report of the results of the clinical outcomes. *Br J of Ophthalmol.*, 83(12):1336-1340.
- Ersoy L, Caramoy A, Ristau T, Kirchhof B, Fauser S. 2013. Aqueous flare is increased in patients with clinically significant cystoid macular oedema after cataract surgery. *Br J of Ophthalmol.*, 97:862-865.
- Grzybowski A, Sikorski BL, Huerva V. 2016. Pseudophakic CME: Update. *Clinical Interv Aging.*, 11: 1221-1229.
- Loewenstein A, Zur D. 2010. Postsurgical cystoid macular edema. *Developments in Ophthalmology*, 47:148-159.
- Massin P, Vicant E, Haouchine B. *et al.* 2000. Reproducibility of retinal mapping using optical coherence tomography. *Arch Ophthalmol.*, 109(8): 1135-1142.
- Mentes J, Erakgun T, Afrashi F, Kerci G. 2003. Incidence of cystoid macular oedema after uncomplicated phacoemulsification. *Ophthalmologica.*, 217(6):408-12.
- Mitne, S. *et al.* 2003. Agreement between optical coherence tomography and fundus Fluorescein angiography in post cataract surgery cystoid macular edema. *Arq Bras Ophthalmol.*, 66(6)771-774.
- Russo A, Costagliola C, Semerao F, *et al.* 2013. Topical non steroidal anti-inflammatory drugs for macular oedema. *Mediators of Inflammation*. 2013(Oct):476525,11.
- Sahin, M., Cingu AK, Gozum N. 2013. Evaluation of cystoid macular oedema using optical coherence tomography and fundus autofluorescence after uncomplicated phacoemulsification. *J of Ophthalmol.*, 376013.
- Schmitz Valckenberg, S., F G Holz, AC Bird and RF Spaide. 2008. Fundus autofluorescence imaging: review and perspectives. *Retina*, Vol 28(3):385-409.
- Schuman, JS., MR Hee, CA Puliafito *et al.* 1995. Quantification of nerve fibre layer thickness in normal and glaucomatous eyes using optical coherence tomography: a pilot study. *Archives of Ophthalmol.*, Vol 113(5),586-596.
- Subramanian ML, Devaiah AK, Warren KA. 2009. Incidence of Postoperative Cystoid Macular Edema by a Single Surgeon. *DJO*, 4:235-6.
- Trichonas G, Kaiser PK. 2014. Optical coherence tomography imaging of macular edema. *Br J Ophthalmol.*, 98:ii24-ii29.

\*\*\*\*\*