



CASE STUDY

A RARE CASE OF DOUBLE TRICHOBEZOARS CAUSING GASTRIC AND JUJEONAL OBSTRUCTION

***Hend ALmalki, Ahmad Alasmari, Abdulrahman Albalaa and Feras AL sanna**

Department of General Surgery, Prince Sultan Medical Military City, Saudi Arabia

ARTICLE INFO

Article History:

Received 11th September, 2017
Received in revised form
16th October, 2017
Accepted 19th November, 2017
Published online 27th December, 2017

Key words:

Trichobezoar,
Bezoar.

Copyright © 2017, Hend ALmalki et al. This is an open access article distributed under the Creative Commons Attribution License, which permits unrestricted use, distribution, and reproduction in any medium, provided the original work is properly cited.

Citation: Hend ALmalki, Ahmad Alasmari, Abdulrahman Albalaa and Feras AL Sanna, 2017. "A rare case of double trichobezoars causing gastric and jujeonal obstruction", *International Journal of Current Research*, 9, (12), 62622-62624.

ABSTRACT

Bezoar is a foreign body found in the gastrointestinal tract due to ingestion of hair or vegetables. When hair is ingested and formed a mass it is called tichobezoar, this mass get complicated by gastric outlet obstruction or small bowel obstruction or presented simultaneously like in our case report. In this case report we presented our experience with a years old female who came to emergency department with signs of gastrointestinal obstruction .she was taken to operating room for exploration and relieve of mechanical obstruction. Trichobezoar with obstruction considered a surgical emergency and all general surgeons should be familiar with the diagnosis and management of this condition.

INTRODUCTION

Trichobezoars are concretions of swallowed hair in the digestive tract. The term "bezoar" is thought to be derived from the Arabic word "bazahr" or "badzehr", as stones obtained from the stomach or intestines of animals were thought to have medicinal uses (Malpani, 1988). Bezoars can be classified in four types: phytobezoar (vegetable); trichobezoar (hair); lactobezoar (milk/curd) and miscellaneous (fungus, sand, paper, etc) (Sehgal, 2006). Trichobezoars are found more in females and usually associated with trichotillomania (a compulsive desire to pull out one's hair) (Mate'ju°, 2009 and Gonuguntla, 2009). Trichobezoars were first described by Baudomant in 1779 (Malpani, 1988). The main cause of trichobezoar formation is the resistance of human hair to peristalsis and digestion (Mewa Kinoo, 2012). The syndrome is considered to be the most severe form of trichophagia, with fewer than 40 cases described in the literature. Although most cases of a Rapunzel syndrome are present in toddlers, adolescents, or young adults, recent literature indicates that the prevalence in adulthood is increasing (Tamini, 2016).

Case Report: A 21 years old lady referred to general surgery from the emergency department with 3 days history of epigastric abdominal pain witch was associated with nausea and vomiting and intolerance to oral intake.

No history of diarrhea, fever, jaundice, ingestion of contaminated food or previous similar attacks. but patient gave history of on and off abdominal pain. Her past medical review was positive for epilepsy. No previous abdominal surgeries. On physical examination generally she was looking ill, dehydrated and in pain. Her abdomen reveled positive bowel sound and it was soft lax on palpation with tenderness over epigasgtric area with voluntary guarding and no acute peritoneal signs .a palpable swelling was appreciated in the epigastric area with no defined border to measure the exact size. The rest of physical examination was unremarkable Laboratory investigation were all within normal limits, including complete blood count, serumelectrolytes, liver and renal functions, pancreatic enzymes. Abdominal computed tomography showed dilated stomach with a big intraluminal heterogeneous mass and air bubbles, duodenum and jejunum were dilated and ileum was collaped witch was suggestive of high grade bowel obstruction. Another heterogeneous mass and air bubbles was seen prior to the transition zone in the small intestine (Figs). The diagnosis of similtanousgastric and intestinal trichobezoar which was associated with high grade bowel obstruction was made. Patient was planned for urgent laparotomy and extraction of the obstructing bezoar. Due to patient history of epilepsy she was assessed by neurologist and the phenytoin dose was adjusted. Patient was taken urgently to operation room. She underwent midline laparotomy and extraction of the bezoar through gastromtomy and enerotomy in both stomach and distal jejunum and repair was made supequently in both.

***Corresponding author: Hend ALmalki**

Senior Registrar in General Surgery, Prince Sultan Medical Military City, Saudi Arabia

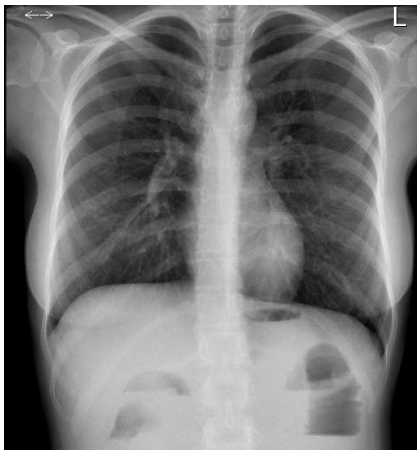
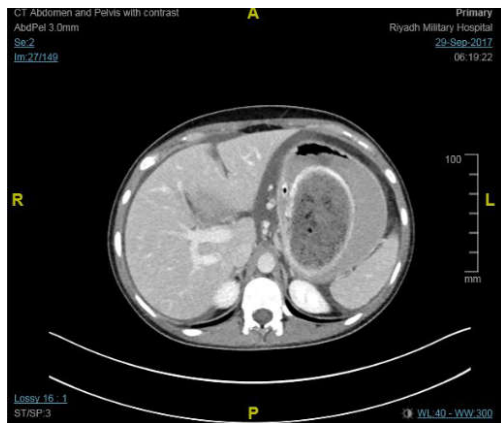
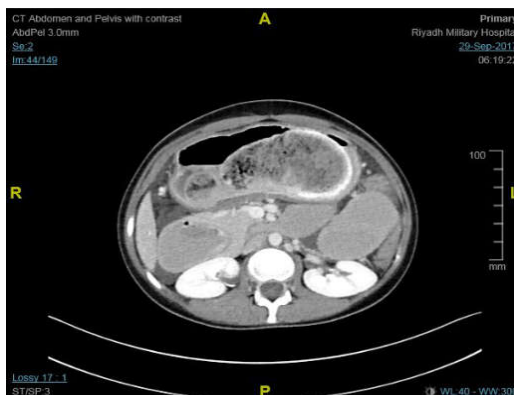

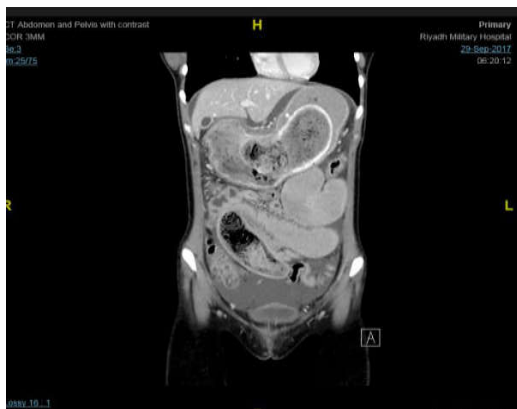Fig 1. Plane radiograph



A

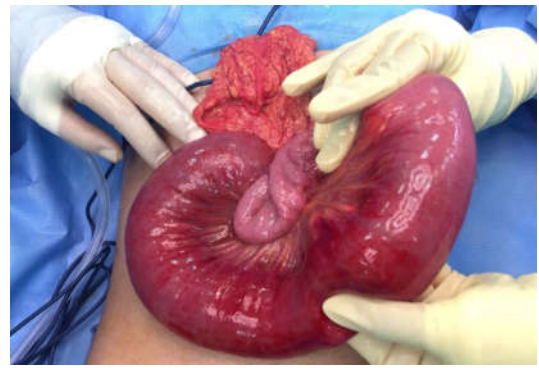


B

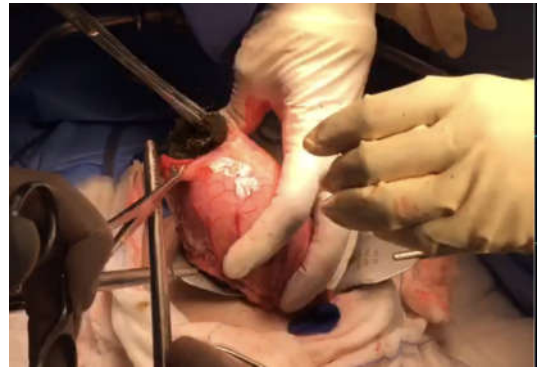


C

(A+B) axial (C) coronal CT scan view of stomach and small intestine containing bezoar



(D) Small intestine bezoar mass



(E) Extracting bezoar from the stomach



(F) Hair mass retrieved from stomach and small intestine

The stomach bezoar was hard to extract, it was divided using scissors and delivered by forceps. The rest of the bowel was run. No obvious pathology was found (Fig). During hospital course patient remained clinically stable and she was assessed by a psychiatrist and a future plan was made. Patient was discharged home and given a follow-up appointment.

DISCUSSION

Trichobezoar, a hair ball in the proximal gastrointestinal tract, is a rare condition almost exclusively seen in young females (Gorter, 2010; Diefenbach, 2000; Carr, 2006; Bouwer, 1998; Sehgal, 2006 and DeBakey, 1939). DeBakey and Ochsner reported that about 80% of individuals in whom trichobezoars developed were younger than 30 years, and 90% were female. (Frey, 2005 and Shigeyoshi, 2015). Human hair is resistant to digestion as well as peristalsis due to its smooth surface. Therefore it accumulates between the mucosal folds of the stomach. Over a period of time, continuous ingestion of hair leads to the impaction of hair together with mucus and food, causing the formation of a trichobezoar.

In most cases the trichobezoar is confined within the stomach (Gorter, 2010). Gastric trichobezoars cause epigastric pain, nausea, vomiting, and anorexia and, as they grow larger, the gastric outlet becomes affected (Shigeyoshi Aoi, 2015; Alsafwah, 2000; O'Sullivan, 2001; Jensen, 2005). However, SBO occurs in fewer than 10 % of patients with trichobezoars (Shigeyoshi Aoi, 2015; Vaughan, 1968; Krol, 2001). Although simultaneous trichobezoars in the stomach and small intestine have been reported previously (Alsafwah, 2000; Klipfel, 2003; Hoover, 2006). In our case we reported our experience with a 27 years old lady presented with simultaneous gastric and intestinal bezoar which was causing both gastric outlet obstruction and small bowel obstruction. Diagnosis was made based on the clinical evidence of obstruction and the computed tomography images. In the literature review in the management of trichobezoar therapeutic intervention needs to encompass removal of the mass and prevention of recurrence by addressing the underlying physical or emotional cause. Depending on its consistency, size, and location, bezoar removal may occur via endoscopy or surgery. Endoscopic therapy can be effective for bezoars composed of vegetable matter (phytobezoars) and milk curd (lactobezoars), as they are small in size, but is less likely to be effective for trichobezoars, particularly those that are large (>20 cm). (Ahmed Youssef Altonbary, 2004 and Gonuguntla, 2009) studies showed that large and symptomatic trichobezoars must be removed surgically via an open or laparoscopic approach (Shigeyoshi Aoi, 2015; Nirasawa, 1998; Hussain, 2007). With laparoscopy this procedure is far more challenging. The risk of spilling contaminated hair fragments into the abdominal cavity makes the laparoscopic approach even less attractive (Gorter, 2010).

In conclusion

Trichobezoars should be considered one of the differential diagnosis of acute abdomen in young female with background psychiatric problem. In treating of obstructing trichobezoars early consideration of conventional laparotomy can save the patient from devastating perforation and peritonitis.

REFERENCES

Ahmed Youssef Altonbary, Monir Hussein Bahgat, Journal of Translational Internal Medicine / APR-JUN 2015 / VOL 3 | ISSUE 2
 Alsafwah S, Alzein M. 2005. Small bowel obstruction due to trichobezoar: role of upper endoscopy in diagnosis. *Gastrointest Endosc.* 52:784–6.
 Bouwer, C., Stein, D.J. 1998. Trichobezoars in trichotillomania: case report and literature review. *Psychosom Med.*, 73:653–656
 Carr, J.R., Sholevar, E.H., Baron, D.A. 2006. Trichotillomania and trichobezoar: a clinical practice insight with report of illustrative case. *J Am Osteopath Assoc.*, 106:647–652
 Debakey, M., Oschner, A. 1939. Bezoars and concretions, comprehensive review of literature with analysis of 303 collected cases and presentation of 8 additional cases. *Surgery* 5:132–160

Diefenbach, GJ, Reitman D, Williamson DA, 2000. Trichotillomania: a challenge to research and practice. *Clin Psychol Rev.*, 289–309
 Frey, A.S., McKee, M., King, R.A., Martin, A. 2005. Hair apparent: Rapunzel syndrome. *Am J Psychiatry.*, 162:242–8.
 Gonuguntla, V., Joshi, D. D. 2009. Rapunzel syndrome: a comprehensive review of an unusual case of trichobezoar, *Clin. Med. Res.* 7., 99–102.
 Gonuguntla, V., Joshi, D.D. 2009. Rapunzel syndrome: A comprehensive review of an unusual case of trichobezoar. *Clin Med Res.*, 7:99-102.
 Gorter, R. R., Kneepkens, C. M. F. *Pediatr Surg Int* (2010) 26:457–463
 Hoover K, Piotrowski J, Pierre K, Katz A, Goldstein AM. Simultaneous gastric and small intestinal trichobezoars—a hairy problem. *J Pediatr Surg.* 41:1495–7.
 Hussain, A.A., Geddoa, E., Abood, M., Alazzawy, M.T. Trichobezoar causing small-bowel obstruction. *S Afr Med J.*, 97:343–4.
 Jensen, A.R., Trankiem, C.T., Lebovitch, S., Grewal, H. 2005. Gastric outlet obstruction secondary to a large trichobezoar. *J Pediatr Surg.* 40:1364–5.
 Klipfel AA, Kessler E, Schein M. Rapunzel syndrome causing gastric emphysema and small bowel obstruction. *Surgery.*, 133:120–1.
 Krol, C.M., Karol, I., Khalil, H., Shah, S. 2001. Small-bowel obstruction due to migratory trichobezoar in a child: CT diagnosis. *Am J Roentgenol.* 177:255–6.
 Malpani, A., Ramani, S.K., Wolverson, M.K. 1988. Role of sonography in trichobezoars. *J Ultrasound Med.* 7: 661-3.
 Mateřju, E., Duchanřová, S.P. Kovac, N. Moravansky, D.J. Spitz, 2009. Fatal case of Rapunzel syndrome in neglected child, *Forensic Sci. Int.* 190., e5–e7.
 Mewa Kinoo, S. Singh, B. 2012. Gastric trichobezoar: an enduring intrigue, *Case Rep. Gastrointest. Med.* (2012).
 Nirasawa Y, Mori T, Ito Y, Tanaka H, Seki N, Atomi Y. Laparoscopic removal of a large gastric trichobezoar. *J Pediatr Surg.*, 33:663–5.
 O'Sullivan, M.J., McGreal, G., Walsh, J.G. Redmond, H.P. 2001. Trichobezoar. *J R Soc Med.*, 94:68–70.
 Sehgal, V.N., Srivastava, G. 2006. Trichotillomania ± trichobezoar: revisited. *Eur Acad Dermatol Venereol*, 20: 911-5.
 Sehgal, V.N., Srivastava, G. 2006. Trichotillomania ± trichobezoar: revisited. *J Eur Acad Dermatol Venereol* 20:911–915
 Shigeyoshi Aoi • Kouseki Kimura, *Surg Today* 2015. 45:634–637
 Shorter, E. 2005. A historical dictionary of psychiatry. Oxford University Press: New York.
 Tamini, N., Pinotti, E. Uggeri, F. Gianotti, L. 2016. Chronic gastric obstruction due to giant trichobezoar in an adult with Rapunzel syndrome, *J. Dig. Liver Dis.*, 48 (April (4)) 452.
 Vaughan, E.D., Sawyers, J.L., Scott, H.W. 1968. The Rapunzel syndrome. an unusual complication of intestinal bezoar. *Surgery.* 63:339–43.
