



## REVIEW ARTICLE

### AN UNDESIRABLE FUSION: TEMPOROMANDIBULAR JOINT ANKYLOSIS

Dr. Ashim Roy, Dr. Rahul Maheshwari, Dr. Soumyarup Sen, Dr. Alisha Dey and \*Dr. Rajashekar

#3 Srinivasa Complex, Hosahalli road, Hunasemarana Halli, Bengaluru -562157, India

#### ARTICLE INFO

##### Article History:

Received 18<sup>th</sup> March, 2018  
Received in revised form  
25<sup>th</sup> April, 2018  
Accepted 29<sup>th</sup> May, 2018  
Published online 30<sup>th</sup> June, 2018

##### Key words:

Temporomandibular,  
Fusion,  
TMJ,  
TJR.

#### ABSTRACT

Temporomandibular joint (TMJ) ankylosis results in the mandible being fused to the articular fossa by bony or fibrotic tissues. This interferes with several functions such as mastication, speech, oral hygiene, and normal life activities, and can be potentially life threatening especially while trying to acquire an air way in an emergency. Attempting to open the mouth, stretching the periosteum, can also result in pain. Multiple factors can result in TMJ ankylosis, such as trauma, arthritis, infection, previous TMJ surgery, congenital deformities, idiopathic factors, and iatrogenic causes of which trauma is the commonest cause. In growing patients TMJ ankylosis results in dentofacial deformity with severe trismus. Diagnosis usually is made by clinical examination and imaging studies, such as plain films, orthopantomograms, computed tomography (CT) scans, MRI, and three dimensional reconstruction. The management goal in TMJ ankylosis is to increase the patient's mandibular function, correct associated facial deformity, decrease pain, and prevent reankylosis. Multiple surgical modalities including gap arthroplasty, interpositional arthroplasty, and total joint reconstruction (TJR) has been suggested. Autogenous tissues, such as ear cartilage, temporalis muscle flap, dermis, fat, and bone, have also been used or after gap arthroplasty. Distraction osteogenesis has also been used to manage TMJ ankylosis with release of ankylosis before and after the distraction process. The common post operative complications include reankylosis, resorption, overgrowth, fracture, and pain.

Copyright © 2018, Rajashekar. This is an open access article distributed under the Creative Commons Attribution License, which permits unrestricted use, distribution, and reproduction in any medium, provided the original work is properly cited.

Citation: Rajashekar, 2018. "An undesirable fusion: Temporomandibular joint ankylosis", *International Journal of Current Research*, 10, (06), 70553-70556.

#### INTRODUCTION

Temporomandibular joint (TMJ) is the only movable joint in the face that plays a very important role in aiding mastication, thus aids in survival of life indirectly. It is diarthroidal synovial joint formed by the articulation of the condyle of the mandible with the articular fossa of the skull. It is one of the most important joints of the body. It consists of Condyle of the Mandible, Temporal fossa, articular disc and joint capsule. TMJ ankylosis is a condition characterized by bony or fibrous union of the condyle to the articular fossa. It is a serious and disabling condition that may cause problems in facial growth, mastication, swallowing, digestion, speech, appearance, and poor oral hygiene with rampant caries. Facial asymmetry develops if only one side is affected. Disturbances of facial and mandibular growth and acute compromise of the airway invariably result in physical and psychological disability (Pavankumar *et al.*, 2011).

The treatment of TMJ ankylosis poses a significant challenge because of technical difficulties and high incidence of recurrence (Loveless *et al.*, 2010). The aim of treating TMJ ankylosis is to re-establish the functioning of the joint, such that normal functions of mastication, deglutition, speech etc. can be performed. There are various treatment options available including, gap arthroplasty, resection of the ankylosed part, reconstruction of the joint, interpositional flap, distraction osteogenesis etc. This article presents a review on TMJ ankylosis and the various treatment options available for the same.

#### DISCUSSION

The TMJ is so designed such that it allows both rotation and translational movement. The term ankylosis is of Greek origin meaning "bent or crooked". TMJ ankylosis results in a stiff joint, with decreased or almost nil functioning. There are two types of TMJ ankylosis, one being the true TMJ ankylosis which involves the joint and the false ankylosis which is of extracapsular variety (Kazanijan, 1938). According to the tissue that grows in the intracapsular area, the ankylosis is classified into bony, fibrous or mixed (Akama *et al.*, 2009; Motta *et al.*, 2007). Taking into account the degree of TMJ mobility limitation, Sawhney (Sawhney, 1986) divided TMJ ankylosis into 4 types:

\*Corresponding author: Dr. Rajashekar,

#3 Srinivasa Complex, Hosahalli road, Hunasemarana Halli, Bengaluru -562157, India.

DOI: <https://doi.org/10.24941/ijcr.29520.06.2018>

- **Type I:** The head of the condylar process is visible but significantly deformed, with the fibroadhesions making TMJ movement impossible.
- **Type II:** Consolidation of the deformed head of the condylar process and articular surface occurs mostly at the edges and in the anterior and posterior parts of the structures, and the medial part of the surface of the condylar head remain undamaged.
- **Type III:** The ankylotic mass involves the mandibular ramus and zygomatic arch; an atrophic and displaced fragment of the anterior part of the condylar head is in a medial location.
- **Type IV:** TMJ is completely obliterated by bony ankylotic mass growing between the mandibular ramus and cranial base (Figure 1). Taking into account heterotopic bone formation within the ankylotic mass, temporomandibular ankylosis was classified by Turlington and Durr (Durr *et al.*, 1993) into 4 grades.

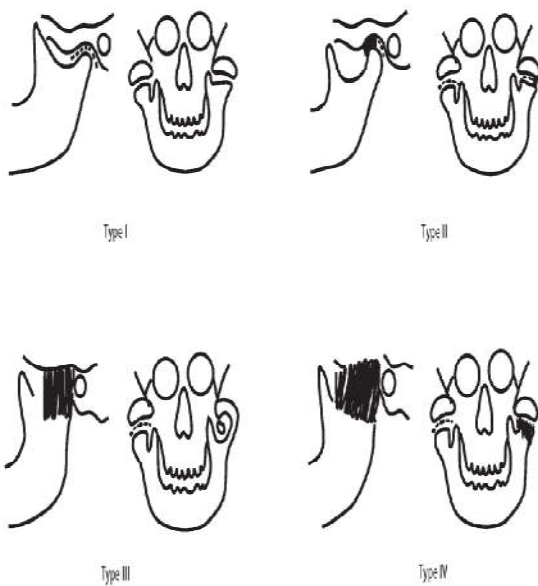


Figure 1. TMJ Classification by Sawhney

- **Grade 0:** No bone islands visible.
- **Grade 1:** Islands of bone visible within the soft tissue around the joint.
- **Grade 2:** Periarticular bone formation.
- **Grade 3:** Apparent bony ankylosis.

Grades 1, 2 and 3 are further classified as symptomatic (S) and asymptomatic (A). The symptomatic ossification includes: severe pain, decreased interincisal opening (15 mm or less), closed locking of the jaw, or decreased lateral or protrusive movement. False ankylosis (Miller *et al.*, 1975) is further classified into

- Myogenic
- Neurogenic
- Psychogenic
- Morphogenic
- Bone impingement
- Tumors
- Fibrous adhesion Raveh *et al* classification of TMJ ankylosis

- **Class I:** Ankylotic bony tissue limited to the condylar process and articular fossa.
- **Class II:** The bone extends out of the fossa involving the medial aspect of the skull base up to the carotid-jugular vessel.
- **Class III:** Extension and penetration into the middle cranial fossa
- **Class IV:** Combination of class II and III.

**Etiology:** The most common cause of TMJ ankylosis includes trauma and local or systemic infection. Inadvertant force applied by forceps during forceps delivery of the baby, damages the TMJ leading to improper development or most commonly TMJ ankylosis. Other etiological factors are: myositis ossificans, osteochondroma, rheumatoid arthritis, ankylosing spondylitis (Bechterew Disease), psoriatic arthritis, systemic lupus erythematosus, radiotherapy or surgical treatment of TMJ. TMJ ankylosis has also been described as a complication after orthognathic surgery (Katarzyna *et al.*, 2011). TMJ ankylosis may occur during development or after completion of growth. Thus, 4 groups of affected patients may be distinguished (Loveless *et al.*, 2010).

- Growing patients without dentofacial deformities;
- Growing patients with dentofacial deformities;
- Adults without dentofacial deformities;
- Adults with dentofacial deformities.

Each of these 4 groups requires an individual treatment protocol owing to its specific character and different clinical manifestations.

**Clinical features:** The clinical of feature of TMJ ankylosis are as follows.

#### Unilateral ankylosis

- Facial asymmetry
- Deviation of chin and mandible to the affected side
- Hypoplasia of mandible of affected side
- Unaffected side flat and elongated due to normal growth
- Well defined antegonial notch on the affected side
- Limited mouth opening
- Class III malocclusion on the affected side with posterior crossbite on the ipsilateral side.

#### Bilateral ankylosis

- Mouth opening restricted. Mandible is symmetrical but micrognathic. Typical 'bird face' deformity.
- Antegonial notch bilaterally present
- Class II malocclusion
- Crowding and many impacted teeth with poor oral hygiene
- Anterior open bite with protrusive incisors.

#### Radiographic examination

- Orthopantomograph
- Arthrography
- Magnetic resonance imaging
- TMJ tomography

- Computed tomography imaging

**Treatment:** While dealing with TMJ ankylosis, the most commonly followed protocol is the Kaban's protocol which includes.

- Aggressive resection of the fibrous or bony mass
- Ipsilateral coronoidectomy
- Contralateral coronoidectomy (intraoral approach) if mouth opening is less than 35mm.
- Lining of the TMJ with temporal fascia
- Reconstruction of the TMJ with a costochondral graft
- Rigid fixation
- Early mobilisation and aggressive physiotherapy

#### On summarising the surgical treatment procedures include

- Arthroplasty of the joint cavity.
- Arthroplasty and a free costochondral graft (Medra, 2005).
- Arthroplasty with temporalis myofascial flap insertion in the newly created joint cavity accompanied by a simultaneous unilateral coronoidectomy on the affected side or a bilateral coronoidectomy.
- Distraction of the ramus and body of the mandible on the affected side.
- Reconstruction of the joint using an alloplastic prosthesis (Mercuri, 2006; Mercuri *et al.*, 2008).
- Arthroscopic laser-assisted preparation of the articular surfaces (Moses *et al.*, 1999).
- Postoperative radiotherapy (Durr *et al.*, 1993; Reid and Cooce, 1999).
- Bilateral arthrotomy.

According to current knowledge, surgical treatment should not be postponed. Based on the Moss functional matrix theory, the surgery and function restoration of both the bones and neighbouring soft tissues release the growth potential of the mandible and prevent further development of the deformity (Moss and Rankow, 1968). With the availability of various surgical techniques for the correction of TMJ ankylosis, it becomes pertinent to decide the right timing for treating it. It's necessary to note that ankylosis correction must not be delayed in children, because any disturbance in growth and development of TMJ will influence and lead to maldevelopment of surrounding structures and mandible. Theoretically, autogenous grafts should grow together with the patient. In practice, however, post-surgical performance of grafts involves undesirable phenomena such as resorption, unpredictable overgrowth, secondary asymmetry and even re-ankylosis (Perrott *et al.*, 1994; Kaban and Perrott, 1992). Based on research reports (Ellis *et al.*, 2002; Perrott and Kaban, 1994) and clinical observations, the appropriate preparation and immobilization of the costochondral graft with the residual ramus of the mandible are considered critical. The intermaxillary fixation following reconstruction with a costochondral graft is maintained for approximately 10 days and then aggressive mouth-opening exercising begins. It is stated that prolonged postponing surgery is a mistake because it results in a gradual deterioration of the condition. Three-year-old children are able to cooperate well during the post-operative rehabilitation. Aggressive physiotherapy should be continued for approximately 1 year following the operation (Matsuura *et al.*, 2001). Early surgery also improves the psychosocial development of a child through the restoration of

a normal facial appearance, the ability to enjoy eating, maintain oral hygiene and obtaining regular dental treatment. In adults however, reconstruction with a free costochondral rib graft may be applied only in a limited number of cases due to the histomorphology of the rib of the fully grown patient. The rib is primarily composed of cortical bone, with only a small amount of cancellous bone. The capability of the graft to become incorporated into the host bone depends mostly on the local soft tissue at the donor site, as well as its ability to revascularize and take over the necessary functions. Vascularity of the recipient site becomes compromised due to the scar tissue resulting from preceding surgical procedures. Capillary vessels are able to penetrate the tissue to a depth of 180–220 µm, while the thickness of the scar tissue surrounding the bones which had already been submitted to surgery is 440 µm. This fact has to be taken into account while planning another reconstruction surgery with a free bone graft (Mercuri, 1998). The advantage of distraction osteogenesis over other treatment methods means it is possible to initiate physiotherapy on the day following surgery, and there is no need to harvest bone from a donor site for the graft.

This is extremely important in juvenile patients because it does not impose restrictions on their normal activity and involves no risk of a complication at the donor site (such as wound infection or oedema in the case of a rib graft). Another advantage is the simultaneous gradual soft tissue adaptation during distraction. It is also of importance that the amount and direction of bone lengthening is quite predictable, since the callus distraction may be controlled. A disadvantage of this is the fact that the distraction device has to remain in place for the period of distraction and subsequent bone healing. The high cost of the distraction device is also of importance (Katarzyna *et al.*, 2011). Following the treatment of ankylosis it becomes necessary to perform revision surgeries to correct facial deformities or any irregular growth pattern. Patient must be followed up with proper orthodontic treatment to aid normal development and correct malocclusions if any. Obviously, routine follow up is necessary without any mention.

#### Conclusion

As an unfavourable fusion, TMJ ankylosis results in slight functional disability to severe and gross anatomical and physical disability. Correcting TMJ ankylosis is very challenging with no hard and fast rule on the method of correction. But it's the role of Oral and Maxillofacial surgeons to assess, plan and treat the condition with aggressive motivation and precision, with an aim to restore normal or near normal functioning of the joint.

#### REFERENCES

- Akama, MK., Guthua, S., Chindia, ML. and Kahuho, SK. 2009. Management of Bilateral Temporomandibular Joint Ankylosis in Children: Case Report, *East African Medical J.*, 86(1): 45–48.
- Durr, ED., Turlington, EG. and Foote, RL. 1993. Radiation treatment of heterotopic bone formation in the temporomandibular joint articulation. *Int J Radiat Oncol Biol Phys.*, 27: 863–69.
- Durr, ED., Turlington, EG. and Foote, RL. 1993. Radiation treatment of heterotopic bone formation in the temporomandibular joint articulation. *Int J Radiat Oncol Biol Phys.*, 27: 863–69.

- Ellis, E., Schneiderman, ED. and Carlson, DS. 2002. Growth of the mandible after replacement of the mandibular condyle: An experimental investigation in Macacumulatta. *J Oral Maxillofac Surg.*, 60: 1461–71.
- El-Mofty, S. 1979. Cephalometric studies of patients with ankylosis of the temporomandibular joint following surgical treatment. *Oral Surg.*, 48: 92–96.
- Kaban, LB. and Perrott, DH. 1992. Discussion: Unpredictable growth pattern of costochondral graft. *Plast Reconstr Surg.*, 90: 887–89.
- Katarzyna, ST., Joanna, JO. and Robert, K. 2011. Management of temporomandibular ankylosis – compromise or individualization – a literature review. *Med Sci Monit*, 17(5): 111–116.
- Kazanijan, VH. 1938. Ankylosis of the temporomandibular joint. *Surg Gynecol Obstet.*, 67: 333–48
- Loveless, TP., Bjornl, T., Dodson, TB. and Keith, DA. 2010. Efficacy of Temporomandibular Joint Ankylosis Surgical Treatment. *J Oral Maxillofac Surg.*, 68: 1276–82.
- Matsuura, H., Miyamoto, H., Ishimaru, J-I., *et al.*, 2001. Effect of partial immobilization on reconstruction of ankylosis of the temporomandibular joint with an autogenous costochondral graft: an experimental study in sheep. *Br J OMS.*, 39: 196–203.
- Medra, AMM. 2005. Follow up of Mandibular Costochondral Grafts after Release of Ankylosis of the TMJ. *Br J Oral Maxillofac Surg.*, 43: 118–22.
- Mercuri, LG. 1998. Alloplastic temporomandibular joint reconstruction. *J Oral Surg.*, 85: 631–37.
- Mercuri, LG. 2006. Alloplastic vs. Autogenous Temporomandibular Joint Reconstruction. In *Oral and Maxillofacial Surgery Clinics of North America*. Indresano AT, Haug RH (eds) Elsevier, Philadelphia. Vol 18. No 3. 399–411.
- Mercuri, LG., Alcheikh Ali, F. and Woolson, R. 2008. Outcomes of Total Alloplastic Replacement with Peri-articular Autogenous Fat Grafting for Management of Re-ankylosis of the Temporomandibular Joint. *J Oral Maxillofac Surg.*, 66: 1794–803.
- Moses, JJ., Lee, J. and Arredondo, A. 1999. Arthroscopic laser debridement of the temporomandibular joint fibrous and bony ankylosis: case report. *J Oral Maxillofac Surg.*, 56: 1104–6.
- Moss, ML. and Rankow, RM. 1986. The role of the functional matrix in mandibular growth. *Angle Orthod.*, 38: 95–103
- Motta, A., Louro, RS., Medeiros, PJ. and Capelli, J. 2007. Orthodontic and surgical treatment of a patient with an ankylosed temporomandibular joint. *Am J Orthod Dentofacial Orthop*, 131: 785–96.
- Pavankumar, JV., Nitin, B. and Rajiv, NB. 2011. TMJ Ankylosis: Multidisciplinary Approach of Treatment for Dentofacial Enhancement—A Case Report. *Case Reports in Dentistry*; Volume 2011, Article ID 187580, 7 pages doi:10.1155/2011/187580.
- Perrott, DH. and Kaban, LB. 1994. Temporomandibular joint ankylosis in children. *Oral Maxillofac Clin North Am.*, 6: 187–99.
- Perrott, DH., Umeda, H. and Kaban, LB. 1994. Costochondral graft construction/reconstruction of the ramus/condyle unit: Long-term follow-up. *Int J Oral Maxillofac Surg.*, 23: 321–28.
- Reid, RR. and Cooce, H. 1999. Postoperative ionizing radiation in the management of heterotopic bone formation in the temporomandibular joint. *J Oral Maxillofac Surg.*, 57: 900–5.
- Sawhney, CP. 1986. Bony ankylosis of the temporomandibular joint: follow-up of 70 patients treated with arthroplasty and acrylic spacer interposition. *Plast Reconstr Surg.*, 77: 29–38.

\*\*\*\*\*