



ISSN: 0975-833X

Available online at <http://www.journalcra.com>

International Journal of Current Research
Vol. 11, Issue, 01, pp.719-720, January, 2019

DOI: <https://doi.org/10.24941/ijcr.34042.01.2019>

**INTERNATIONAL JOURNAL
OF CURRENT RESEARCH**

RESEARCH ARTICLE

A CASE OF VIPER BITE RESULTING IN MASSIVE INFARCTION IN BRAIN

¹Dr. Sandipan Mukherjee and ²Dr. Samiran Misra

¹Senior Resident, Purba Medinipur District Hospital

²Medical Officer, Purba Medinipur District Hospital

ARTICLE INFO

Article History:

Received 17th October, 2018

Received in revised form

26th November, 2018

Accepted 19th December, 2018

Published online 31st January, 2019

Key Words:

Viper bite, Cerebral infarction,
Deranged renal function.

Copyright © 2019, Dr. Sandipan Mukherjee and Dr. Samiran Misra. This is an open access article distributed under the Creative Commons Attribution License, which permits unrestricted use, distribution, and reproduction in any medium, provided the original work is properly cited.

Citation: Dr. Sandipan Mukherjee and Dr. Samiran Misra. 2019. "A case of viper bite resulting in massive infarction in brain", *International Journal of Current Research*, 11, (01), 719-720.

ABSTRACT

Russell's Vipers cause vasculotoxic features resulting in acute kidney injury, bleeding manifestation. In our case a 50 years old man with history of snake bite was presented in casualty. He was unconscious; 20 minute whole blood clotting time was deranged, and renal function was abnormal. CT scan of head showed large area of infarct in left hemisphere. Though cerebral hemorrhage is much common, cerebral ischemia following viper bite is an uncommon feature. Despite treatment, anti snake venom and supporting measures the patient could not regain consciousness and eventually succumbed to death.

INTRODUCTION

Snake bites are common health hazards in India. The major families of snakes in India are elapidae which includes common cobra, king cobra and common krait; viperidae includes Russell's viper, saw scaled viper and pit vipers and hydrophiidae (sea snake). Vasculotoxic Russell's Vipers (*Daboia siamensis* and *D. russelii*) snake bites are well known to cause local cellulitis, local tissue necrosis, bleeding manifestations, disseminated intravascular coagulation (DIC), acute kidney injury (AKI), shock, cardiac arrhythmia, neurotoxicity, coma, and death.

Case Presentation

A 50 year old gentleman presented to the casualty in unconscious state with history of snake bite 1 hour back with swelling and redness over right foot. On examination his GCS was 7/15 (E2V2M3); Pupil mid dilated reacting bilateral equally; Planter bilateral non responsive; Temperature 98.4^oF; Pulse 88/min, regular; BP 118/74 mm Hg; Spo2 93% in room air. Upon Foley's catheterisation there was 150 ml reddish urine. No other bleeding manifestations were present. Biochemical parameters were as follows: 20 min Whole Blood Clotting Time (20WBCT) was 31 minutes; Capillary Blood Glucose 160 mg/dl; Urea 36.4 mg/dl; Creatinine 1.25 mg/dl; other haematological parameters were within normal limit.

The patient was given 10 vials of AVS via intravenous route initially and the 20WBCT was repeated 6 hourly. On the basis of 20WBCT patient was given a total 30 vials of AVS. As the patient developed laboured breathing and the Spo2 was deteriorating, atropine and neostigmine were administered and he was put on mechanical ventilation ACMV mode with FiO2 80% and PEEP 5 cm H2O. Second day onwards urea and creatinine levels started rising gradually though the 20WBCT has been returned to normal. By the 4th day urea and creatinine was 122 and 3.89 mg/dl respectively. Hemodialysis was contemplated as there was no improvement in urine volume.

In the mean time a CT scan of head has been done. The scan revealed a large area of infarct over the left capsulo-ganglionic region with midline shift. Despite repeated attempts from our side the relatives of the patient did not give consent for hemodialysis. As a result on 10th day after admission his urea and creatinine report was as high as 337 and 12.6 mg/dl respectively. Patient succumbed to death on the 12th day after admission.

DISCUSSION

The patient suffered from AKI as well as Ischemic CVA following Viper bite confirmed by biochemical and radiological evidence. Cerebral ischemia is a rare complication in viper bite (Bashir, 1985; Kurian, 1989 and Byung-chul Lee, 2001). There are many hypotheses regarding cerebral infarct.

*Corresponding author: Dr. Sandipan Mukherjee,
Senior Resident, Purba Medinipur District Hospital

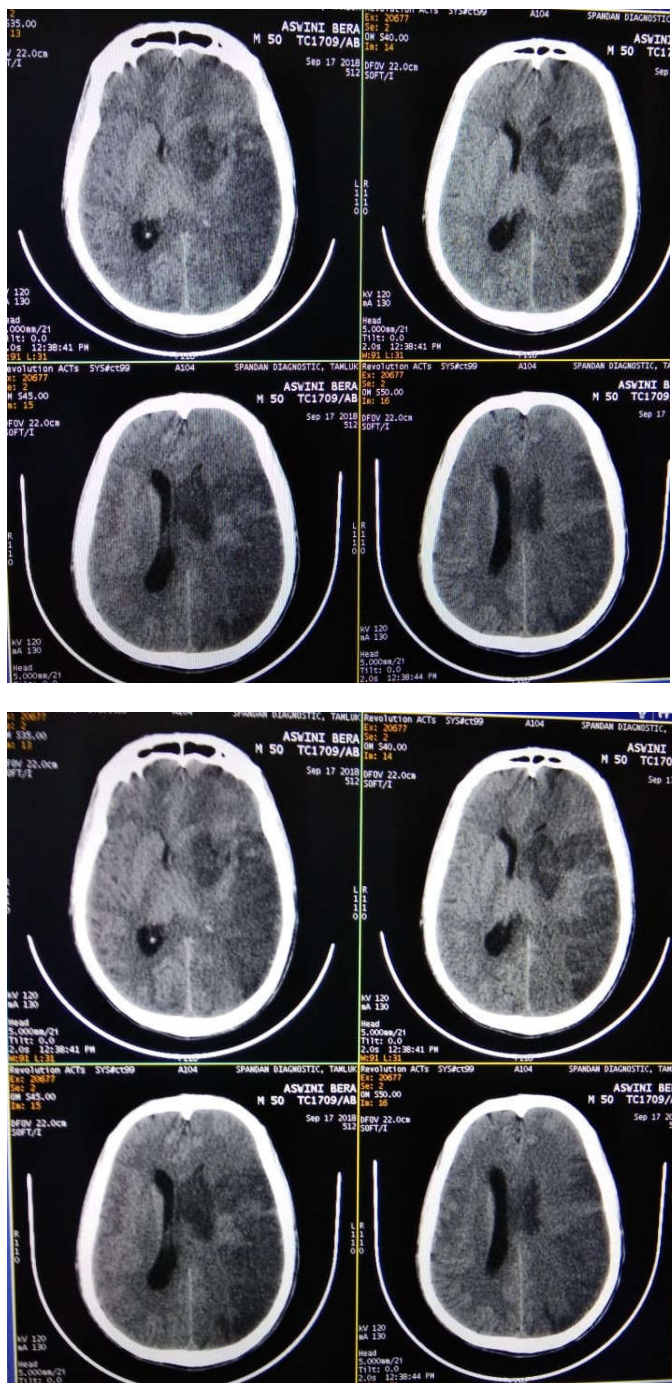


Figure 1. CT scan of head showing large infarct at left temporo-parietal lobe involving left capsulo-ganglionic complex with midline shift to right side

Russell's Viper venom contains procoagulant enzymes which activate factor V and X in the blood coagulation cascade leading to fibrin cross-linkage and deposition of micro thrombi in the microvasculature. The coagulant action is also due to Arginine esterase hydrolase similar in action to thrombin, clots fibrinogen and aggregates platelets.

Vascular endothelial damage is also done by direct action of toxins leading to release of vascular endothelial growth factor and von Willebrand's factor resulting in consumption coagulopathy stage of DIC. Direct cardiotoxic effect of viper venom resulting in dysrhythmias, can lead to cardiac thromboembolism, and subsequent cerebral ischemia. Toxin mediated vascular spasm and endothelial damage results in toxic vasculitis and cerebral infarction. Hypotension due to vasodilatation and loss of vasomotor tone provoked by the viper toxin can lead to ischemic state. AKI in viper bite is mainly due to tubular damage. Viper venom itself, hemoglobinuria, hypotension, microthrombi in the kidney contribute to the acute tubular necrosis and serial rise in blood urea and serum creatinine with acidosis and hyperkalemia, generalized anasarca, renal failure. Rhabdomyolysis and myoglobinuria can contribute to renal tubular damage.

Conclusion

Russell's Viper (*Daboia russelii*, *D. siamensis*) are among the most dangerous snakes to be found in south Asia including India, accounting for thousands of death per year. It has variety of complications but the coagulation disorder is the most dreaded complication of all. Our patient presented with both hematotoxic and neurotoxic complications after the bite. After a pool of clinical, biochemical and radiological examinations it became evident that the patient suffered from AKI and ischemic CVA due to snake venom induced coagulation disorder. Though acute kidney failure is quite common in the setting of viper bite, cerebral infarct as in this case is not so common in our day to day experience. It needs a strong suspicion in the part of the clinician to identify such cases and rapid intervention can be live saving.

REFERENCES

- Bashir R, Jenkins J. 1985. Cerebral infarction in a young female following snake bite. *Stroke.*, 16:328–30.
- Byung-chul Lee, Sung-Hee Hwang, Jae-Chun Bae, Seok-Bum Kwon. 2001. Brainstem infarction following Korean viper bite. *Neurology.*, 56:1244–5
- Kurian J, Thomas M, Krishna Das KV. 1989. Stroke following snake bite. *J Assoc Phys Ind.*, 37:38.
- Panicker JN, Madhusudan S. 2000. Cerebral infarction in a young male following viper envenomation. *J Assoc Physicians India.*, 48:744–5.
