



ISSN: 0975-833X

Available online at <http://www.journalcra.com>

INTERNATIONAL JOURNAL
OF CURRENT RESEARCH

International Journal of Current Research
Vol. 11, Issue, 04, pp.3082-3086, April, 2019

DOI: <https://doi.org/10.24941/ijcr.34989.04.2019>

RESEARCH ARTICLE

ADVANCING FRONTS OF PATHOLOGY

¹Sapna Chandran, L., ²Krishnapillai Rekha, ³Ramakrishnan Bindhu, P. and ⁴Thomas Priya

¹Post graduate student, ³rd year, Dept of Oral Pathology and Microbiology, Annoor Dental College and Hospital, Muvattupuzha, Kerala

^{2,3,4}Dept Of Oral Pathology and Microbiology, Annoor Dental College and Hospital, Muvattupuzha, Kerala

ARTICLE INFO

Article History:

Received 19th January, 2019
Received in revised form
16th February, 2019
Accepted 10th March, 2019
Published online 30th April, 2019

Key Words:

Digital Pathology,
Surgical Pathology,
Whole Slide Imaging,
Microscopy, Telepathology.

*Corresponding author: Olkeba Assefa

Copyright ©2019, Sapna Chandran et al. This is an open access article distributed under the Creative Commons Attribution License, which permits unrestricted use, distribution, and reproduction in any medium, provided the original work is properly cited.

Citation: Sapna Chandran, L., Krishnapillai Rekha, Ramakrishnan Bindhu P. and Thomas Priya. 2019. "Advancing fronts of pathology", International Journal of Current Research, 11, (04), 3082-3086.

ABSTRACT

Pathology is a branch of medical science that help in diagnosing the disease by microscopic examination and revealing the information to render correct diagnosis and help in proper treatment planning. Recent advances in technology has put a significant impact in the diagnostic field of pathology. Introduction of slide less pathology also known as Virtual Microscopy or Whole slide imaging (WSI) is not mere an imagination but an upcoming and promising invention. It is highly demanded in everyday pathology as well as in educational, research purpose and bioindustry. Even though these advances are faced with significant challenges such as data storage, image compression, they also provide guidance to newer diagnostic approach. These can also minimize the interobserver variability, diagnostic dilemma, identifies the therapeutic pathways and predicts the patient responses to therapy. Hence the promise of digital pathology is not the simple transfer of an image to monitor, but rather an upgradation with information that cannot be garnered by human examination. This article aims to introduce and discuss the important aspects of this evolving technology.

INTRODUCTION

An early introduction to Digital pathology or Whole slide imaging (WSI) system was credited to Wetzel and Gilbertson in 1999 and since then, it is continuously being monitored and modified. It uses high speed, high-resolution digital acquisition of images of the entire slide or selected area of it and these images can be viewed on computers and laptops with required field of magnification (Ghaznavi *et al.*, 2013; Chandra, 2014). WSI scanners, robotic microscopes capable to automatically generate digital images from the glass slide are the equipment necessary for its functioning (Pantanowitz *et al.*, 2013) Few of its advantages are: easier mode of data transfer, qualitative and quantitative assurance, use in remote consultations and any time approach to analyze the slide. Previous literature suggest that digital pathology helps in better diagnosis, manipulation of digital images in innovative ways. Moreover, it helps in second opinion, telepathology, reviewing, sharing and for educational and research purposes. But compared to the conventional light microscopy, its diagnostic accuracy needs to be more evaluated and standardized. Hence a wider acceptance is not yet achieved regarding its high technical insets, high costs and also due to technophobia of pathologists (Pantanowitz, 2010).

Digital slides: Digital pathology utilizes a virtual microscope, which is a trinocular microscope with advanced controls of various adjustments like movement of the mechanical stage, illumination, objective, coarse and fine focusing of the lens. These enables the use of digital images which are analog images composed of pixels represented using binary numbers of ones and zeros. Digital imaging has four important steps (Pinco *et al.*, 2009).

- Image acquisition
- Storage and management,
- Editing
- Display and transmission of images.

Whole slide imaging: This process adopts the technology of digitalization wherein the slides are kept on the stage and scanned using high speed digitization in a tile or linear pattern under a required magnification. This is followed by capturing of several pictures in pixels by the automatic movement of the equipment, hence the name "Digital Scanner". These images are further compiled with the help of a software to produce a final picture which is the replica of the representative section on the slide.

This image is called as digital slide or “e-slide” or virtual image or whole slide image. This demands high-speed internet and security measures to protect the information (Indu *et al.*, 2016; Karnovsky *et al.*, 2006). WSI can be categorized into bright field, fluorescence and multispectral. Most common and least expensive includes the bright field variety. Fluorescent WSI works similar to ordinary fluorescent microscope, mainly utilized for immunofluorescence and in situ hybridization (Krenacs *et al.*, 2010). Digital microscopy is also specialized in capturing spectral details across the visible range of light to near infrared bands to form the multispectral imaging. This can work along with fluorescent and bright field microscopy. Thus, it helps in overcoming the problems related to auto fluorescence in fluorescence microscopy, but it is slow and requires complex preparation of the sample (Levenson *et al.*, 2008).

Scanning procedure: Image acquisition takes place in long narrow strips in case of linear scanning whereas in tile scanning the slides are scanned in a series of rectangular tiles. Several methods of scanning principle are followed to focus the fields – these include “focus every field”, “focus every nth” field and “focus map method” (Parwani *et al.*, 2012; Montalto *et al.*, 2011)

Scan view	Scan field	Merits
Focus every field	Scan the entire field	Accurate but time consuming
Focus every nth field	Every nth field	Faster and simpler
Focus map method	Focus point distributed over the surface	Faster but less accurate

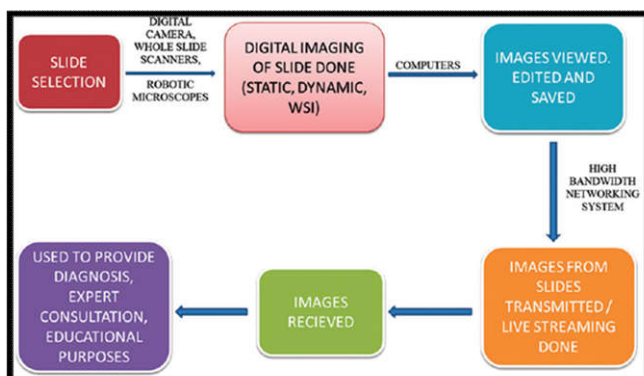
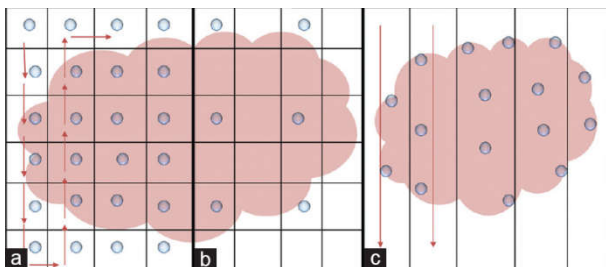


Figure 2. Steps in whole slide imaging

Figure 1: (a and b) Tile pattern of scanning. The arrows show direction of scanning. Blue dots in 1a indicate “focus every field” method. Dots in 1b indicate “focus every nth field” method. (Courtesy: Dr. Toby C. Cornish, PhD, Assistant Professor of Pathology, John Hopkins Medicine). (c) Linear pattern of scanning.

Blue dots in 1c indicate “focus map” method (= focus point, → = direction of scanning). Scanning of slides occur in multiple magnification and focal planes. These images are either auto loaded or smaller images are finally grouped to larger images with the help of software. These duplicate the exact section required in the slide and store it in computer for future use (Chandra, 2013). The image thus obtained can be modified in relation to brightness, contrast and color saturation if required. Quality of image obtained depends on the quality of the original slide to be scanned. It should be free of artifacts such as folds, knife marks, air bubbles, and stain deposits to get the best results.

Slide size: In addition to the scanning of traditional slides of size 75 × 25 mm, it can also analyze larger slides of size as big as 200 × 150 mm. Moreover 200 such slides can be analyzed and auto scanned resulting in a large file size up to several gigabits. These files are further compressed using Joint Photographic Experts Group (JPEG) or JPEG 2000 algorithms for storage convenience (Pantanowitz, 2012; Khushi, 2013)

Limitation of Conventional Microscopy (Chandra, 2013)

- Glass slides are fragile and tends to break
- Fading of stain with storage
- Difficult to retrieve
- Proper data with history needs to be stored
- Difficult for academic purpose

Advantages of whole slide imaging (Indu, 2016)

- High resolution
- Better color and contrast of images
- Short time scanning
- Fast image analysis
- Easily retrievable
- Easy portable
- Can be used for multiple opinions simultaneously
- Act as permanent record
- Used in online interaction

Disadvantages of whole slide imaging

- Demand high infrastructure
- Requires uninterrupted internet and power supply
- More technical problems associated with software and hardware problem
- Larger size difficult to retrieve
- Time consuming in few cases
- Difficulty to scan large tissue sections, 3D cell groups in cytology and thick smears
- Well trained technicians and pathologist required for proper handling of data

Applications of digital imaging

- Used for pathologic interpretations
- Used for education purpose
- Used for research purpose
- Used for tele communication

Role in pathologic interpretation: Digital microscopy helps in analysis of whole slide imaging at once making interpretations easier and faster.

Simultaneously many slides can be analyzed. Detail scanning is possible with enlarged view of each section possible. Can be viewed by multiple person at same time, hence avoiding inter-observer and intra-observer bias (Bhargava, 2016). Digital microscopy is entering into daily pathology practice. According to Krishnamurti *et al.* digital slides of breast carcinoma tissue gave a similar accuracy, precision and reproducibility in interpretation when compared to conventional microscopy (Krishnamurthy *et al.*, 2013).

Used for education purpose: Digital slides are being introduced into the education system in many institutions for undergraduate and staff training. One of the main disadvantages of conventional microscopy is that it does not allow simultaneous viewing of the slides by multiple students. This can be solved by using digital microscopy. The maintenance of numerous microscopes for teaching purpose in the laboratory can be avoided by using digital microscopy. Hence only one slide required for teaching hundreds of students. Moreover, the usage of glass slide examination can also be replaced with digital slides (Saco *et al.*, 2016; Fonseca *et al.*, 2015) These can also aid as material in scientific presentation in conferences and symposiums.

Used for research purpose: Digital microscopy can help resolve various drawbacks in using glass slide in FISH and genomic analysis. The small signal size and fading of nucleus during fluorescent techniques can be resolved by simultaneous scanning of several focal planes through the sample and maintaining a digital record. This can be used in procedures of tissue microarray and also in human genomic project such as in virtual tumor bank.

Used for tele communication: Communication methods through telecommunication are widely in practice now a days. WSI telepathology provide access to entire digital slide at a single time. This is especially useful in case of second consultation or shortage of pathologist in the hospital. Telepathology includes a digital work platform to attain digital images, telecommunication network to transmit images and monitor or screen to view the images. Nowadays it is used in telehematology, ultra structural telepathology other than surgical pathology (Evans, 2009). This helps in better resolution of images and in teleconferencing. Many factors need to be focused while setting telepathology such as the distance between the slide and the tele pathologist, the computer network, the bandwidth limitations etc. Technical issues such as scanning difficulties, hardware malfunctioning, image problems may arise (Pekmezci *et al.*, 2016).

WSI vs Microscopy: According to a study done by Mukhopadhyay S *et al* 2018, WSI is considered to be non-inferior to microscopy in diagnosing primary disease in biopsy and resection specimens when compared to H&E, immunochemistry and special staining (Mukhopadhyay *et al.*, 2018)

Computational interpretation of pathology imaging: The digitization of pathology imaging has made a tremendous improvement in the quantitative analysis through image processing. Interpretation of digital image include recognition and classification of cells, the characterization of microscopic structures that are multicellular or regional in nature and the quantification of antibody staining. The following features are analyzed (Cooper *et al.*, 2012):

Object segmentation: The shape, color and texture of segmented nuclei and their boundaries are detected.

Region segmentation: Often areas such as boundaries of blood vessel, lesions, and inflammation are observed in segments.

Feature extraction: It is the process of gathering informative descriptions of objects or regions, and often precedes classification or segmentation tasks. It is used to describe spatial characteristics, object characteristics such as shape or texture (useful for object classification), or a collection of segmented objects to describe group behavior.

Classification: Based on extracted features whole slides can be classified into different cell types, antibody activation etc.

Antibody quantification: Application of multiple stains highlighting both structure and antibody binding can subsequently be unmixed and evaluated using digital techniques (Ruifrok *et al.*, 2003)

Computer-Aided Diagnosis: It is the most active research area in pathology image analysis. Introduction of this system helps to reduce variability and error in diagnosis by emulating established diagnostic procedures. This system contains multiple module implementing object segmentation, region segmentation, and feature extraction for classifying the disease. Numerous systems have been developed such as follicular lymphoma (Belkacem-Boussaid, 2010; Cooper *et al.*, 2009; Sertel *et al.*, 2010), breast cancer (Basavanahally *et al.*, 2010; Madabhushi *et al.*, 2011; Van De Wouwer, 2000), colon cancer and neuroblastoma (Masood *et al.*, 2009; Kong *et al.*, 2008).

Limitations to digital pathology: Although the pathology imaging data is fast growing after the implementation of digital technology, yet there are few limitations in this field which holds back its use in regular practice.

Image size: A typical whole slide image is compressed with JPEG, reduces the image size to several giga bytes or hundreds of megabytes. A single scanning system generates hundreds of images daily and these images are stacked in multilayer providing a focus capability of tens of such images (Cooper *et al.*, 2012).

Low-latency access: A centralized server maintains the pathology images which are viewed remotely by the practitioners. Moreover, a proper zooming of the field for diagnostic purpose is achieved by low latency serving.

Unique compression requirements: Another challenge faced by pathologists are the appearance of compression artifact during diagnosis. These challenges are overcome by introduction of quantitative data generated by computational image analysis. These data represent the contents of a virtual pathology slide ranging from single individual cell to regional/textural descriptions of whole tissues at multiple resolutions. This newer addition can improve the potential role of digital pathology in the identification of novel therapeutic targets and survival predilection (Cooper *et al.*, 2012).

The future of digital pathology: Digitization and image analysis are expected to improve prognosis, therapeutics, and understanding of complex diseases like cancer. This may help

in research testbed where the molecular and imaging data can be associated with patient genome and morphology.

Classification of disease subtypes: Image analysis can be used to describe the shape and texture of hundreds of millions of cells using various features. Thus, diseases that have been traditionally diagnosed as single disease is discovered to have multiple subtypes, each with characteristic molecular foundations. Significant differences in expression for genes known to influence cell appearance including cell differentiation, cell lineage, and programmed death were analyzed using digital pathology (Cooper *et al.*, 2012).

Molecules identification in the Tumor Microenvironment

Earlier, imaging localized protein expression to individual cells using special techniques but simultaneous measurement of molecules was difficult. This problem was overcome by the development of recent technique called quantum dot, which provide spatial localization of molecules through fluorescence imaging. This advancement may provide transition from the laboratory to the clinic over the next decade and may be ubiquitous in pathology as magnetic resonance is in radiology (Tholouli *et al.*, 2008; Caldwell, 2008).

Storage enhancement: Various studies are in progress to improve the data storage capacity. Presently solid-state drives are in use which provide a low-latency data storage at smaller capacities than traditional hard disks. Further advancements such as multiple levels of coupled spinning drives and SSDs in RAID configurations are expected to come in forefront. These can improve the long-term storage and high-speed access for larger documentation. Hence further modifications in data transmission, effective compression and adequate compilation and computation reuse should be focused on for the smooth utilization of imaging techniques (Cooper *et al.*, 2012).

Deep learning for digital image analysis: Deep learning is a machine learning pattern of feature learning. The principle behind this method involves deriving a suitable feature space solely from the data itself. This is mainly adopted to analyze big data sources. It identifies feature such as (a) epithelium segmentation, (b) nuclei segmentation (c) lymphocyte detection, (d) mitosis detection, and (e) lymphoma classification thereby bridging the gap between digital pathology domain and deep learning (Janowczyk *et al.*, 2016). The steps followed in whole slide imaging is summarized below (Nishat *et al.*, 2017): The advances in imaging technologies are revolutionizing the pathologist's ability to rapidly capture the multidimensional data from each patient. Science is far advancing in this technological era. With the advent of digital pathology newer perspectives are being added to the field of pathology helping the pathologist to make more accurate and definitive diagnosis in coming future.

Financial support and sponsorship: Nil.

Conflicts of support: There are no conflicts of interest.

REFERENCES

- Basavanthally AN., Ganesan S., Agner S., Monaco JP., Feldman MD., Tomaszewski JE., Bhanot G., Madabhushi A. 2010. Computerized image-based detection and grading of lymphocytic infiltration in HER2+ breast cancer histopathology. *IEEE Trans Biomed Eng.* Mar; 2010 57(3):642–653. [PubMed: 19884074]
- Belkacem-Boussaid K., Pennell M., Lozanski G., Shana'ah A., Gurcan M. 2010. Computer-aided classification of centroblast cells in follicular lymphoma. *Anal Quant CytolHistol.* Oct; 32(5):254–260. [PubMed: 21509147]
- Bhargava R, Madabhushi A. A review of emerging themes in image informatics and molecular analysis for digital pathology. *Annu Rev Biomed Eng* 2016;18.
- Caldwell ML., Moffitt RA., Liu J., Parry RM., Sharma Y., Wang MD. 2008. Simple quantification of multiplexed quantum dot staining in clinical tissue samples. *Proc IEEE Conf Eng Med Biol Soc.*, 2008:1907–1910
- Chandra M. 2014. Digital pathology slides in medical education. *Indian J Dermatopathol Diagn Dermatol.*, 1:17-20
- Chandra M. Virtual microscopy- Technology of new millennium. *J Odontol Res* 2013; 1:1-3.
- Cooper L., Sertel O., Kong J., Lozanski G., Huang K., Gurcan M. 2009. Feature-based registration of histopathology images with different stains: An application for computerized follicular lymphoma prognosis. *Comput Methods Programs Biomed.* Dec; 96(3):182–192. [PubMed: 19487043]
- Cooper LA., Carter AB., Farris AB., Wang F., Kong J., Gutman DA., Widener P., Pan TC., Cholleti SR., Sharma A., Kurc TM. 2012. Digital pathology: Data-intensive frontier in medical imaging. *Proceedings of the IEEE.* Apr;100(4):991-1003.
- Evans AJ., Chetty R., Clarke BA., Croul S., Ghazarian DM., Kiehl TR., et al. 2009. Primary frozen section diagnosis by robotic microscopy and virtual slide telepathology: The University Health Network experience. *Hum Pathol.*, 40:1070-81
- Fonseca FP., Santos-Silva AR., Lopes MA., de Almeida OP., Vargas PA. 2015. Transition from glass to digital slide microscopy in the teaching of oral pathology in a Brazilian dental school. *Medicina oral, patologia oral y cirugiabucal.* Jan;20(1): e17.
- Ghaznavi F, Evans A, Madabhushi A, Feldman M. 2013. Digital imaging in pathology: Whole-slide imaging and beyond. *Ann Rev Pathol Mech Dis.*, 8:331-59.
- Indu M., Rathy R., Binu MP. 2016. "Slide less pathology": Fairy tale or reality? *Journal of oral and maxillofacial pathology: JOMFP.* May;20(2):284.
- Janowczyk A., Madabhushi A. 2016. Deep learning for digital pathology image analysis: A comprehensive tutorial with selected use cases. *Journal of pathology informatics.*, 7.
- Karnovsky MJ. 2006. A pathologist's odyssey. *Annu Rev Pathol.*, 1:1–22. [PubMed: 18039106]
- Khushi M, Edwards G, de Marcos DA, Carpenter JE, Graham JD, Clarke CL. Open source tools for management and archiving of digital microscopy data to allow integration with patient pathology and treatment information. *Diagn Pathol* 2013; 8:22
- Kong J., Sertel O., Boyer KL., Saltz JH., Gurcan MN. 2008. A multi-resolution image analysis system for computer-assisted grading of neuroblastoma differentiation. *Proc SPIE.* 6915:69151T.
- Krenacs T., Zsakovics I., Micsik T., Fonyad L., Varga, SV., Ficsor L. 2010. Digital microscopy – The upcoming revolution in histopathology teaching, diagnostics, research and quality assurance. In: Vilas M, Diaz J, editors. *Microscopy: Science, Technology, Applications and Education.* Badajoz: *Formatex Research Center.* p. 965-77

- Krishnamurthy S, Mathews K, McClure S, Murray M, Gilcrease M, Albarracin C, Spinosa J, Chang B, Ho J, Holt J, Cohen A. 2013. Multi-institutional comparison of whole slide digital imaging and optical microscopy for interpretation of hematoxylin-eosin-stained breast tissue sections. *Archives of Pathology and Laboratory Medicine*, 15;137(12):1733-9
- Levenson RM., Fornari A., Loda M. 2008. Multispectral imaging and pathology: Seeing and doing more. *Expert Opin Med Diagn.*, 2:1067-81.
- Madabhushi A., Agner S., Basavanahally A., Doyle S., Lee G. 2011. Computer-aided prognosis: Predicting patient and disease outcome via quantitative fusion of multi-scale, multi-modal data. *Comput Med Imaging Graphics.*; 35(7-8):506-514
- Masood K., Rajpoot N. 2009. Texture based classification of hyperspectral colon biopsy samples using CBLP. Proc ISBI. Jun-Jul:1011-1014.10.1109/ISBI.2009.5193226
- Montalto MC., McKay RR., Filkins RJ.2011. Autofocus methods of whole slide imaging systems and the introduction of a second-generation independent dual sensor scanning method. *J Pathol Inform.*, 2:44.
- Mukhopadhyay S., Feldman MD., Abels E., Ashfaq R., Beltaifa S., Cacciabeve NG., Cathro HP., Cheng L., Cooper K., Dickey GE., Gill RM. 2018. Whole slide imaging versus microscopy for primary diagnosis in surgical pathology: A Multicenter blinded randomized noninferiority study of 1992 cases (Pivotal study). *The American journal of surgical pathology*. Jan;42(1):39.
- Nishat R., Ramachandra S., Behura SS., Kumar H. 2017. Digital cytopathology. *Journal of oral and maxillofacial pathology: JOMFP*. Jan;21(1):99.
- Pantanowitz L, Szymas J, Yagi Y, Wilbur D. Whole slide imaging for educational purposes. *J Pathol Inform* 2012; 3:46.
- Pantanowitz L. 2010. Digital images and the future of digital pathology. *J Pathol Inform.*, 1:15
- Pantanowitz L., Sinard JH., Henricks WH., Fatheree LA., Carter AB., Contis L. *et al.*, 2013. Validating whole slide imaging for diagnostic purposes in pathology: Guideline from the College of American Pathologists Pathology and Laboratory Quality Center. *Arch Pathol Lab Med.*, 137:1710-22
- Parwani AV., Feldman M., Balis U., Pantanowitz L. 2012. Digital imaging. In:Pantanowitz L, Balis UJ, Tuthill JM, editors. *Pathology Informatics: Theory and Practice*. Canada: ASCP Press; p. 231-56.
- Pekmezci M, Uysal SP, Orhan Y, Tihan T, Lee HS. 2016. Pitfalls in the use of whole slide imaging for the diagnosis of central nervous system tumors: A pilot study in surgical neuropathology. *Journal of pathology informatics*.7.
- Pinco J., Goulart RA., Otis CN., Garb J., Pantanowitz L. 2009. Impact of digital image manipulation in cytology. *Arch Pathol Lab Med.*, 133:57-61.
- Ruifrok AC., Katz RL., Johnston DA. 2003. Comparison of quantification of histochemical staining by hue-saturation-intensity (HSI) transformation and color-deconvolution. *Appl Immunohistochem Mol Morphol*. Mar; 11(1):85-91. [PubMed: 12610362]
- Saco A, Bombi JA, Garcia A, Ramirez J, Ordi J. Current status of whole-slide imaging in education. *Pathobiology*. 2016;83(2-3):79-88.
- Sertel O., Lozanski G., Shana'ah A., Gurcan MN.2010. Computer-aided detection of centroblasts for follicular lymphoma grading using adaptive likelihood-based cell segmentation. *IEEE Trans Biomed Eng*. Oct; 2010 57(10):2613-2616. [PubMed: 20595077]
- Tholouli E., Sweeney E., Barrow E., Clay V., Hoyland JA., Byers RJ. 2008. Quantum dots light up pathology. *J Pathol*. Nov216(3):275-285. [PubMed: 18814189]
- Van De Wouwer G., Weyn B., Scheunders P., Jacob W., Van Marck E., Van Dyck D. 2000. Wavelets as chromatin texture descriptors for the automated identification of neoplastic nuclei. *J Microscopy.*, 197(1):25-35
