



RESEARCH ARTICLE

ROOT CANAL OBTURATION- AN IMPORTANT TOOL FOR FORENSIC IDENTIFICATION

¹Dr. Younis Pervez SK., ²Dr. Kalyan Satish R., ³Dr. Sreenivasa Bharath, T., ⁴Dr. Girija. S. Sajjan,
⁵Dr. Madhu Varma K. and ⁶Dr. Madhuri S.S.

¹Post graduate student, Dept. of Conservative Dentistry and Endodontics, Vishnu Dental College, Bhimavaram, Andhra Pradesh

²Professor, Dept. of Conservative Dentistry and Endodontics, Vishnu Dental College, Bhimavaram, Andhra Pradesh

³Reader, Dept. of Oral Pathology, Vishnu Dental College, Bhimavaram, Andhra Pradesh

⁴Professor and Head, Dept. of Conservative Dentistry and Endodontics, Vishnu Dental College, Bhimavaram, Andhra Pradesh

⁵Professor, Dept. of Conservative Dentistry and Endodontics, Vishnu Dental College, Bhimavaram, Andhra Pradesh

⁶Post graduate student, Dept. of Conservative Dentistry and Endodontics, Vishnu Dental College, Bhimavaram, Andhra Pradesh

ARTICLE INFO

Correspondence: younis@vishnudentalcollege.com

Article History:

Received 20th January, 2019

Received in revised form

26th February, 2019

Accepted 24th March, 2019

Published online 30th April, 2019

Key Words:

Root Canal Treatment,
Identification, Forensic Dentistry.

*Corresponding author:

Copyright©2019, Younis Pervez et al. This is an open access article distributed under the Creative Commons Attribution License, which permits unrestricted use, distribution, and reproduction in any medium, provided the original work is properly cited.

Citation: Dr. Younis Pervez SK., Dr. Kalyan Satish R., Dr. Sreenivasa Bharath, T., Dr. Girija. S. Sajjan, Dr. Madhu Varma K. and Dr. Madhuri, S.S. 2019. "Root canal obturation- an important tool for forensic identification", *International Journal of Current Research*, 11, (04), 3417-3420.

INTRODUCTION

In Forensic Sciences the process of Deceased Victim Identification involves a range of forensic science techniques to make a positive identification of the deceased victims. Some of these are Fingerprints, Odontology, DNA profiling (Forrest 2010). Although DNA matching is a revolutionary and accurate method of connecting an identity to human remains, the configuration of an individual's teeth is still the most common and cost effective method of identification. Any forensic expert will first look at accessing dental records and matching them before exploring other avenues. Digital dental radiography is becoming very popular and this permits images of xraysto be stored in computers. This is allowing authorities to develop a database, similar to the type used for fingerprints that may be extremely valuable in the future.

Dental Comparison is one of the main method used for the identification of large number of victims in cases of mass disaster. Forensic dentistry plays a basic role in the identification of individuals who cannot be identified by routine methods (Pretty 2001). Forensic dental identification depends mainly on the recognition of common consistent features by comparison of ante-mortem and post-mortem dental records with no incompatible differences demonstrated between the two sets of records (Keiser-Nielsen 1980). The radiographic images captured from a patient can be duplicated precisely in the future and the process of duplication is non-operator specific. With this background radiographic imaging became an extremely significant role in the comparison process in personal forensic identification. The vital role of Forensic Odontology in identification is based on the unique

characteristics and arrangements of the teeth of different individuals (Krishan 2015). Dental radiology has played a key role in the identification of victims in many cases. The identification of 73% of the 35 burned victims in Hotel Hafnia, Denmark was achieved by eight dental surgeons forming part of the identification team (Khalid 2016). The identification of American victims of Operation Desert Storm was largely dependent on forensic dental radiology. 244 out of the 251 victims were identified based on the availability of dental records (Kessler 1993). Dental records were most likely the primary source of identification after the 9/11 attacks in New York in 2001. If families had provided dental records and other personal information, it would have made it much simpler for investigators to narrow down whom they may belong to (Ritter 2007). Post-operative endodontic radiographs provide a rich source of information that may be a unique identifying feature for a particular tooth and individual. This is because of the rare frequency of variation between the radiographic appearance of an endodontic filling compared to that of an intra-coronal restoration (Khalid 2016). The aim of this study was to investigate whether endodontic obturation radiographs have a potential aid for forensic identification.

MATERIALS AND METHODS

This was a cross-sectional hospital-based study conducted in the dental hospital of the Vishnu dental college, in Bhimavaram. This research was approved by the Research and Ethics Committee, Vishnu dental college, Bhimavaram. Thirty periapical radiographs of patients having endodontic treatment of mandibular left first molars with three canals were selected randomly from the data bank of the digital Xray system of Department of Conservative Dentistry and Endodontics of Vishnu Dental College, Bhimavaram. The post-operative radiographs were printed, the crown area was cut from the radiographs, labelled from (1 – 30) and considered as an ante-mortem data “Set 1” (Figure 1). Ten radiographs from the thirty were reprinted, labelled from (A-J) and considered as a post-mortem data “Set 2” (Figure 2). This post-mortem group of 10 radiographs “Set 2” was compared with the ante-mortem group of 30 radiographs comprising “Set 1”. The examiners who were blinded to the study included 40 specialist and 40 general dentist from Vishnu dental college. Their success rates of comparing and matching the radiographic images was recorded.

RESULTS

73 examiners achieved a success rate of 100%, 3 examiners achieved a success rate of 90% (1 mismatch), 2 examiners achieved a success rate of 80% (2 mismatch) and 2 examiners achieved a success rate of 70% (3 mismatch) (Bar chart). According to Kolmogorov-Smirnov and Shapiro-Wilk, data is not in normal distribution. So, non parametric test were considered for Statistical Analysis. Mannwhitney test was performed using SPSS software version 22 and there is significant difference between two groups (Table 1). P value is 0.006.

DISCUSSION

It is common practice that, during forensic comparison between radiographic images, the similarities of the features that are common in both images are compared.

In the seaquake in South-East Asia in December 2004, more than 92% of the non-Thai victims have been identified. About 80% of the non-Thai victims were identified by dental information. This high success rate of dental identification in Thailand was a matter of surprise for many forensic experts (Schuller-Götzburg 2007). The relatively recent trend for aesthetic dentistry has resulted in the introduction of tooth-coloured composite materials to replace amalgam. This has opened up a new area of research regarding the radiographic assessment of composite materials for purposes of identification. Nonetheless if it can be demonstrated that both the ante and post-mortem radiographs of a single composite restoration in the same tooth show the same morphology, this uniqueness can be used for purposes of identification (Zondag 2009; Hemasathya 2013). Bonavilla et al conducted a study to evaluate which endodontic obturation materials were capable of withstanding high temperatures such as those to which an incinerated victim would have been exposed. This information was used to compile a database regarding the use of root canal filling materials as an aid in forensic identification (Bonavilla 2008). Savio C. et al carried out a study to evaluate the radiographic appearance of unrestored teeth, restored teeth and endodontic ally treated teeth after exposure to different ranges of high temperatures. The outcome showed significant retention of radiographic appearance and features of endodontic treatment were recognizable up until 1100 C (Savio 2006).

Many other studies have also highlighted the importance of radiography in human identification, for example, comparison of obturated single root canals, comparison of trabecular bone patterns, comparison of the morphology of the frontal sinus and comparison of the bones of the maxilla (Eastman 1982; Harris 1987). This study demonstrated that 73 out of the 80 dentally trained examiners were able to match the 10 radiographic images of obturated multi-rooted canals from “Set 1” and “Set 2” of the same tooth. This group of 73 represented 91 % of the total sample size of examiners who participated in the study. This indicates that characteristics of the radiographic images of similar multi rooted teeth can be discriminated using unique obturation morphology and can be used as a tool for purpose of identification. Based on the category of the observers, the percentage of maximum identification among Specialists was the highest (100 %), followed by General Dentist (82%). This shows that there is statistical significance difference between Specialist and General Dentist. This might be due to more knowledge, skill and experience of specialist than general dentist in interpretation of radiographs. In real life, if examiner feels that the post mortem obturation radiographs has some close resemblance with the ante mortem radiograph, then he must take multiple radiographs in different positions, so as to compare the ante mortem radiographs stored in the data bank of digital x ray system with post mortem radiographs. So, every clinician must develop a habit of storing data of radiographic images which can be used for future needs for forensic identification if necessity comes. The results of this study demonstrate that the morphology of an obturated multi rooted teeth is easily identifiable by comparison of ante and post-mortem radiographs which is in accordance with the previous study of obturated single rooted tooth for forensic identification by comparing ante and post-mortem radiographs. Obturation of multi-rooted teeth using gutta-percha creates a unique pattern that can be easily recognised using radiographs.

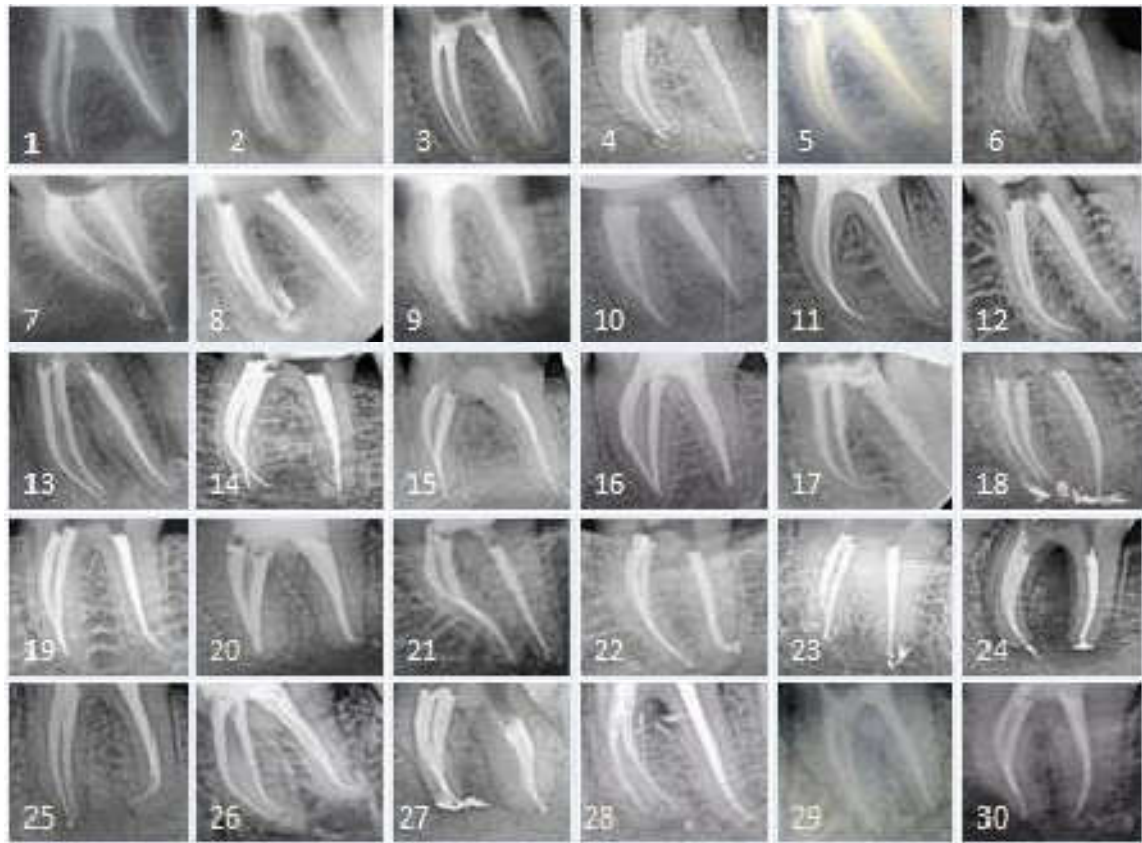


Figure 1. SET 1; Radiographs represent ante-mortem labelled from (1-30)

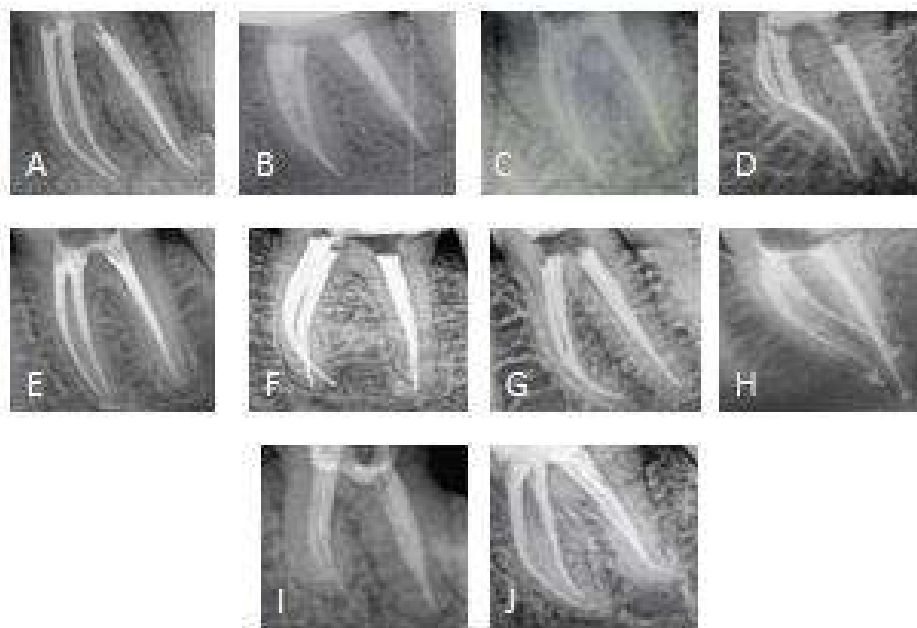
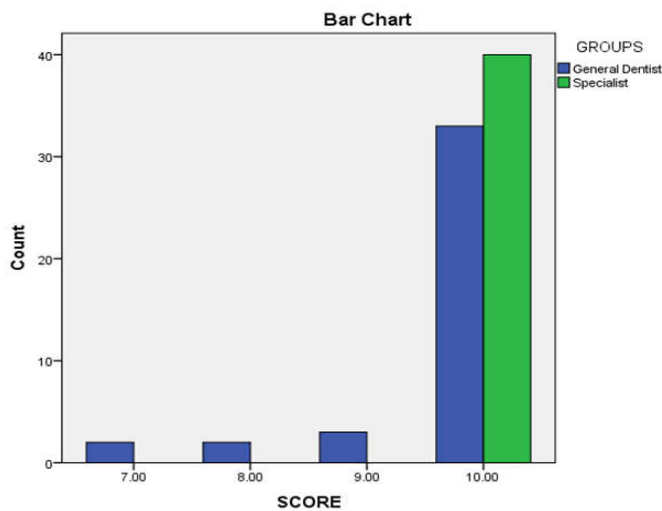


Figure 2. SET 2; Radiographs represent post-mortem labelled from (A-J)

Table 1. Showing significant difference between two groups

	GROUPS	N	Mean Rank	Sum of Ranks
SCORE	General Dentist	40	37.00	1480.00
	Specialist	40	44.00	1760.00
	Total	80		

P Value IS 0.06



Bar chart showing comparison between General Dentist and Specialist

This study also suggests that it is highly unlikely for two obturated multi-rooted teeth to have exactly the same radiographic appearance.

Conclusion

The radiographic images of the obturated canals of multi-rooted teeth in this study were shown to have highly specific morphological features that could act as a potential aid for purposes of identification. Every clinician must develop a habit of storing data of radiographic images which can be used for future needs for forensic identification if necessity comes. The potential feature of the unique morphology of the obturated canal of a multi-rooted tooth could be used for evidence-based decision making in Forensic Dentistry.

REFERENCES

- Forrest, A. S. and Wu, H. Y. H. 2010. Endodontic imaging as an aid to forensic personal identification. *Australian Endodontic Journal*, 36(2): 87-94.
- Pretty, I. A. and Sweet, D. 2001. forensic dentistry: A look at forensic dentistry–Part 1: The role of teeth in the determination of human identity. *British dental journal*, 190(7): 359.
- Keiser-Nielsen, S. 1980. Bristol: John Wright and Sons. The final report. *Person Identification by Means of their Teeth*, 54-72.
- Krishan, K., Kanchan, T. and Garg, A. K. 2015. Dental evidence in forensic identification–An overview, methodology and present status. *The open dentistry journal*, 9: 250.
- Khalid, K., Yousif, S. and Satti, A. 2016. Discrimination potential of root canal treated tooth in forensic dentistry. *Journal of Forensic Odonto-Stomatology*, 34(1): 19-26.
- Kessler, H. P. and Pembie III, C. W. 1993. Forensic dental identification of casualties during Operation Desert Storm. *Military medicine*, 158(6), 359-362.
- Ritter, N. 2007. Missing persons and unidentified remains: the nation's silent mass disaster. *niJ Journal*, 256(7).
- Schuller-Götzburg, P., & Suchanek, J. 2007. Forensic odontologists successfully identify tsunami victims in Phuket, Thailand. *Forensic Science International*, 171(2-3): 204-207.
- Zondag, H. and Phillips, V. M. 2009. The discrimination potential of radio opaque composite restorations for identification: Part 3. *J Forensic Odontostomatol*, 27(1): 27-32.
- Hemasathya, B. A., & Balagopal, S. 2013. A study of composite restorations as a tool in forensic identification. *Journal of forensic dental sciences*, 5(1): 35.
- Bonavilla, J. D., Bush, M. A., Bush, P. J. and Pantera, E. A. 2008. Identification of incinerated root canal filling materials after exposure to high heat incineration. *Journal of forensic sciences*, 53(2): 412-418.
- Savio, C., Merlati, G., Danesino, P., Fassina, G. and Menghini, P. 2006. Radiographic evaluation of teeth subjected to high temperatures: Experimental study to aid identification processes. *Forensic Science International*, 158(2-3): 108-116.
- Eastman, J. R., Raibley, S. and Schwartz, L. 1982. Trabecular bone patterns in dental radiographs: a further aid to dentists involved in forensic dentistry. *Illinois dental journal*, 51(3): 161-163.
- Harris, A. M. P., Wood, R. E., Nortje, C. J. and Thomas, C. J. 1987. The frontal sinus: Forensic fingerprint?-A pilot study. *J Forensic Odontostomatol.*, 5: 9-15.
