



RESEARCH ARTICLE

CLINICAL EVALUATION OF CLASS II AND CLASS III GINGIVAL RECESSION DEFECTS OF MAXILLARY POSTERIOR TEETH TREATED WITH PEDICLED BUCCAL PAD OF FAT

¹Dr. Syed Saima, ²Dr. Gazanfer Ali Shah, ³Dr. Suhail Majid Jan and ⁴Dr. Roobal Behal

¹Lecturer, Dept of Periodontics, Government Dental College and Hospital, Srinagar

²Postgraduate Scholar, Department of Periodontics, Government Dental College and Hospital, Srinagar

³Prof and Head Of Department, Department of Periodontics, Government Dental College and Hospital, Srinagar

⁴Associate Professor, Department of Periodontics, Government Dental College and Hospital, Srinagar

ARTICLE INFO

Gingival Recession Length (GRL) - the vertical from

Article History:

Received 20th February, 2019

Received in revised form

24th March, 2019

Accepted 30th April, 2019

Published online 30th May, 2019

Key Words:

Adipose, stem cell, fat pad, gingival recession, Miller's Class II, III recession.

*Corresponding author:

Copyright © 2019, Syed Saima et al. This is an open access article distributed under the Creative Commons Attribution License, which permits unrestricted use, distribution, and reproduction in any medium, provided the original work is properly cited.

Citation: Dr. Syed Saima, Dr. Gazanfer Ali Shah, Dr. Suhail Majid Jan and Dr. Roobal Behal, 2019. "Clinical evaluation of Class II and Class III gingival recession defects of maxillary posterior teeth treated with pedicled buccal pad of fat.", *International Journal of Current Research*, 11, (05), 3676-3679.

ABSTRACT

Background: Buccal fat pad (BFP) is a specialized vascular tissue adequately present in buccal space and is close to the maxillary posterior quadrant. The aim of this clinical study was to evaluate the utility of pedicled BFP (PBFP) in the treatment of Class II and III gingival recession. **Materials and Methods:** Ten systemically healthy patients with age ranging from 35 to 55 years with Class II and Class III gingival recession in the maxillary molars were selected. Before the surgical phase, patients were enrolled in a strict maintenance program including oral hygiene instructions and scaling and root planing. A horizontal incision of 1–1.5 cm was made in the buccal sulcus of the maxillary molar region; buccinator muscle was separated bluntly to expose the BFP. The fat was then teased out from its bed and spread to cover defects adequately. It was then secured and sutured without tension. Clinical parameters such as probing depth, recession length, and width of keratinized gingiva were recorded at baseline and at 6 months postoperatively, and weekly assessment was done at 1 week, 2 weeks, 3 weeks, and after 4 weeks for observations during the postoperative healing. **Results:** Treated recession defects healed successfully without any significant postoperative complications. Decreased gingival recession length from baseline to six months. values were statistically significant ($P < 0.05$). Percentage of root coverage average was 85%. There was a statistically significant decrease in length of recession. **Conclusion:** Pedicled buccal fat showed promising results as the treatment modality in the management of Class II and Class III gingival recession of maxillary posterior teeth.

INTRODUCTION

Gingival recession is defined as the displacement of the gingival margin apical to the Cement-enamel junction. It indicates the loss of periodontal connective tissue fibers along with root cementum and alveolar bone. Primary causes of recession are periodontal disease and improper oral hygiene practice¹ leading to dental hypersensitivity and affect esthetics when anterior teeth are involved. Treatment of gingival recession aims to cover the exposed root surface and to arrest the progression of tissue loss. Various periodontal plastic procedures have been used including pedicle flaps and free gingival grafts. It has been demonstrated that recessions treated with pedicle flaps heal with a long junctional epithelium between the root surface and the covering tissue in animals and in humans (Wilderman, 1965; Pfeifer, 1971). Only a limited amount of regeneration has been observed in varying degrees in the most apical portion of the exposed root surface. Mucogingival surgery can therefore result in satisfactory root coverage without significant enhancement of the attachment apparatus (Sugarman, 1969).

All of these procedures resulted in an increase in the amount of keratinized tissue, with appreciable results in terms of root coverage ranging from 56% to 98% (Pini Prato, 1992). Guided tissue regeneration has also shown good results in the treatment of buccal recessions. Procedures for the treatment of severe gingival recession of posterior teeth are limited. Egyedi first reported the use of buccal fat pad (BFP) in the closure of oro-antral/nasal communications. BFP is also used in the defects resulting from traumatic or malignant tumors in oral soft tissue (Egyedi, 1977). The BFP has also been used to reconstruct defects in the hard palate, soft palate (up to midline), the retromolar trigone, the buccal mucosa, the anterior tonsillar pillar, the superior alveolar ridge (up to the canine region), and the superior buccal sulcus (Egyedi, ?). It could be used alone or in combination with other flaps such as the pedicled temporalis muscle myocutaneous flap or the pectoralis major myocutaneous flap, where the posterior portion of the defects (palatal region and tonsillar pillar) was reconstructed by the BFP, leaving the anterior and inferior portion to be covered by myocutaneous flaps (Samman, 1993).

The buccal space is bounded anterolaterally by muscles of facial expression and superficial layer of deep cervical fascia, medially by buccinator muscle, posteriorly by masseter and parotid gland, and no definite true superior or inferior boundaries. The buccal fat fills the space largely and has four projections (buccal, temporal, pterygoid, and pterygopalatine) arising from a central body. The central body and buccal extension constitute 50% of total volume and are commonly used for intraoral reconstruction (Alkan, 2003). Other contents of buccal space are facial and buccal arteries, facial vein, parotid duct, minor salivary glands and accessory parotid lobules, lymphatic channels, and branches of facial and mandibular nerves (Kim, 2005). Buccal fat is a specially organized fat tissue also called syssarcosis, a fat that enhances intermuscular motion (muscles of mastication). It is not subjected to lipid metabolism unlike subcutaneous fat where it has a different rhythm of lipolysis (Colella *et al.*, 2008). The anatomical region is consistent, and surgery has no influence on either its appearance or function. Excellent blood supply provided by the rich plexus of blood vessels, proximity between the donor and recipient site, simplicity, and its ease to mobilize, stabilize/adapt, and suture along with its strong anti-infective and keratinizing properties makes it a suitable choice for oral reconstructions and root coverage procedure in the region of maxillary posterior teeth (El Haddad *et al.*, 2008). Hence, the aim of the present study was to clinically evaluate the effect of pedicled BFP (PBFP) in the treatment of Class II and Class III gingival recession defects of maxillary posterior teeth.

MATERIALS AND METHODS

Twelve (12) patients including 6 males and 6 females in the age range of 30–50 years with Class II and Class III gingival recession in the maxillary molars were selected from the Outpatient Department of Periodontology, Govt Dental College and Hospital, Srinagar. Ethical committee clearance was obtained from the Institutional Ethical Committee board. Systemically healthy patients with gingival recession on the buccal side of maxillary first molar or second molar measuring about 3 to 5 mm and above were selected. Inclusion criteria further considered were vital tooth, teeth without caries, or restorations. Exclusion criteria included patients with poor oral hygiene, tobacco users, pregnant and lactating patients, and patients on steroid therapy. Surgical procedure was explained to the patients, and informed consent form was duly signed by the patients. They were educated and motivated about the oral hygiene maintenance and reinforced the need to report to the re-call visits to assess the progress of healing and also to record if any postoperative complications occurred. Clinical parameters recorded during the course of the study were changes in recession from occlusal stent, width of keratinized gingiva (KGW), and percentage of root coverage. UNC-15 Probe was used to measure the readings and was recorded at baseline and at six months. All patients received oral hygiene instructions and Phase I therapy including scaling and root planing before surgery.

Surgical procedure: Nerve blocks and infiltration along the proposed incision were achieved with lignocaine hydrochloride 2% with adrenaline (1:100,000). Crevicular incision was made and a full-thickness mucoperiosteal flap was raised. A horizontal incision of 1–1.5 cm was made in the mucobuccal fold in relation to the maxillary first molar region and extended backward.

Buccinator muscle was separated bluntly to expose the buccal BFP. The fat was teased out from its bed; the anterior portion was gently grasped and spread onto the defect site to cover adequately. It was then secured and sutured without tension using resorbable sutures. Excessive stretching of the flap is avoided as it invariably impairs the vascularity. Care was taken not to tear the capsule to enable easy handling of the BFP tissue. It is suggested that the fat pad is applied adequately or little excess to cover the entire surgical defect to compensate for postoperative shrinkage during healing. Postoperative instructions included the prescription of the antibiotic amoxicillin 500 mg three times a day for 5 days and ibuprofen 600 mg three times a day for 5 days, soft semisolid to liquid diet, and brushing other areas except the operated site for 1 week. Chlorhexidine mouth rinses twice daily were advised. The epithelialization was evident from periphery onto the surface of BFP in 2–4 weeks and completed in 4–6 weeks and Surface was smooth, pink, and developed an appearance similar to normal tissues. Patients were followed up at 1 week, 2 weeks, 3 weeks, and 4 weeks for the assessment of postoperative healing.

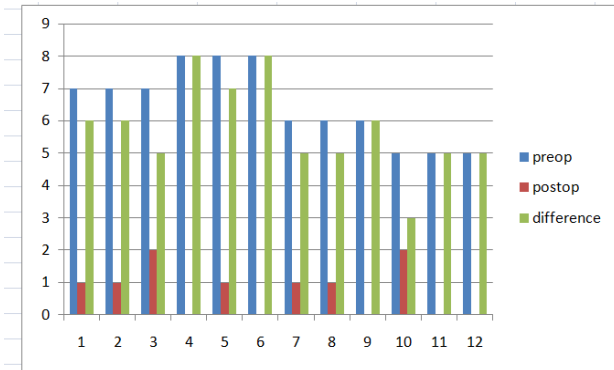
Histologic evaluation of post buccal fat placement over recession area: The histological nature of the healing process of the BFP was first reported by Samman *et al.*⁸ He observed that there was a complete absence of the fat cells in sections taken from healed sites, indicating fibrosis of the fat tissue, and the reconstructed area was covered by parakeratotic stratified squamous epithelium. Fat cells of BFP were replaced by collagen fibers slowly over time until all fat cells had disappeared. However, the mechanism by which the fat tissue is replaced is still not clear and needs further investigation. Processed lipoaspirate (PLA) cells could be isolated from the adipose tissue in significant numbers and exhibit stable growth and proliferation kinetics in culture. PLA cells, such as mesenchymal stem cells (MSCs), differentiate *in vitro* toward the osteogenic, adipogenic, myogenic, and chondrogenic lineages when treated with established lineage-specific factors.¹³ This further led to the conclusion that a population of multipotent stem cells comparable with mesenchymal stem cells could be isolated from human adipose tissue (Zuk, 2002). Pyo *et al.* showed the differentiation of adult stem cell derived from BFP into osteoblast, which confirms the presence of stem cells within the BFP that can aid in periodontal regeneration (Pyo *et al.*, 2006).

DISCUSSION

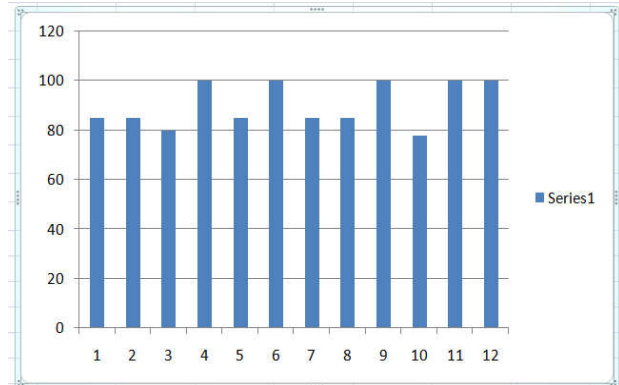
The present study aimed to evaluate the application of PBFP in the treatment of gingival recession defects. A total of twelve patients were treated with BFP in Class II and Class III gingival recession defects of maxillary first and second molars. The periodontal parameters at baseline together with the 6-month outcomes are summarized in Table 1. Among the 12 defects treated, two were second molars and eight were first molars and four Class II and six Class III defects. All patients completed the study and attended all the recall visits. Postoperative healing was uneventful. Supragingival plaque control was maintained throughout the study period, and if required, oral prophylaxis was performed. There was a statistically significant decrease in the gingival recession length, KGW ($P < 0.05$) from baseline to 6 months. In our cases, we observed the epithelialization of the BFP within the 2nd week with complete epithelialization in 4–6 weeks. There was not much difference in the healing pattern with either BFP

Table 1. Measurement of clinical parameters

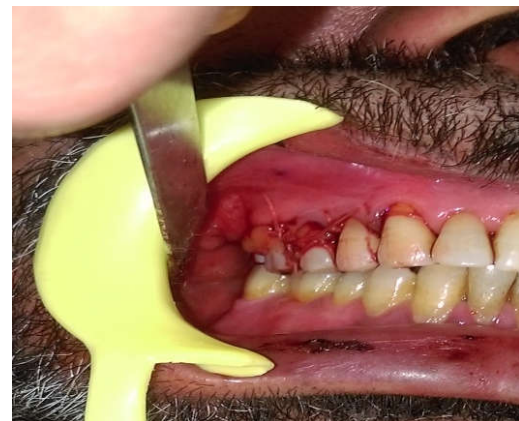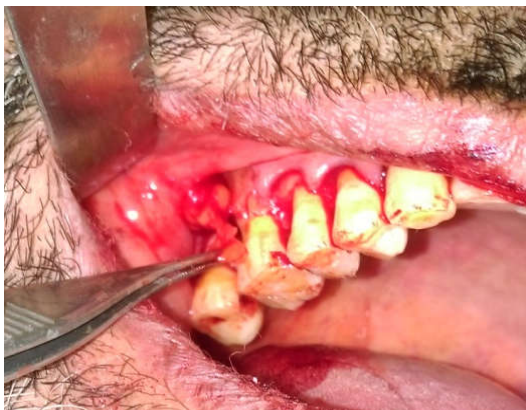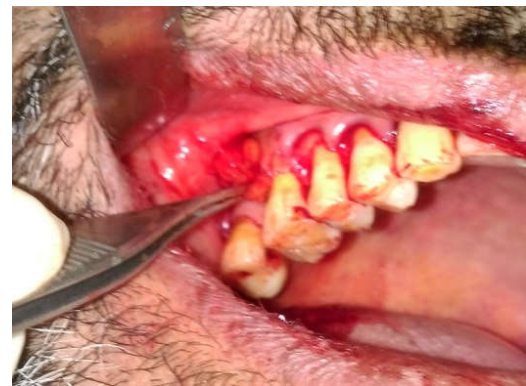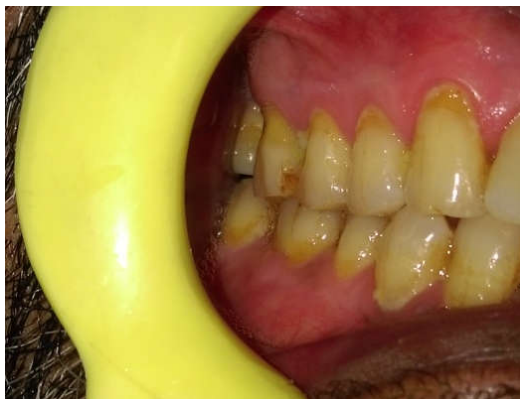Case No.	Gingival recession length Pre operative	Post operative	% of root coverage	Gain in the width of keratinized gingiva
1	7	01	85	2mm
2	7	01	85	2mm
3	7	02	80	1mm
4	8	00	100	2mm
5	8	01	85	1mm
6	8	00	100	2mm
7	6	01	85	1mm
8	6	01	85	1mm
9	6	00	100	2mm
10	5	02	78	2mm
11	5	00	100	2mm
12	5	00	100	2mm



Gingival recession length in mm



Percentage root coverage



capsule intact or in patients with tear in capsule. However, the BFP easily slipped while suturing when the capsule was broken. The histological nature of the healing process of the BFP was first reported by Samman *et al.* (1993) He observed that there was a complete absence of the fat cells in sections taken from healed sites, indicating fibrosis of the fat. Tissue, and the reconstructed area was covered by parakeratotic stratified squamous epithelium.

Fat cells of BFP were replaced by collagen fibers slowly over time until all fat cells had disappeared. However, the mechanism by which the fat tissue is replaced is still not clear and needs further investigation. Furthermore, vital role played by the adipose-derived fat cells in differentiation and regeneration needs elaboration. Stem cells are considered to be the cells possessing self-replicating potential and the ability to

give rise to terminally differentiated cells of multiple lineages (Zuk et al., 2001). Adipose tissue, such as bone marrow, is derived from the mesenchyme and contains a supportive stroma that is easily isolated. Based on this, adipose tissue may represent a source of stem cells that could have far-reaching applications. Processed lipoaspirate (PLA) cells could be isolated from the adipose tissue in significant numbers and exhibit stable growth and proliferation kinetics in culture. PLA cells, such as mesenchymal stem cells (MSCs), differentiate *in vitro* toward the osteogenic, adipogenic, myogenic, and chondrogenic lineages when treated with established lineage-specific factors (Zuk, 2002). This further led to the conclusion that a population of multipotent stem cells comparable with mesenchymal stem cells could be isolated from human adipose tissue (Pyo, 2006) Pyo et al. showed the differentiation of adult stem cell derived from BFP into osteoblast, which confirms the presence of stem cells within the BFP that can aid in periodontal regeneration. Advantages of using BFP are that it is a quick, simple, and easy flap to use, heals with minimal scarring, negligible morbidity, and failure rate is very low. However, reported complications with BFP reconstruction are bleeding, hematoma, partial necrosis, excessive scarring, and infection.

Limitation

PBFP cannot be stretched till the maxillary anterior teeth and neither could be used for mandibular teeth. Future recommendations include (1) histological study of healed tissue to correlate the stability of the achieved results could be considered and (2) larger sample size with longer follow-up period could be considered for meaningful results.

Conclusion

Within the limitations of this study, it can be concluded that the PBFP has proved useful entity in the treatment of severe gingival recession in maxillary posterior teeth. Its major advantage is its anatomical proximity to the maxillary posterior teeth, adequate volume, definite vascularity, and remarkable resistance to infection, thus making PBFP an alternative for severe recession in maxillary posterior teeth.

REFERENCES

Alkan A., Dolanmaz D., Uzun E., Erdem E. 2003. The reconstruction of oral defects with buccal fat pad. *Swiss Med Wkly.*, 133:465-70.

- Colella G., Tartaro G., Giudice A. 2004. The buccal fat pad in oral reconstruction. *Br J Plast Surg.*, 57:326-9.
- Egyedi P. 1977. Utilization of the buccal fat pad for closure of oro-antral and/or oro-nasal communications. *J Maxillofac Surg.*, 5:241-4.
- Egyedi P., Müller H. Buccal fat pad flap plus skin graft to oroantral and oronasal defects. In: Strauch B, Vasconez LO, Hall-Findlay EJ, editors. *Grabb's Encyclopedia of Flaps.*: Little, Brown and Co; New York. p. 403-6.
- El Haddad SA., Abd El Razzak MY., El Shall M. 2008. Use of pedicled buccal fat pad in root coverage of severe gingival recession defect. *J Periodontol.*, 79:1271-9
- Kim HC., Han MH., Moon MH., Kim JH., Kim IO., Chang KH. et al., 2005. CT and MR imaging of the buccal space: Normal anatomy and abnormalities. *Korean J Radiol.*, 6:22-30.
- Löe H., Anerud A., Boysen H. 1992. The natural history of periodontal disease in man: Prevalence, severity, and extent of gingival recession. *J Periodontol.*, 63:489-95.
- Pfeifer JS., Heller R. 1971. Histologic evaluation of full and partial thickness lateral repositioned flaps: A pilot study. *J Periodontol.*, 42:331-3
- Pini Prato G., Tinti C., Vincenzi G., Magnani C., Cortellini P., Clauser C. et al., 1992. Guided tissue regeneration versus mucogingival surgery in the treatment of human buccal gingival recession. *J Periodontol.*, 63:919-28
- Pyo SW., Park JW., Lee IK., Kim CH. 2006. Differentiation of adult stem cell derived from buccal fat pad into osteoblast. *J Korean Assoc Oral Maxillofac Surg.*, 32:524-9.
- Samman N., Cheung LK., Tideman H. 1993. The buccal fat pad in oral reconstruction. *Int J Oral Maxillofac Surg.*, 22:2-6.
- Sugarman EF. 1969. A clinical and histological study of the attachment of grafted tissue to bone and teeth. *J Periodontol.*, 40:381-7
- Wilderman MN., Wentz FM. 1965. Repair of a dentogingival defect with a pedicle flap. *J Periodontol.*, 36:218-31.
- Zuk PA., Zhu M., Ashjian P., De Ugarte DA, Huang JI., Mizuno H. et al. Human adipose tissue is a source of multipotent stem cells. *Mol Biol Cell* 2002;13:4279-95.
- Zuk PA., Zhu M., Mizuno H., Huang J., Futrell JW., Katz AJ., et al., 2001. Multilineage cells from human adipose tissue: Implications for cell-based therapies. *Tissue Eng.*, 7:211-28.
