



ISSN: 0975-833X

Available online at <http://www.journalcra.com>

International Journal of Current Research
Vol. 11, Issue, 08, pp.6256-6259, August, 2019

DOI: <https://doi.org/10.24941/ijcr.36317.08.2019>

INTERNATIONAL JOURNAL
OF CURRENT RESEARCH

RESEARCH ARTICLE

2.5 YR FOLLOW UP STUDY OF POST TRAUMATIC, IPSILATERAL INTERTROCHANTERIC FRACTURE, POSTERIOR DISLOCATION OF HIP WITH FRACTURE OF POSTERIOR WALL AND POSTERIOR COLUMN OF ACETABULUM IN YOUNG ADULT(FLOATING HIP)

***Kuldeep Nahar**

Senior consultant Orthopaedic surgeon, Gujarat research and medical institute, Shahibagh Ahmedabad, Gujarat, India

ARTICLE INFO

Article History:

Received 28th May, 2019
Received in revised form
24th June, 2019
Accepted 19th July, 2019
Published online 31st August, 2019

Key Word:

Ipsilateral , Posterior hip Dislocation
Intertrochanteric Fracture,
Acetabulum Fracture.

*Corresponding author:

Kuldeep Nahar

Copyright © 2019, Kuldeep Nahar. This is an open access article distributed under the Creative Commons Attribution License, which permits unrestricted use, distribution, and reproduction in any medium, provided the original work is properly cited.

Citation: Kuldeep Nahar, 2019. " 2.5 yr follow up study of post traumatic,ipsilateral intertrochanteric fracture,posterior dislocation of hip with fracture of posterior wall and posterior column of acetabulum in young adult(floating hip)", *International Journal of Current Research*, 11, (08), 6256-6259.

ABSTRACT

31 yr old male presents to me for traumatic ipsilateral fracture of trochanteric region with transverse fracture of acetabulum having posterior wall and posterior column fracture alongside posterior dislocation of hip. patient was operated for intertrochanteric fracture first by fixation with dynamic screw plate system on fracture table. simultaneously acetabulum was fixed with plates and screw on simple table in lateral position. patient was followed for 2.5 yrs and doing well in terms of union, range of motion of hip, vascularity of head except some gluteal muscle limp. so proper planning and surgical skill yielded good result.

INTRODUCTION

Posterior dislocation of the hip joint with associated acetabular fracture and intertrochanteric fracture is an uncommon injury. early diagnosis and reduction can prevent complications and bring good results. Final outcome depends upon the time from injury to treatment, type of fracture-dislocation, congruity and stability of the reduction and severity of injury [Skand Sinha, 2013; Sen, 2017]. Posterior hip dislocations occur in axial force transfer through the femur to the hip joint in adduction at hip. There are case reports documenting dislocation of hip with column or wall fractures of acetabulum, with neck or intertrochanteric fracture [Barrett, 2009; Keel, 2010]. The combination of posterior dislocation of hip with trochanteric fracture of femur, with fracture of posterior wall of acetabulum and transverse fracture acetabulum has been reported in literature. I hereby present a case with above combination with no sciatic nerve palsy.

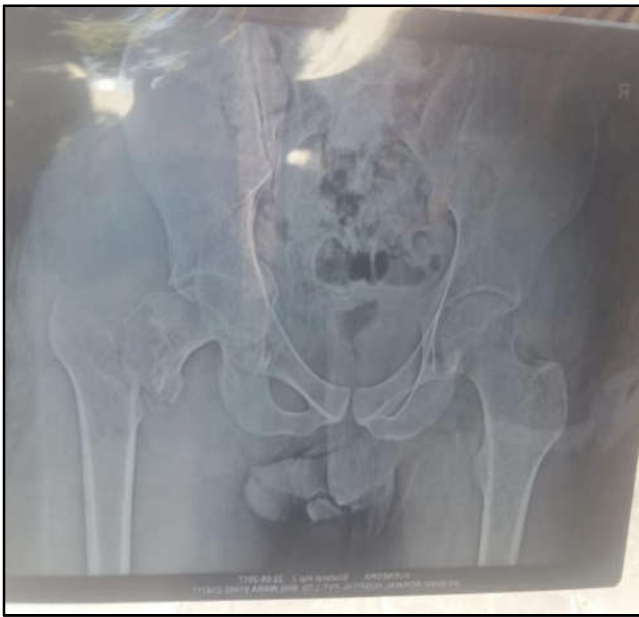MATERIALS AND METHODS

31 year old male presented with history of road traffic accident before 2 days. Pt was referred to us after hemodynamically stabilisation. On examination patient having periorbital oedema in lt eye plus restricted mouth opening.

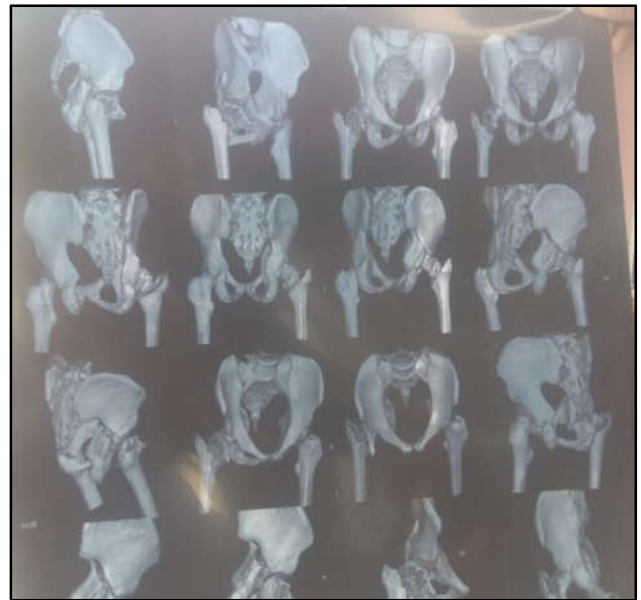Massive oedema around left hip region with restricted motion but no neurological issues. X-ray pelvis showed a intertrochanteric fracture, fracture of posterior wall and column, posteromedial dislocation of hip left side. 3D CT scan was done to confirm the findings. Undisplaced anterior column fracture was additional information on CT. Patient was undertaken for surgery next day. pt was taken in fracture table in supine position. Lateral thigh incision on trochanter was made and by retracting femur laterally, with the help of hip reduction screw the head was pulled out from pelvis and intertrochanteric fracture was fixed with DHS plate and screw. Temporary skin closure was done again pt was shifted on simple table and placed in lateral position. Same incision was extended as K L APPROACH for acetabular fixation. Posterior wall and column was fixed with multiple plates. pt was immobilised for 1 week and then non weight bearing mobilisation for 8 weeks. Partial wt bearing for 6 wks and full wt bearing thereafter. Pt was followed til today having good clinical and radiological outcome.

DISCUSSION

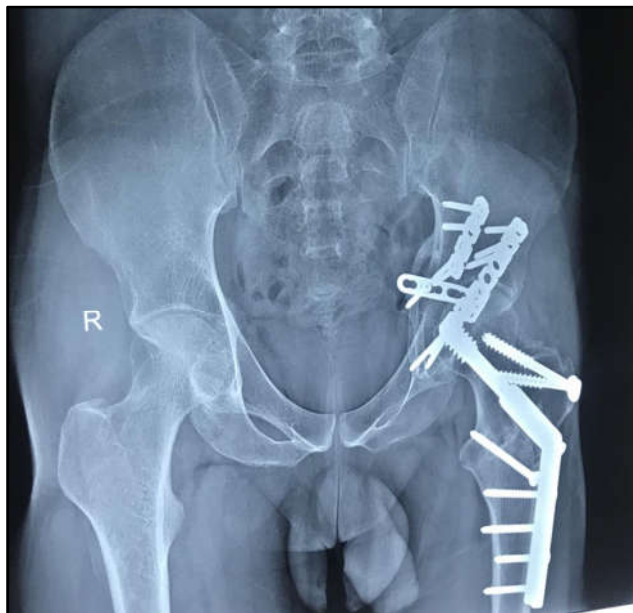
Fractures of the pelvis or acetabulum occurring with a femur fracture constitute the term floating hip (2). These represent a wide spectrum of injury patterns which require surgical intervention.



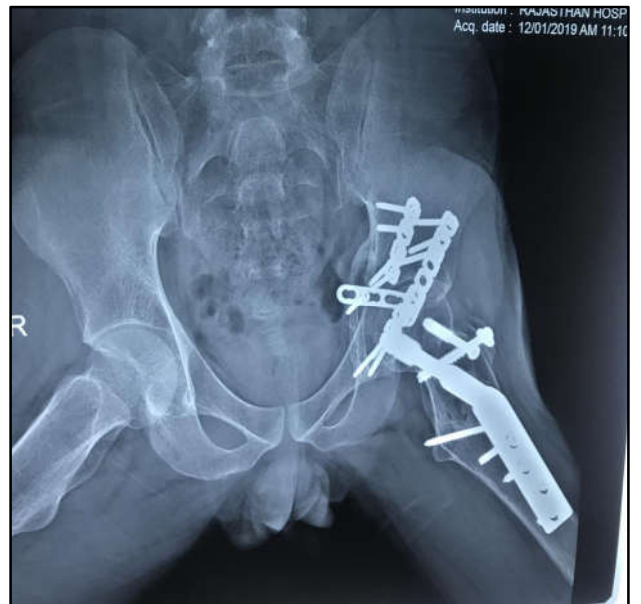
PRE OP X-RAY



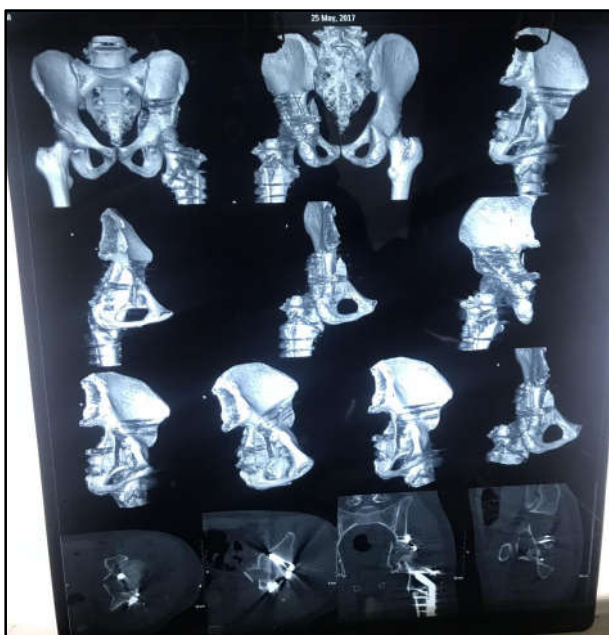
PRE OP CT scan



Final follow up X-ray



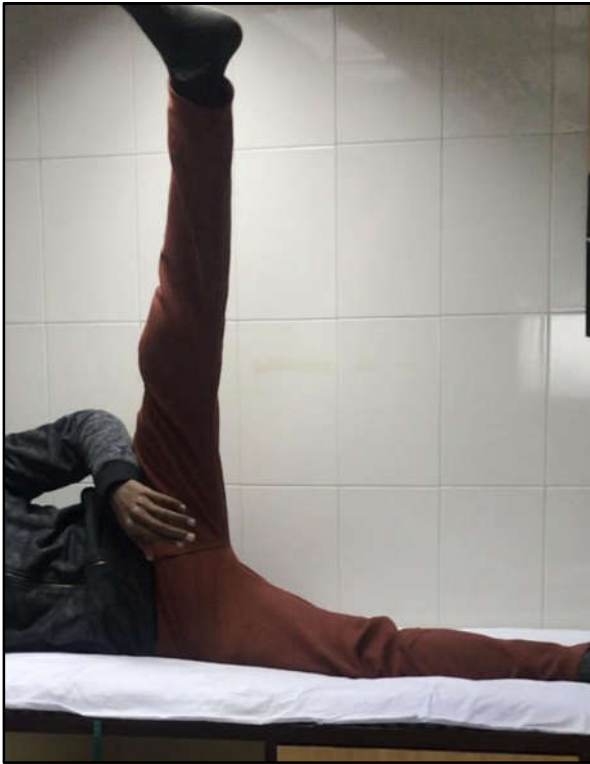Final follow up x-ray



Post op ct scan



Final range of motion



Final range of abduction at hip

These fractures are a result of high velocity trauma secondary to road traffic accidents or fall from height. Various combinations of fracture patterns are there in the floating hips. The difference of opinion exists in the order of fixation of Fracture. Liebergall (2002) said that the femur fracture fixation should take priority over acetabular fracture which was also followed by Suzuki *et al.* (2006) and suggested by Muller (1999) operated femur first. In cases with a concomitant acetabular fracture. Liebergall (2002) advocated early stabilisation of the femur fracture as per prevailing guidelines and a three to five-day delay for the fixation of acetabular fractures. Femur fracture was fixed first followed by fixation of unstable vertical shear injuries. Acetabulum fractures which involved the dome and posterior wall or column were all approached with the same Kocher-Langenbeck approach.

There was need for anterior Ilio-femoral approach and a trochanteric osteotomy when fracture lines extended up to the iliac wing or the anterior column (Barquet, 1983). In fractures of the femur involving the diaphysis or the distal third, fixation with plates and distal femur nails are preferred. This is desirable as we can avoid incisions proximally and preserve the anatomy of the area around the acetabulum. Proximal femur fractures can be approached laterally in the supine position on a fracture table and be fixed with a sliding hip screw and blade plates. The fixation of the acetabulum can proceed after transfer to a radiolucent table. If antegrade intramedullary nailing is required, it should be done preferably in the lateral position to incorporate its incision with the Kocher-Langenbeck incision. But the difficulty arise in visualisation of lateral view around head and neck while trying to visualise the femoral heads lateral projection. The benefits here is that there is no need to change positions for fixation of acetabular fractures. Suzuki et al and Wu et al in his paper on this In a case with minimally displaced acetabulum fracture they preferred to fix the femur first in fear of displacement of the acetabulum fracture (Suzuki, 2006).

Kregor and Templeman (Kregor, 2002) in their paper proposed three different protocols for such injuries the Fixation of the acetabulum followed by antegrade nailing, or fixation of acetabulum followed by plating of femur, and finally distal femur nailing of femur followed by acetabular fixation. He opined early preference for the acetabular fracture. Tiedeken *et al.* (2013) in his case opened the hip by the Kocher-Langenbeck approach and the joint was reduced and posterior wall acetabulum plated with reconstruction plates. The patient was then placed in supine position to fix the femur fracture by the retrograde method. Duygulu et al in their paper approached the hip by the posterolateral approach and fixed the transverse and posterior wall fractures by reconstruction plates.

Irifune *et al.* (2015) in their case report of an ipsilateral femoral neck, shaft and acetabular fractures, the femur shaft was fixed in the same sitting as the neck fracture. The shaft femur fracture was fixed by retrograde nailing and then patient was transferred to a traction table where the neck of femur fracture was fixed with multiple cannulated screws. The acetabulum fracture was operated on seven days after the femur surgery. The transverse acetabulum fracture was operated by the modified Stoppa technique followed by posterior wall fixation by the Kocher-Langenbeck approach. In my case IT Fracture was fixed on fracture table by putting screw traction device through fracture site and fixed with dynamic screw and barrel plate. incision was temporarily closed and patient shifted to simple table and positioned in lateral decubitus position. incision extended proximally and posterior acetabulum fixed with multiple plates.

Conclusion

Complex communitated fracture of acetabulum with posterior coloumn and posterior wall with ipsilateral intertrochanteric femur fracture should be dealt with utmost care and understanding priorities should be reduction of head of femur and fixation of intertrochanteric fracture. Acetabulum should be dealt immediately as soon as possible preferably in same sitting to avoid complications.

REFERENCES

- Agarwal A, Chadha M. 2004. Floating injuries: a review of the literature and proposal for a universal classification. *Acta Orthop Belg.* 70: 509–14.
- Alexa O., Puha B., Veliceasa B., Păduraru D. 2009. Posterior dislocation of the hip associated with ipsilateral trochanteric fracture--a very rare case. *Chirurgia (Bucur)* Nov-Dec;104(6):761–4. [PubMed] [Google Scholar]
- Barquet A., Mussio A. 1983. Fracture-dislocation of the femoral head with associated ipsilateral trochanteric and shaft fracture of the femur. *Arch Orthop Trauma Surg.* 102(1):61–3. [PubMed] [Google Scholar]
- Barrett MO., Anglen JO., Hoernschemeyer DG., Schnetzler KA. 2009. Case report: associated both-column acetabulum fracture with an ipsilateral centrally dislocated intertrochanteric femur fracture. *J Trauma.* Mar;66(3):918–21. [PubMed] [Google Scholar]
- Burd T., Hughes M., Anglen J. 2008. The floating hip: complications and outcomes. *J Trauma.*, 64: 442–8
- Canale ST., Manugian AH. 1979. Irreducible traumatic dislocations of the hip. *J Bone Joint Surg Am.*, Jan;61(1):7–14. [PubMed] [Google Scholar]

- Chen W., Su Y., Zhang Y., Zhang Q., Zheng Z., Pan J. 2010. Unusual combination of posterior femoral head dislocation with anterior and posterior wall fractures in the ipsilateral acetabulum. *Orthopedics*. Jun 9;33(6) [PubMed] [Google Scholar]
- Chi-Chuan W., Chun-Hsuing S., Lih-Huei C. 1993. Femoral shaft fractures complicated by fracture-dislocations of the ipsilateral hip. *J Trauma*, 34: 70–5
- Duygulu F., Calis M., Argun M., Guney A. 2006. Unusual Combination of Femoral Head Dislocation Associated Acetabular Fracture With Ipsilateral Neck and Shaft Fractures: A Case Report. *J Trauma*, 61:1545–154821
- Epstein HC. 1973. Traumatic dislocations of the hip. *Clin Orthop*. 92:116–42. [PubMed] [Google Scholar]
- Helal B., Skevis X. 1967. Unrecognized dislocation of the hip in fractures of the femoral shaft. *J Bone Joint Surg Br*, 49B: 296–300
- Iedeken NC., Saldanha V., Handal J., Raphael J. 2013. The irreducible floating hip: a unique presentation of a rare injury. *J Surg Case Rep*, 2013(10)
- Iotov A., Tzachev N., Enchev D., Baltov A. 2006. Operative treatment of the floating hip. *J Bone Joint Surg Br*, 88-B(Supp 1): 160
- Irifune H., Hirayama S., Takagi N., Narimatsu E. 2015. Ipsilateral Acetabular and Femoral Neck and shaft fractures. *Case Rep Ortop*, 2015
- J Orthop Case Reports. 2013 Oct-Dec; 3(4): 31–34. Skand Sinha, Ananta k Naik, Rajendra K Arya, Trauma J. 2010; 69: 405–1014. Giordano V, Amaral NP, Rios H, Franklin CE, Pallottino A. Management of ipsilateral fractures of the femur and pelvis (floating hip): a prospective study on 16 cases *Rev bras ortop*. 2007; 42: 9
- Keel MJ., Bastian JD., Buchler L., Siebenrock KA. 2010. Surgical dislocation of the hip for a locked traumatic posterior dislocation with associated femoral neck and acetabular fractures. *J Bone Joint Surg Br*, Mar;92(3):442–6. [PubMed] [Google Scholar]
- Kregor PJ., Templeman D. 2002. Associated injuries complicating the management of acetabular fractures. *Orthop Clin North Am*, 33: 73–9518
- Liebergall M., Lowe J., Whitelaw GP., Wetzler MJ., Segal D. 1992. The floating hip. Ipsilateral pelvic and femoral fractures. *J Bone Joint Surg Br*, 74: 93–100
- Liebergall M., Mosheiff R., Safran O., Peyser A., Segal D. 2002. The floating hip injury: patterns of injury. *Injury*. 33: 717–22.
- Muller EJ., Siebenrock K., Ekkernkamp A., Ganz R., Muhr G. 1999. Ipsilateral fractures of the pelvis and the femur—floating hip? A retrospective analysis of 42 cases. *Arch Orthop Trauma Surg*, 119: 179–82.
- Panetta T., Sclafani SJ., Goldstein AS., Phillips TF., Shaftan GW. 1985. Percutaneous transcatheter embolization for massive bleeding from pelvic fractures. *J Trauma*, 25: 1021–917.
- Sen R., Jha L. 2017. Floating Hip. *Journal of Clinical Orthopaedics* Jan – June 2(1):43–48.
- Simpson NS., Jupiter JB. 1995. Complex fracture patterns of the upper extremity. *Clin Orthop Relat Res*, 318: 43–53.3.
- Singh R., Sharma SC., Goel T. 2006. Traumatic inferior hip dislocation in an adult with ipsilateral trochanteric fracture. *J Orthop Trauma*. Mar;20(3):220–2. [PubMed] [Google Scholar]
- Suzuki T., Shindo M., Soma K. 2006. The floating hip injury: which should we fix first? *Eur J Orthop Surg Traumatol*.
- Thompson VP, Epstein HC. 1951. Traumatic dislocation of the hip; a survey of two hundred and four cases covering a period of twenty-one years. (33-A(3)). *J Bone Joint Surg Am*. Jul;746–78. [PubMed] [Google Scholar]
- Tile M. 1995. Fractures of pelvis and acetabulum. 2nd ed. Williams, Baltimore [chapter 19]19.
- Wiltberger BR., Mitchell CL., Hedrick DW. 1948. Fracture of the femoral shaft complicated by hip dislocation—a method of treatment. *J Bone Joint Surg Am*, 30A: 225–28
- Wu CL, Tseng IC, Huang JW, Yu YH, Su CY, Wu CC. Unstable pelvic fractures associated with Femoral shaft fractures: a retrospective analysis. *Biomed J*. 2013; 36(2): 77–83.
- Yashavantha C, Nalini K B, Nagaraj P, Jawal A. Ipsilateral Floating Hip and Floating Knee – A Rare Entity *Journal of Orthopaedic Case Reports* 2013 July-Sep;3(3): 3–622.
- Zamora-Navas P, Guerado E. Vascular complications in floating hip. *Hip Int*. 2010; 20: S11–8.
