



ISSN: 0975-833X

Available online at <http://www.journalcra.com>

International Journal of Current Research
Vol. 11, Issue, 12, pp.9155-9157, December, 2019

DOI: <https://doi.org/10.24941/ijcr.37337.12.2019>

INTERNATIONAL JOURNAL
OF CURRENT RESEARCH

RESEARCH ARTICLE

ESTHETIC REHABILITATION OF ANTERIOR TEETH : CASE REPORT

*Pooja Jain, Swalpa Sharma, Narendra Padiyar U., Pragati Kaurani and Devendra Pal Singh

Mahatma Gandhi University of Medical Science and Technology, Jaipur India

ARTICLE INFO

Article History:

Received 24th September, 2019
Received in revised form
08th October, 2019
Accepted 19th November, 2019
Published online 31st December, 2019

Key Words:

CAD-CAM, Zirconia Crowns,
Anterior Rehabilitation.

Copyright © 2019, Pooja Jain et al. This is an open access article distributed under the Creative Commons Attribution License, which permits unrestricted use, distribution, and reproduction in any medium, provided the original work is properly cited.

Citation: Pooja Jain, Swalpa Sharma, Narendra Padiyar U., Pragati Kaurani and Devendra Pal Singh, 2019. "Esthetic rehabilitation of anterior teeth: Case report", *International Journal of Current Research*, 11, (12), .9155-9157.

ABSTRACT

A 21 year old male patient reported to the department, and complains of malpositioned teeth even after he has undergone orthodontic treatment and wishes to improve the esthetic of his anterior teeth with prosthetic rehabilitation. Treatment plan for this patient includes CAD- CAM designing followed by zirconia crown on all maxillary anterior teeth

INTRODUCTION

In our modern competitive society, a pleasing appearance often means the difference between success and failure in both our personal and professional lives. A charming smile can open doors and knock down barriers that stand between you and a fuller, richer life. An attractive or pleasing smile clearly enhances the acceptance of the individual in the society where he belongs and the character of the smile influences to the great extent the attractiveness and the personality of the individual.

Esthetics (GPT 9): The branch of philosophy dealing with beauty. In dentistry, the theory and philosophy that deal with beauty and the beautiful, especially with respect to the appearance of a dental restorations, as achieved through its form and or color. Those subjective and objective elements and principles underlying the beauty and attractiveness of an object, design or principle.

CASE REPORT

A 21 year old male patient reported to the department, and complains of malpositioned teeth even after he has undergone orthodontic treatment and wishes to improve the esthetic of his anterior teeth with prosthetic rehabilitation.

There was no finding in his medical history and dental history revealed extraction irt 12, RCT irt 11,21,22,31,41,42, undergone orthodontic treatment. On oral examination we found missing irt 12, generalised spacing in upper anterior teeth, open bite, labially placed 21, palatally placed 11. radiographic findings were ankylosed tooth irt. 11, root resorption irt.22, RCT irt 11,21,22,31,41,42.

Treatment plan: In the first treatment visit, diagnostic impressions, face bow record, centric bite were made for esthetic evaluation, photograph were used to facilitate communication with the patient and laboratory technician. Mock preparation & diagnostic wax up was done irt 11,12,13,21,22,23. In the second visit : crown preparation done irt 11,13,21,22,23,31,32,33 and interim restorations were carried out using tooth molding material by indirect technique and aimed to restore esthetic. for final impressions retraction cord were placed and a double-mix impression technique, with addition silicone was used to reproduce the teeth and surrounding soft tissue. Working casts were obtained for the laboratory procedures. CAD CAM designing was carried out for final prosthesis. Marginal adaptation, occlusal and interproximal contacts were accessed to establish biologic and esthetic parameters for final prosthesis, resin cement was used for cementation. Oral fluids and any hemorrhage process were controlled. Afterward, the excess resin cement was removed.

DISCUSSION

Beauty is power; A smile is its sword

*Corresponding author: Pooja Jain,

Mahatma Gandhi University of Medical Science and Technology,
Jaipur India.

-John Ray

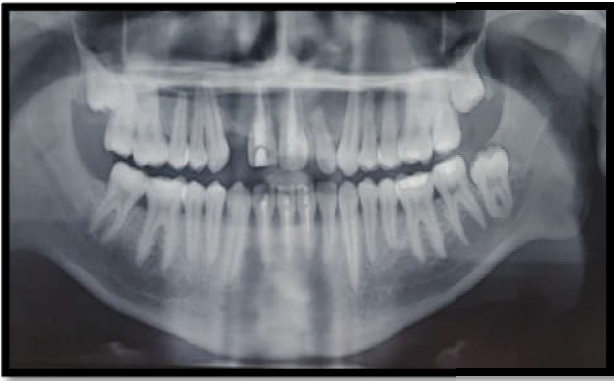


Fig.1. OPG

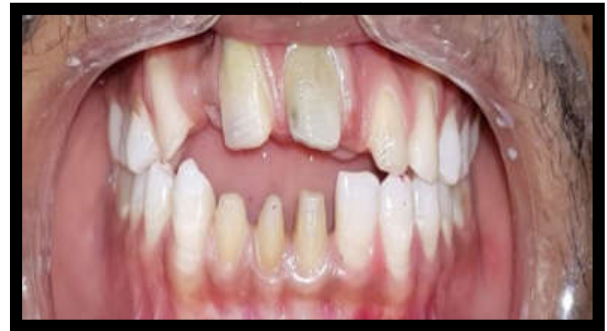

Fig.5. Preparation Photographs

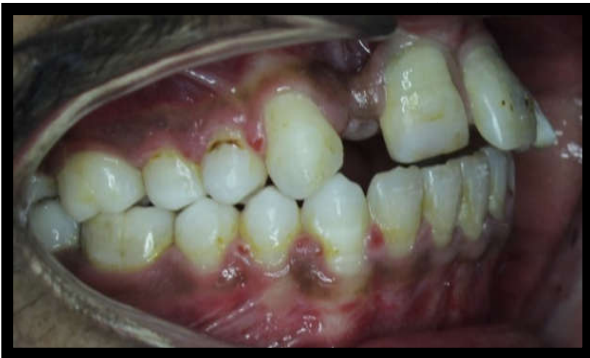

Fig. 2. Lateral View (Preoperative)

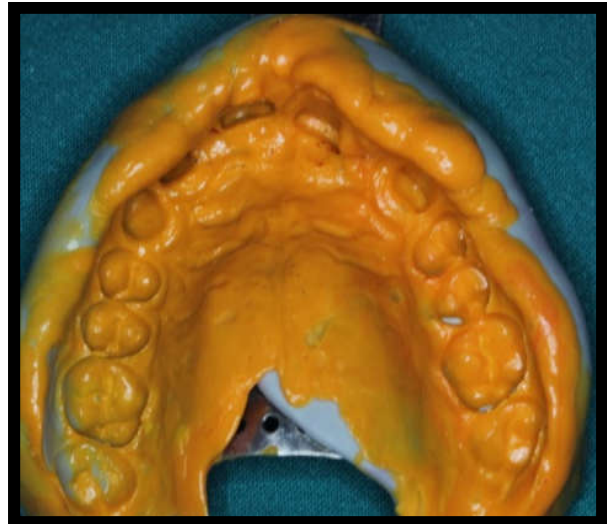

Fig 6. Final Impression

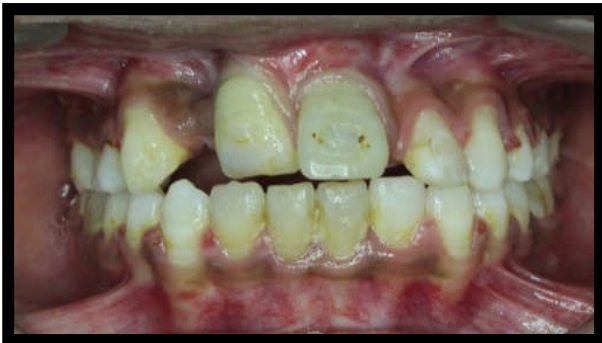

Fig. 3. Preoperative photograph

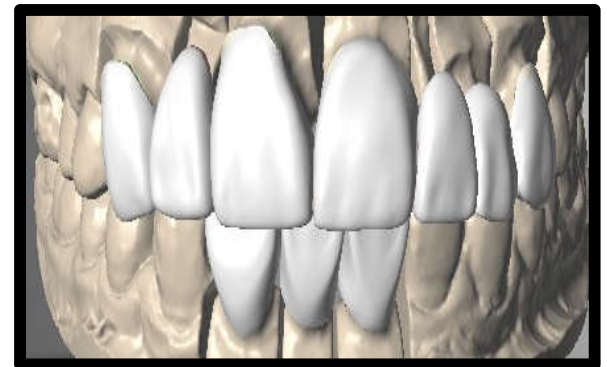


Fig.7. Cad Cam Planning

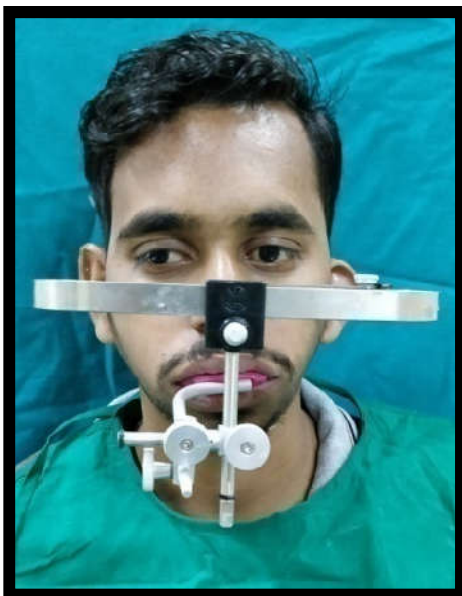

Fig.4. Face Bow Transfer

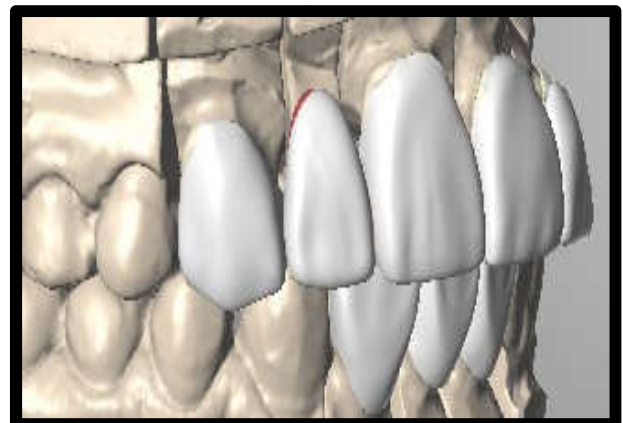


Fig.8. Cad-Cam Planning (Lateral View)

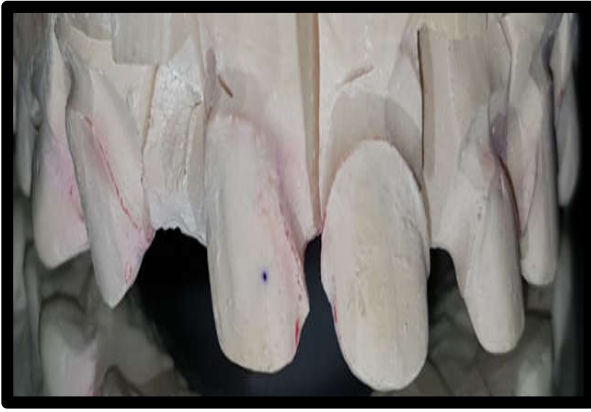

Fig.9. Final cast

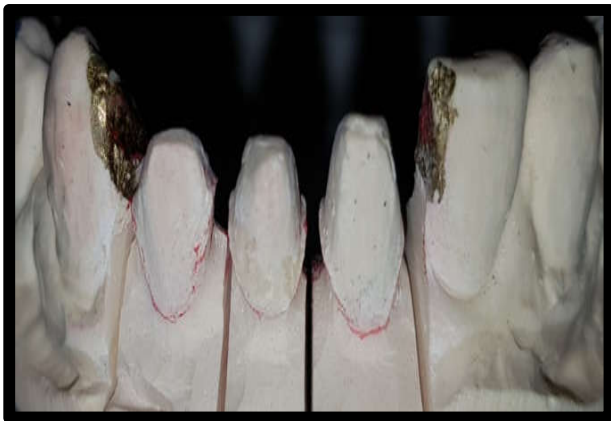

Fig.10 Mandibular master cast

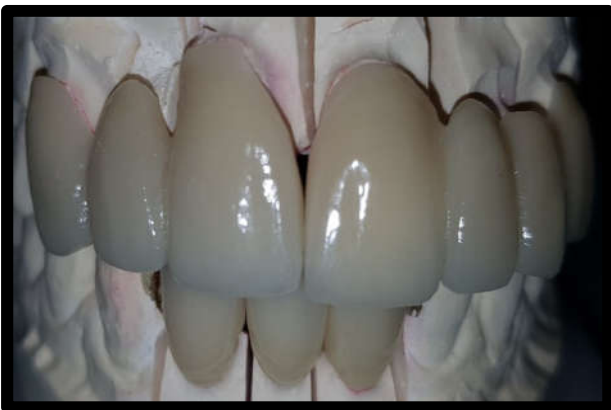

Fig.11 Zirconia crowns

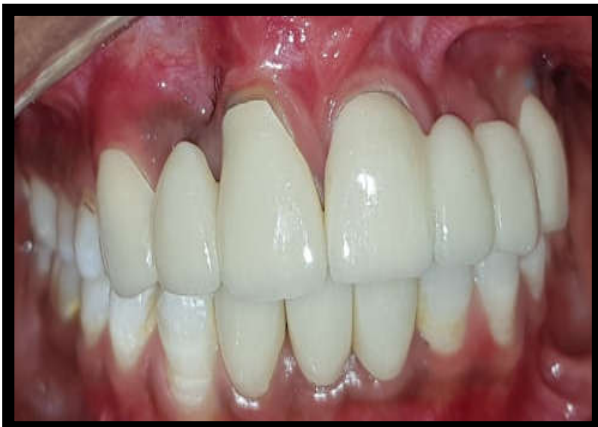

Fig.12. Final Prosthesis (Front View)

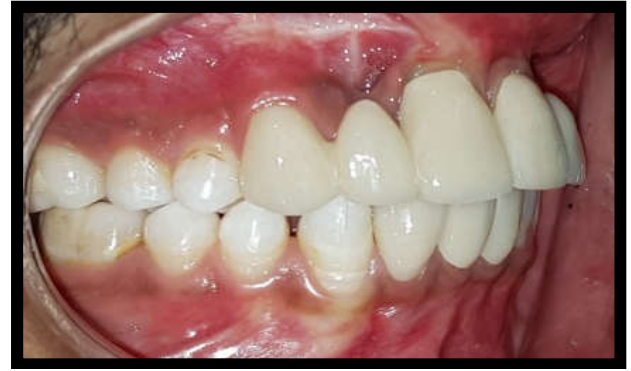

Fig.13. Final Prosthesis (Lateral View)

Scottish physiologist Charles bell (1774-1842) was quoted as remarking that the thought is to the word that the feeling is to the facial expression. He pointed out in 1806 that a smile could convey a thousand different meanings, yet it is the most easily recognized expression. Smile is dependant on the musculature and Basically the presence of the teeth. But every person is not blessed enough to have a beautiful smile. We as a Prosthodontist is probably the best person to identify the quality of smile. Digitalization has become an integral part and parcel of contemporary dentistry. Zirconia (ULTRA T) crowns showed promising result in restoring anterior teeth as they are Milled over CAD/CAM hence precise on fit and perfect with function in the mouth, Material of choice for anterior cases & Recommended for discoloured teeth. Zirconia frameworks for prosthetic rehabilitation, is preferred over ceramic, as ceramic fractures has been reported as a frequent complication. chipping and fractures of ceramic is thus a major problem both on metal ceramic and all-ceramic crowns. Adhesive resin cement has contributed to the rising importance of innovative restorative dentistry. They bond chemically and hence can be used even if no retentive preparation has been performed. Dual cure version (variolink esthetic DC) is suitable with ceramic and composite where complete polymerization with light cannot be ensured because of materials opacity or strong wall thickness. In such cases, complete polymerization is achieved by materials combination of light and self curing properties, resulting in a reliable adhesion of the restoration.

Conclusion

Advancement in the technique, has made the esthetic treatment more pleasing as the crowns showed promising result in restoring anterior teeth and are milled over CAD/CAM hence precise on fit and perfect with function in the mouth.

REFERENCES

- Sadowsky, SJ. 2006. An overview of treatment considerations for esthetic restorations: a review of the literature. *J Prosthet Dent.*, 96:433-42.
- Groten M. 2007. Complete esthetic and functional rehabilitation with adhesively luted all-ceramic restorations. A case report over 4.5 year. *Quintess Int* 38:723-31.
- Guess PC., Stappert CF. 2008. Midterm results of a 5-year prospective clinical investigation of extended ceramic veneers. *Dent Mater.*, 24:804-13
- Small BW. 2012. Anterior restorations: Crowns, veneers, or direct composite. How do you decide? *Gen Dent.*, 60:179-81