



ISSN: 0975-833X

Available online at <http://www.journalcra.com>

INTERNATIONAL JOURNAL  
OF CURRENT RESEARCH

International Journal of Current Research  
Vol. 12, Issue, 01, pp.9716-9717, January, 2020

DOI: <https://doi.org/10.24941/ijcr.37787.01.2020>

## REVIEW ARTICLE

### CASE REPORT -AUTOLOGOUS TRANSFUSION AND TOTAL THYROIDECTOMY FOR PATIENT WITH GOITRE AND THROMBOCYTOSIS

\*Dr. Kaveti Vihitha Reddy, Dr. Prasad Kulkarni and Dr. Rahul Kishore

Department of Anaesthesia, Institute: MVJ Medical College and Research Hospital, Hoskote, Bengaluru

#### ARTICLE INFO

##### Article History:

Received 24<sup>th</sup> October, 2019  
Received in revised form  
30<sup>th</sup> November, 2019  
Accepted 19<sup>th</sup> December, 2019  
Published online 30<sup>th</sup> January, 2020

##### Key Words:

Autologous Transfusion,  
Thrombocytopenia.

#### ABSTRACT

**Introduction:** Autologous blood transfusion is the collection of blood from a single patient and re-transfusion back to the same patient when required. The primary driving forces for the use of autologous blood transfusion are to reduce the risk of transmission of infection and to protect an increasingly scarce resource. **Case report:** A 60 Year old female patient posted for thyroidectomy. On examination solitary swelling in front of the neck of 8\*8 cm, oval in shape, smooth surface, extending superiorly upto hyoid bone and inferiorly till suprasternal notch. TFT showed euthyroid state and Blood counts revealed thrombocytosis-7lakhs cu mm. All other investigations were within normal limits. Patient planned for General anaesthesia with nasal intubation(MO<2F). ENT opinion was taken and bilateral vocal cords were reported to be normal. Intraoperative events uneventful. Postoperative subsequent retransfusion of red blood cells along with normal saline was done to preserve adequate blood volume. This technique reduced the platelet count without a significant alteration in coagulation factor activity. Postoperative subsequent retransfusion of red blood cells along with normal saline was done to preserve adequate blood volume. This technique reduced the platelet count without a significant alteration in coagulation factor activity. **Discussion:** Thrombocytosis is a commonly encountered clinical scenario, with a large proportion of cases discovered incidentally. Thrombocytosis can be spurious, attributed to a reactive process or due to clonal disorder. The threshold for clinically significant thrombocytosis is variable from patient to patient, a platelet count of  $\geq 450 \times 10^9/L$  is a generally accepted value. ANH is performed in the anaesthetic room shortly after induction of anaesthesia. A large-bore cannula is inserted to allow the collection of 15–20 ml  $kg^{-1}$  of blood prior to surgery. Blood volume is restored with crystalloid or colloid. The collected blood is carefully labelled and kept with the patient in the operating room at all times; there is no need for refrigeration. The blood is transfused back to the patient at the end of surgery once haemostasis is achieved. **Conclusion:** Autologous blood transfusion, when used appropriately, can provide a safe alternative to allogenic blood transfusion. However, there will always be a need for allogenic blood (even patients who have autologous blood may need further transfusion with allogenic units). There is an important need to balance use of resources in ensuring safe blood transfusion for all those who need it.

Copyright © 2020, Kaveti Vihitha Reddy et al. This is an open access article distributed under the Creative Commons Attribution License, which permits unrestricted use, distribution, and reproduction in any medium, provided the original work is properly cited.

Citation: Dr. Kaveti Vihitha Reddy, Dr. Prasad Kulkarni and Dr. Rahul Kishore. 2020. "Case report -autologous transfusion and total thyroidectomy for patient with goitre and thrombocytosis", *International Journal of Current Research*, 12, (01), 9716-9717.

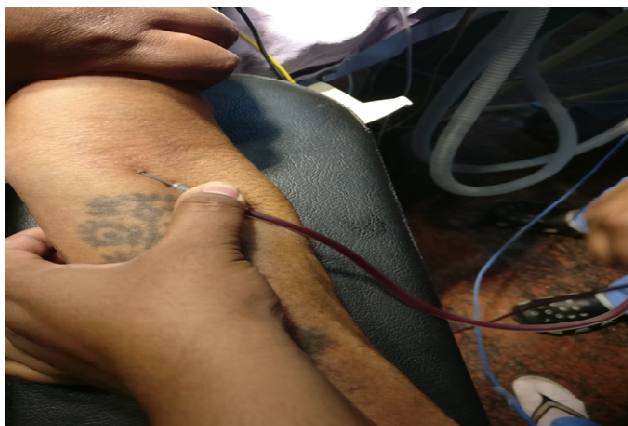#### INTRODUCTION

Autologous blood transfusion is the collection of blood from a single patient and re-transfusion back to the same patient when required. The primary driving forces for the use of autologous blood transfusion are to reduce the risk of transmission of infection and to protect an increasingly scarce resource.


**Case report:** A 60 Year old female patient posted for thyroidectomy. On examination solitary swelling in front of the neck of 8\*8 cm, oval in shape, smooth surface, extending

\*Corresponding author: Dr. Kaveti Vihitha Reddy,  
Department of Anaesthesia, Institute: MVJ Medical College and  
Research Hospital, Hoskote, Bengaluru.

superiorly upto hyoid bone and inferiorly till suprasternal notch. TFT showed euthyroid state and Blood counts revealed thrombocytosis-7lakhs cu mm. All other investigations were within normal limits. Patient planned for General anaesthesia with nasal intubation(MO<2F). ENT opinion was taken and bilateral vocal cords were reported to be normal. Intraoperative events uneventful. Postoperative subsequent retransfusion of red blood cells along with normal saline was done to preserve adequate blood volume. This technique reduced the platelet count without a significant alteration in coagulation factor activity. Postoperative subsequent retransfusion of red blood cells along with normal saline was done to preserve adequate blood volume. This technique reduced the platelet count without a significant alteration in coagulation factor activity.



**Fig. 1. Autologous transfusion procedure**



**Fig. 2. Autologous transfusion procedure**

The threshold for clinically significant thrombocytosis is variable from patient to patient, a platelet count of  $\geq 450 \times 10^9/L$  is a generally accepted value. ANH is performed in the anaesthetic room shortly after induction of anaesthesia. A large-bore cannula is inserted to allow the collection of 15–20 ml  $kg^{-1}$  of blood prior to surgery. Blood volume is restored with crystalloid or colloid. The collected blood is carefully labelled and kept with the patient in the operating room at all times; there is no need for refrigeration. The blood is transfused back to the patient at the end of surgery once haemostasis is achieved.

### Conclusion

Autologous blood transfusion, when used appropriately, can provide a safe alternative to allogenic blood transfusion. However, there will always be a need for allogenic blood (even patients who have autologous blood may need further transfusion with allogenic units). There is an important need to balance use of resources in ensuring safe blood transfusion for all those who need it.

### REFERENCES

- Catalano L, Campolongo A, Caponera M, et al., 2014. Indications and organisational methods for autologous blood transfusion procedures in Italy: results of a national survey. *Blood Transfus.* 12(4):497–508. doi:10.2450/2014.0295-13
- Shukla, P., Dwivedi, S., Bhargava, M. et al., 2014. Intraoperative Autologous Blood Transfusion of Peritoneal Blood During Laparotomy for Ectopic Pregnancy: Prospective Study. *J ObstetGynecol India* 64, 358–361.

### DISCUSSION

Thrombocytosis is a commonly encountered clinical scenario, with a large proportion of cases discovered incidentally. Thrombocytosis can be spurious, attributed to a reactive process or due to clonal disorder.

\*\*\*\*\*