



ISSN: 0975-833X

Available online at <http://www.journalcra.com>

International Journal of Current Research
Vol. 12, Issue, 02, pp.10077-10079, February, 2020

DOI: <https://doi.org/10.24941/ijcr.37897.02.2020>

INTERNATIONAL JOURNAL
OF CURRENT RESEARCH

RESEARCH ARTICLE

MICROCURRENT THERAPY AS A POTENTIAL MEASURE FOR TREATMENT OF PRESSURE ULCER - A CASE REPORT

^{1,*}Subash Palanisamy and ²Dr. Ramamoorthy Veyilmuthu

¹M.P.T (Neurology), Senior Physiotherapist Grade III, Department of Physical Medicine and Rehabilitation, PSG IMS&R Hospitals, Coimbatore, India

²M.D (PMR), Professor, Department of Physical Medicine and Rehabilitation, PSG IMS&R Hospitals, Coimbatore, India

ARTICLE INFO

Article History:

Received 04th November, 2019

Received in revised form

10th December, 2019

Accepted 29th January, 2020

Published online 28th February, 2020

Key Words:

Pressure Ulcer,
Microcurrent Therapy,
Wound Healing.

ABSTRACT

Background and Purpose: Electrical stimulation has been used in clinical practice to accelerate wound healing for which positive results have been reported in clinical studies. The Purpose of the case report is to document the clinical effects of application of microcurrent stimulation in healing of pressure ulcer in a chronic bedridden patient. **Case Description:** The Patient was a 53 year old male who was diagnosed to have Cerebro vascular accident with Intraventricular hemorrhage and subsequent hydrocephalus underwent external ventricular drainage and Ventriculo peritoneal shunting before one year. Current evaluation demonstrated primary impairments of muscle weakness in right upper and lower limbs associated with activity limitation of bed mobility and ambulation. The patient also had secondary impairments of grade IV pressure ulcer in the sacral region. A plan of care was developed to focus on the management of primary and secondary impairments along with application of microcurrent electrical stimulation for management of pressure ulcer. **Outcomes:** The patient had benefits with significant reduction in the surface area of the pressure ulcer following 8 weeks of microcurrent stimulation. The Pressure Ulcer Scale for Healing (PUSH) showed a significant change from a score of 15 at week one, to a score of 6 at the end of 8 weeks. **Discussion:** Pressure ulcers are one of the most common issues in the elderly and immobile individuals, which constitute a major psychological and physiological burden with reduced quality of life. Among the treatment options, this research report focuses on the beneficial effects of Microcurrent electrical stimulation, based on its results in pain control, edema control and wound healing.

Copyright © 2020, Subash Palanisamy and Dr. Ramamoorthy Veyilmuthu. This is an open access article distributed under the Creative Commons Attribution License, which permits unrestricted use, distribution, and reproduction in any medium, provided the original work is properly cited.

Citation: Subash Palanisamy and Dr. Ramamoorthy Veyilmuthu, 2020. "Microcurrent therapy as a potential measure for treatment of pressure ulcer - a case report.", *International Journal of Current Research*, 12, (02), 10077-10079.

INTRODUCTION

Microcurrent therapy (MCT) is a form of low-intensity, direct current that delivers monophasic or biphasic pulsed micro amperage currents across the skin, below the sensation threshold which is a novel treatment for different pain disorders and wounds (Koopman, 2009). It has been used to regenerate the internal bioelectrical activity of injured tissues and has been consistent with that of endogenous currents that act at the cellular level. Application of microcurrent can influence the behaviour of cells involved in healing processes such as migration, proliferation and production of proteins and cytokines. At the tissue level, it can promote angiogenesis, neural sprouting and increase the rate of tissue synthesis (Poltawski, 2009). Microcurrent therapy results in accelerated healing of wounds compared with sham therapy.

Sufficient literature has reported positive outcomes as the result of application of microcurrent therapy in a range of pain syndromes, venous ulcers and open wounds. In this case report we have provided description about application effects of microcurrent therapy for healing of pressure ulcer wounds. A pressure ulcer, also known as pressure sore, decubitus ulcer, or bedsore, is defined as a localized injury to the skin and/ or underlying tissue occurring most often over a bony prominence and caused by pressure, shear, or friction forces alone or in combination. Pressure ulcers represent a major burden to patients and caretakers and have a detrimental effect on patients' quality of life (Grey, 2006). Pressure ulcers are classified into four categories: Stage I describes intact skin with nonblanchable erythema; Stage II pressure ulcers have partial-thickness skin damage with possible blister formation, but no subcutaneous tissues visible; Stage III pressure ulcers have full-thickness skin loss with subcutaneous fat exposed but no muscles, bones, or tendons visible; Stage IV pressure ulcers have tissue loss with exposure of muscles, bones, tendons, or vital organs (Dealey, 2006).

*Corresponding author: Subash Palanisamy,

M.P.T (Neurology), Senior Physiotherapist Grade III, Department of Physical Medicine and Rehabilitation, PSG IMS&R Hospitals, Coimbatore, India.

Pressure ulcer prevention aims to eliminate or reduce factors that predispose a person to pressure ulcer development. Strategies commonly used include other than regular risk assessment, use of special pressure relieving support surfaces, regular repositioning and turning, local skin care, nutrition support, removal of necrotic tissue, prevention of skin maceration, control of infections, which encourages soft tissue repair (Reddy, 2006). The purpose of the case report is to identify the effects of application of microcurrent therapy along with routine care for healing of pressure ulcer.

CASE DESCRIPTION: The patient was a 53 years old male who had been present with systemic hypertension over a period of 1 year, diagnosed to have an episode of cerebrovascular accident – interventricular hemorrhage, intracerebral hemorrhage and a subsequent episode of hydrocephalus before 1 year. He subsequently underwent conservative management for CVA and surgical treatment for hydrocephalus with external ventricular drainage followed by ventriculo peritoneal shunting performed by a neurosurgeon. The Patient underwent post surgical care and inpatient rehabilitation for a period of 85 days and was discharged to home from a tertiary care hospital. After a period of 6 months, the patient was admitted for provision of rehabilitation care. During that time, patient is confined to bed with complaints of weakness of muscles of both upper and lower extremities, decreased bed mobility, pressure ulcer in the sacral region and was completely dependent for performing activities of daily living (ADL). A review of systems demonstrated normal higher mental functions along with impairments in motor, sensory and integumentary functions. He had severe neurological impairments with a score of 40/56 in Scandinavian Stroke Scale (SSS), had modified dependence in functional activities with a score of 80/126 on the Functional Independent Measure (FIM).

Integumentary system examination revealed that the patient has grade IV pressure ulcer in the sacral region – Full thickness skin and tissue loss with exposure of muscles, tendons, bones and vital organs. The pressure ulcer scale for healing (PUSH tool) is a commonly used tool developed by the NPUAP, which grades pressure ulcers based on size of wound, wound bed tissue type, and exudate amount.(6)The pressure ulcer scale for healing (PUSH tool) Version 3.0 was used to assess the extent of ulcer. The patient had a PUSH score of 15 initially with a score of 10 in the Length X Width component as the wound had a total surface area of 46 cm², a score of 2 in the exudates component with moderate amount of exudate and a score of 3 in the tissue type component with slough tissues.

Intervention: The patient underwent regular physiotherapy treatment with short term goals to improve voluntary motor control, bed mobility and transfers, long term goals being set towards improvement of locomotor ability and independent activities of daily living. For the treatment of pressure ulcer, regular positioning care and saline dressing were the primary treatment choice along with application of microcurrent therapy. An intellect combination therapy unit was used to deliver microcurrents through reusable carbon-impregnated silicon rubber electrodes, with intensity within range of 20 – 50µA and negative polarity. The electrodes are placed such that it covers the surface area of the wound. The patient received microcurrent therapy for a duration of 20 minutes per session per day, six days a week for eight weeks. The patient underwent positioning care with regular change of position for every 2 hours and wound care with saline dressing for two times a day. During the course of treatment, the patient did not have/report any adverse events.

Table 1. Pressure Ulcer Scale for Healing (PUSH) weekly scores

Variables	On Initial Assessment	2 nd week	4 th week	6 th week	8 th week
Length X width	10	9	8	7	5
Exudate amount	2	1	1	0	0
Tissue type	3	3	3	2	1
PUSH total score	15	13	12	9	6

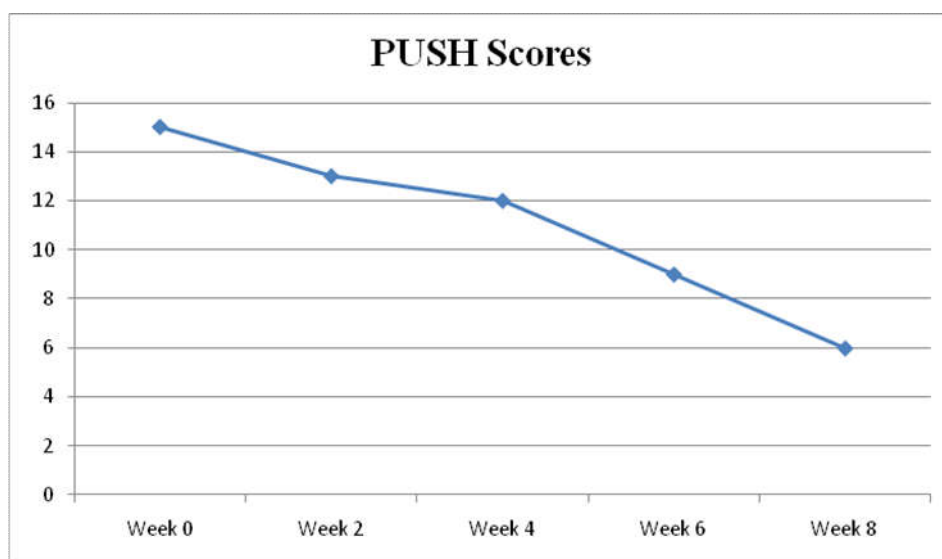


Figure 1. Graphical representation of PUSH scores monitored weekly

Outcome Measures

The pressure ulcer scale for healing (PUSH tool) Version 3.0 was used to assess the healing of ulcer. The PUSH model provides an accurate, simple, and clinically useful way to measure progress toward wound healing. Assessment of the ulcer characteristics include surface area, exudate amount (none, light, moderate, and heavy), and surface appearance (necrotic tissue, slough, granulation tissue, epithelial tissue, and closed). Each parameter is scored, and the sum of the three yields a total wound status score.

RESULTS

The pressure ulcer wound was monitored every week with PUSH score. At the end of six weeks of application of microcurrent electrical stimulation, the following results were obtained: (i) reduction in the wound surface area from the initial size of 46 cm² to 2.5 cm², ii) the exudates from the wound were completely absent, iii) Wound was completely covered with epithelial tissue from the initial stages of slough tissue. The findings resulted in a change of total PUSH score from 15 at day 1 to a score of 6 at the end of eight weeks.¹

DISCUSSION

In this case report, we have reported the effects of microcurrent electrical stimulation on healing of pressure ulcer in an individual with severe mobility impairments. Previous studies have documented that adequate mobility is one of the efficient strategy in the process of healing of pressure ulcer.⁽⁵⁾To accelerate wound healing process in an individual with impaired mobility, the intervention strategies such as utilisation of pressure relieving support surfaces, adequate nutrition, wound care and regular positioning care is alone inadequate. In scenarios where endogenous healing has failed or healing has become obsolete, adjunct use of microcurrent therapy which is the transcutaneous delivery of miniature pulsating current that mimics the currents generated in the body at the cellular level, also known to stimulate cellular physiology and growth may be favorable ⁽⁷⁾².

Along with the use of conventional saline dressing and regular positioning, microcurrent therapy have resulted in reduction in wound surface area, improvement in tissue healing and growth in the wound site, demonstrated by a gradual decrease in the PUSH score through the weeks. At the end of eight weeks of microcurrent application, the total PUSH score had shown a change of 9 points from the time of initial assessment, a magnitude of change of 60%. The wound surface area has been reduced by 94%, with a change from initial size of 46cm² to 2.6 cm² at the end of eight weeks. Microcurrent application have been identified to physiologically help in re-establishment of tissue bio-electricity by imitating endogenous electrical signals that can guide cellular behavior and the proposed mechanisms of galvanotaxis which is attraction of positively/negatively charged cells towards the opposite pole of an electric field, thereby increasing transportation, cell migration, proliferation and synthesis of new tissue which are essential in the healing process (8,9).

Experimental studies involving the use of microcurrent electrical stimulation in larger specific population targeting wound healing are suggested. Therefore, the microcurrent electrical stimulation is considered an alternative for wound treatment specifically with in those with failed natural healing, reparation difficulties, devitalized tissue like pressure, diabetic, stasis and arterial ulcers.

Conclusion

These results indicate that microcurrent therapy has a positive effect in healing of pressure ulcers and it is preferable because of its easy application, acceleration in the healing and low cost.

Conflict of Interest: Ethical approval has been obtained for the case report from the Institute of Human ethics committee, PSG Institute of Medical Sciences and Research.

REFERENCES

- Balakatounis KC., Angoules AG. 2008. Low-intensity electrical stimulation in wound healing: review of the efficacy of externally applied currents resembling the current of injury. *Eplasty*.8.
- Dealey C., Lindholm C. 2006. Pressure ulcer classification. *In* Science and practice of pressure ulcer management (pp. 37-41). Springer, London.
- Grey JE., Harding KG., Enoch S. 2006. Pressure ulcers. *Bmj*. Feb 23;332(7539):472-5.
- Koopman JS., Vrinten DH., van Wijck AJ. 2009. Efficacy of microcurrent therapy in the treatment of chronic nonspecific back pain: a pilot study. *The Clinical journal of pain*. Jul 1;25(6):495-9.
- Lessiani G., Galati V., Franzone G., Iodice P. 2014. Efficacy of modulated microcurrent stimulation in pressure ulcers treatment: A monocentric, prospective, double-blind, randomized study. *J Nov Physiother.*, 4(224):2.
- Nair HK. 2018. Microcurrent as an adjunct therapy to accelerate chronic wound healing and reduce patient pain. *Journal of wound care*. May 2;27(5):296-306.
- Poltawski L., Watson T. 2009. Bioelectricity and microcurrent therapy for tissue healing – a narrative review. *Physical Therapy Reviews.*, 14(2):104–14.
- Reddy M., Gill SS., Rochon PA. 2006. Preventing pressure ulcers: a systematic review. *Jama*. Aug 23;296(8):974-84.
- Stotts NA., Rodeheaver GT., Thomas DR., Frantz RA., Bartolucci AA., Sussman C., Ferrell BA., Cuddigan J., Maklebust J. 2001. An instrument to measure healing in pressure ulcers: development and validation of the pressure ulcer scale for healing (PUSH). *The Journals of Gerontology Series A: Biological Sciences and Medical Sciences*. Dec 1;56(12):M795-9.