



ISSN: 0975-833X

Available online at <http://www.journalcra.com>

International Journal of Current Research  
Vol. 12, Issue, 07, pp.12573-12577, July, 2020

DOI: <https://doi.org/10.24941/ijcr.38867.07.2020>

INTERNATIONAL JOURNAL  
OF CURRENT RESEARCH

## RESEARCH ARTICLE

### PROFILE CHANGES AFTER USING CLARK'S TWINBLOCK APPLIANCE IN A GROWING MALE PATIENT WITH A SKELETAL CLASS II PATTERN AND A RECESSIVE LOWER JAW - A CASE REPORT

<sup>1</sup>Dr. Bhushan Jawale, <sup>2,\*</sup>Dr. Lishoy Rodrigues, <sup>3</sup>Dr. Sameer Patil, <sup>4</sup>Dr. Keluskar, K.M.  
<sup>5</sup>Dr. Anup Belludi and <sup>6</sup>Dr. Biju Kalarickal

<sup>1</sup>Professor, Dept. of Orthodontics and Dentofacial Orthopedics, Sinhgad Dental College and Hospital, Sinhgad, Pune, Maharashtra, India

<sup>2</sup>Post Graduate Resident, Dept. of Orthodontics and Dentofacial Orthopedics, Sinhgad Dental College and Hospital, Sinhgad, Pune, Maharashtra, India

<sup>3</sup>Dean, Professor and HOD, Dept. of Orthodontics and Dentofacial Orthopedics, Sinhgad Dental College and Hospital, Sinhgad, Pune, Maharashtra, India

<sup>4</sup>Dean, Professor and HOD, Dept. of Orthodontics and Dentofacial Orthopedics, KLE Dental College and Hospital, Belgaum, Karnataka, India

<sup>5</sup>Professor and HOD, Dept of Orthodontics and Dentofacial Orthopedics, KLE Dental College and Hospital, Bangalore

<sup>6</sup>Professor, Dept of Orthodontics and Dentofacial Orthopedics, Mar Baselios Dental College and Hospital, Thangalam, Ernakulam, Kothamangalam, Kerala, India

#### ARTICLE INFO

##### Article History:

Received 07<sup>th</sup> April, 2020

Received in revised form

25<sup>th</sup> May, 2020

Accepted 27<sup>th</sup> June, 2020

Published online 30<sup>th</sup> July, 2020

##### Key Words:

Twinblock, Class II Skeletal pattern, Recessive lower Jaw, Profile changes

**Copyright** © 2020, Bhushan Jawale et al. This is an open access article distributed under the Creative Commons Attribution License, which permits unrestricted use, distribution, and reproduction in any medium, provided the original work is properly cited.

**Citation:** Dr. Bhushan Jawale, Dr. Lishoy Rodrigues, Dr. Sameer Patil, Dr. Keluskar, K.M. Dr. Anup Belludi and Dr. Biju Kalarickal. 2020. "Profile Changes After Using Clark's Twinblock Appliance in a Growing Male Patient with a Skeletal Class II Pattern and a Recessive Lower Jaw - A Case Report", *International Journal of Current Research*, 12, (07), 12573-12577.

#### ABSTRACT

Twin block appliance from its inception and evolution itself has been widely accepted as a more competent Class II corrector compared to earlier bulky monoblock appliances. Functional appliances can be used successfully in growing patients with certain skeletal Class II patients. Twin block appliance is very effective in a growing patient. The successful use of this appliance in the treatment of skeletal Class II malocclusion is based upon factors such as; age of patient, compliance of the patient and other case selection criteria. This appliance is very successful in a patient with a retrognathic mandible and well aligned arches with a positive VTO. This efficiently enables the mandibular forward positioning and improves the profile. This case report is of a 13-year-old growing male patient with a Skeletal Class II Pattern and a recessive lower jaw who was treated with Twin block appliance. The profile changes and treatment results were demonstrated. In permanent dentition, twin block appliance produces a similar effect as in mixed dentition phase. With proper case selection and good patient cooperation, we can obtain a significant result with twin block appliance.

#### INTRODUCTION

Dentofacial orthopedic treatment can significantly alter and improve facial appearance in addition to correcting irregularity of the teeth. Functional appliance therapy can be used successfully in Class II malocclusion, e.g., in a growing patient. Twin blocks are simple bite blocks that interlock at a 70° angle and correct the maxillomandibular relationship through functional mandibular displacement. The twin block appliance was developed by Clark in 1980s. They modify the occlusal inclined plane, guiding the mandible forward into correct occlusion. The use of these appliances is greatly dependent on patient's compliance and they simplify the fixed appliance phase.

Functional appliances may be defined as orthodontic appliances that use the forces generated by the muscles to achieve dental and skeletal changes.(1,2) These appliances have been used in clinical orthodontics for a long time and are extensively featured in the literature.(3,4) .

Their effect is produced from the forces generated by the stretching of the muscles.(5) It is a commonly used functional appliance partly due to its acceptability by patients (Chadwick et al., 1998).(6) the muscles and soft tissues are stretched with the generated pressure transmitted to the skeletal and dental structures potentially resulting in skeletal growth modification and tooth movement.

\*Corresponding author: Dr. Lishoy Rodrigues,

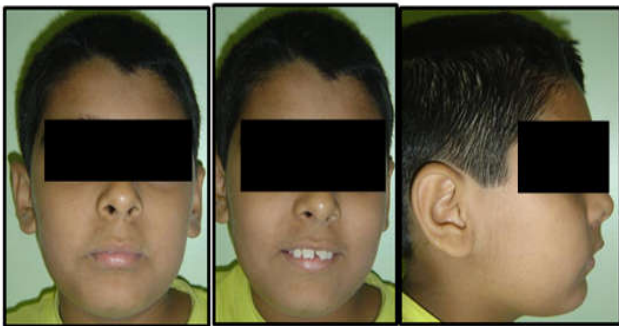Post Graduate Resident, Dept. of Orthodontics and Dentofacial Orthopedics, Sinhgad Dental College and Hospital, Sinhgad, Pune, Maharashtra, India.

## CASE REPORT

### EXTRA-ORAL EXAMINATION

A 13 year 4 month old male patient presented with the chief complaint of forwardly placed upper front teeth and a backwardly placed lower jaw. On Extraoral examination, the patient had a convex profile, grossly symmetrical face on both sides with a retruded chin, competent lips, deep mentolabial sulcus and an average Nasolabial Angle, a Mesoprosopic facial form, Dolicocephalic head form, Average width of nose and mouth, slightly upwardly tipped nose, minimal buccal corridor space, a consonant smile arc and posterior divergence of face. The patient had no relevant prenatal, natal, postnatal history, history of habits or a family history.

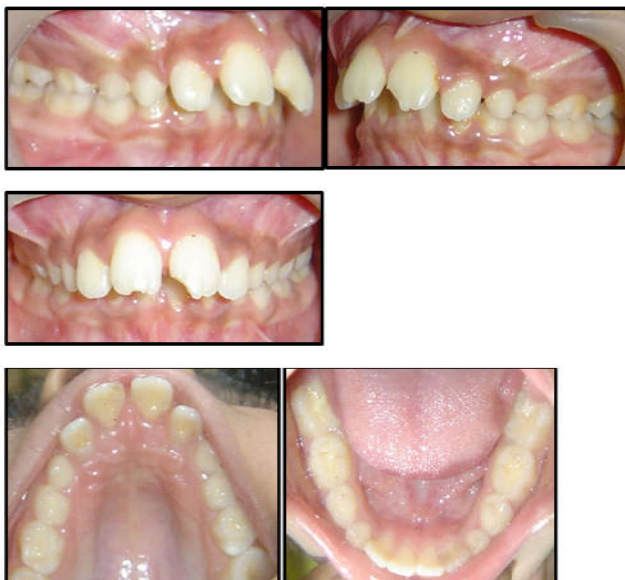### PRE TREATMENT EXTRAORAL PHOTOGRAPHS



### INTRA-ORAL EXAMINATION

Intraoral examination on frontal view shows presence of a deep overbite, on side views the patient shows the presence of Class II div 1 incisor relationship, an End on canine relationship on both sides and an end on molar relationship on both sides. Patient has an overjet of 8 mm and an overbite of 5mm. The upper and lower arch shows the presence of a U shaped arch form. OPG of the patient shows presence of all four 3rd molars in a developing stage. Hand wrist radiograph shows SMI stage 3.

### PRE TREATMENT INTRAORAL PHOTOGRAPHS



## PRE TREATMENT CEPHALOMETRIC READINGS

PARAMETERS	PRE- TREATMENT
SNA	82°
SNB	75°
ANB	7°
WITS	4mm
MAX. LENGTH	73mm
MAN. LENGTH	97mm
IMPA	105°
NASOLABIAL ANGLE	99°
U1 TO NA DEGREES	38°
U1 TO NA mm	10mm
L1 TO NB DEGREES	30°
L1 TO NB mm	8mm
U1/L1 ANGLE	110°
SADDLE ANGLE	129°
ARTICULAR ANGLE	152°
GONIAL ANGLE	140°
FMA	24°
Y AXIS	68°

- 1) Steiners analysis shows an average maxilla and a retrognathic mandible, Class II Skeletal pattern, an Average to Horizontal growth pattern, proclined maxillary and mandibular anteriors, forwardly placed maxillary and mandibular anteriors and protrusive upper and lower lips
- 2) Tweeds analysis shows a Horizontal growth pattern and proclined mandibular incisors
- 3) Wits appraisal shows AO ahead of BO by 4 mm indicating Skeletal Class II pattern
- 4) Ricketts analysis shows a retrognathic mandible, repositioned condyles and proclined mandibular anteriors
- 5) McNamara analysis shows a retrognathic maxilla, retrognathic mandible, a horizontal growth pattern, decreased lower anterior facial height and proclined mandibular incisors
- 6) Rakosi Jaraback analysis shows a Horizontal growth pattern and proclined maxillary and mandibular incisors
- 7) Hold away soft tissue analysis shows increased maxillary and mandibular sulcus depth and increased strain of lips
- 8) Downs analysis shows a retro positioned chin, a Class II Skeletal pattern, a horizontal growth pattern and proclined maxillary and mandibular anterior teeth

### MODEL ANALYSIS

#### Bolton ratio:-

Mandibular anterior excess:- 3.4 mm

Mandibular Overall excess:- 0.7 mm

#### Arch Perimeter Analysis :

Indicates need to extract second premolars

#### Ashley Howe's index:-

Borderline case for extraction

#### Careys Analysis :

Indicates need for proximal stripping

#### Pont's Index :

Expansion needed

#### Chadda's Index :

Expansion needed

### DIAGNOSIS

This 13 years 4 month old male patient was diagnosed with Angle's Class II div 1 malocclusion with an average maxilla, retrognathic mandible and a horizontal growth pattern, increased overjet and overbite, proclined upper and lower incisors, deep mentolabial sulcus and protrusive upper and lower lips

## TREATMENT OBJECTIVES

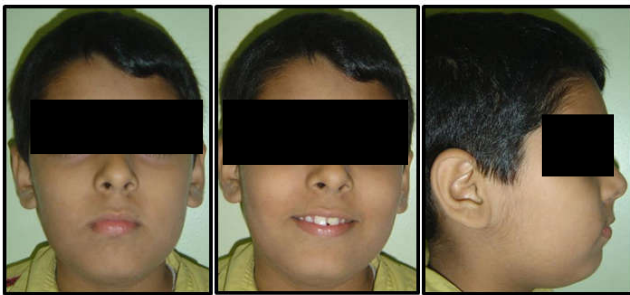
1. To correct mandibular retrognathism
2. To correct proclination of upper and lower anteriors
3. To correct overjet and overbite
4. To correct a deep mentolabial sulcus
5. To correct a deep curve of spee
6. To achieve a pleasing smile and a pleasing profile

## TREATMENT PLAN

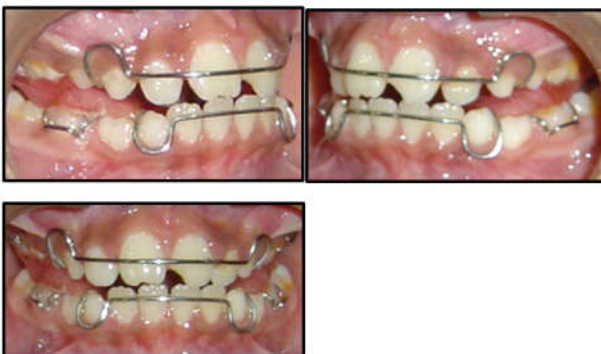- a) Myofunctional Therapy: Removable Twinblock appliance
- b) Appliance design:  
Sagittal advancement: 7 mm  
Vertical opening: 4 mm

**TREATMENT:** The treatment plan followed 2 phases of orthopedic and orthodontic correction. 1st phase involved correction of Sagittal discrepancy using Twinblock functional appliance therapy. The appliance used was a standard Clarks original Twinblock with a sagittal advancement of 7mm and a vertical opening of 4 mm. The 2nd phase of treatment involved fixed orthodontic treatment with MBT 0.022 inch slot.

## TWINBLOCK APPLIANCE DELIVERY EXTRAORAL PHOTOGRAPHS



## TWINBLOCK APPLIANCE DELIVERY INTRAORAL PHOTOGRAPHS

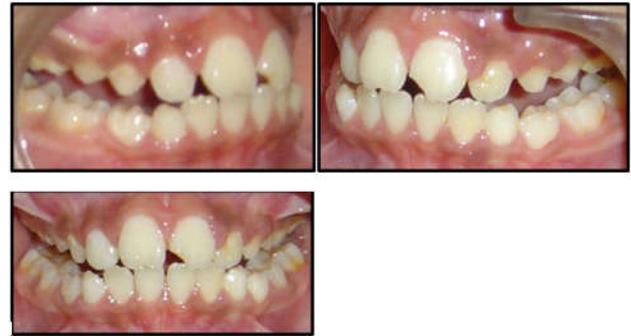

## TREATMENT PROGRESS

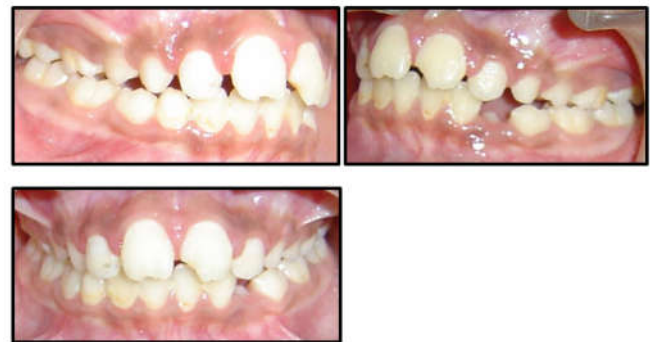Construction bite of the patient was registered by training the patient to bite in the desired anterior position which corrected the profile and enabled a class I molar relation bilaterally. Construction bite was taken with 7mm advancement and 4 mm opening. Clarks Twinblock was fabricated and appliance was delivered to the patient and proper post appliance delivery instructions were given. Follow ups were carried out regularly. Pterygoid response was observed in the patient within 28 days

of delivery of the appliance. Trimming of the appliance was done in an occlusolingival direction at an interval of 3 weeks. Sagittal correction into a class I molar relation was achieved in 8 months. Mid treatment changes after appliance trimming show the presence of a lateral open bite bilaterally.

## MID TREATMENT CHANGES BEFORE APPLIANCE TRIMMING



## MID TREATMENT CHANGES AFTER APPLIANCE TRIMMING



## DISCUSSION

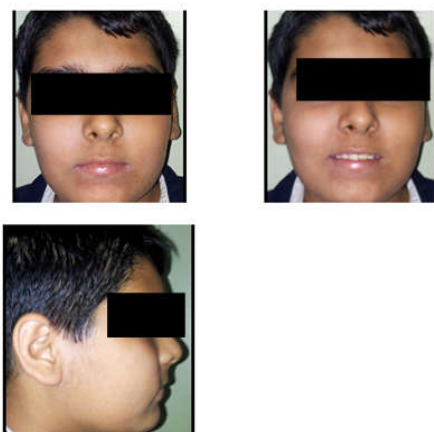Twin block functional appliance has several well established advantages including the fact that it is well tolerated by patients and it can be used in the mixed and permanent dentition. There are potential disadvantages such as the proclination of the lower incisors and development of posterior open bites. In this case, the treatment objectives were achieved largely due to good patient compliance. The patient's chief complaint was forwardly placed upper front teeth and a backwardly placed lower jaw. The selection of functional appliances is dependent upon several factors which can be categorized into patient factors, such as age and compliance, and clinical factors, such as preference/familiarity and laboratory facilities. The myofunctional therapy resulted in an improvement in the patient's profile, which is largely attributed to the favorable growth and partly to the functional appliance. It has been proved in the literature that functional appliances do not produce long-term skeletal changes and most of their effects are dentoalveolar. In a prospective controlled trial with twin blocks and controls to investigate the skeletal and dental effects showed that the ANB angle reduced by 2°, which was almost entirely due to mandibular length increase which was 2.4 mm compared to the controls as measured from Ar-Pog. There was no evidence of a restriction in maxillary growth. Successful results were obtained after the myofunctional therapy within 8 months of time. After this active treatment phase, the profile of this 13 year old growing male patient

improved significantly as seen in the post treatment Extra oral photographs

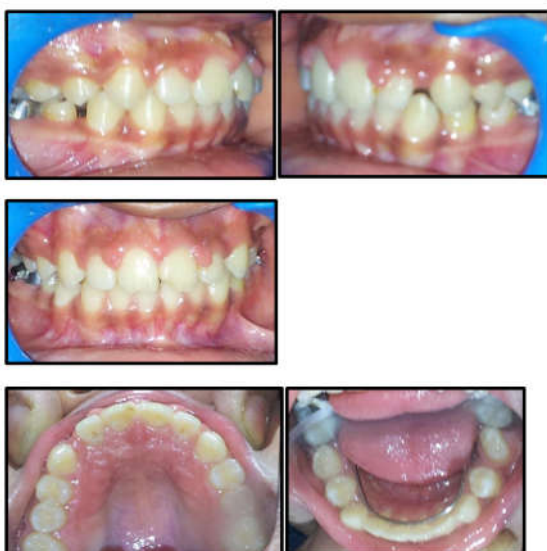**POST TREATMENT CEPHALOMETRIC READINGS**

PARAMETERS	POST-TREATMENT
SNA	81°
SNB	80°
ANB	1°
WITS	1mm
MAX. LENGTH	74mm
MAN. LENGTH	102mm
IMPA	96°
NASOLABIAL ANGLE	102°
U1 TO NA DEGREES	28°
U1 TO NA mm	2mm
L1 TO NB DEGREES	22°
L1 TO NB mm	2mm
U1/L1 ANGLE	132°
SADDLE ANGLE	124°
ARTICULAR ANGLE	144°
GONIAL ANGLE	129°
FMA	25°
Y AXIS	69°

**POST TREATMENT EXTRAORAL PHOTOGRAPHS**



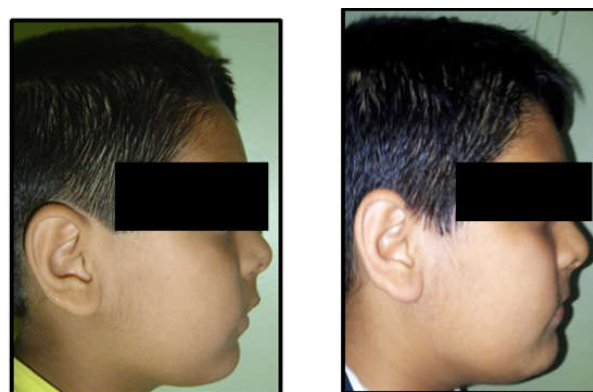**POST TREATMENT INTRAORAL PHOTOGRAPHS**



**COMPARISON OF PRE AND POST TREATMENT CEPHALOMETRIC READINGS**

Parameters	Pre- Treatment	Post-Treatment
SNA	82°	81°
SNB	75°	80°
ANB	7°	1°
WITS	4mm	1mm
MAX. LENGTH	73mm	74mm
MAN. LENGTH	97mm	102mm
IMPA	105°	96°
NASOLABIAL ANGLE	99°	102°
U1 TO NA DEGREES	38°	28°
U1 TO NA mm	10mm	2mm
L1 TO NB DEGREES	30°	22°
L1 TO NB mm	8mm	2mm
U1/L1 ANGLE	110°	132°
SADDLE ANGLE	129°	124°
ARTICULAR ANGLE	152°	144°
GONIAL ANGLE	140°	129°
FMA	24°	25°
Y AXIS	68°	69°

**PROFILE CHANGES PRE AND POST TREATMENT**



**CONCLUSION**

The effect of twin block functional appliances is mostly dentoalveolar with small skeletal component. However, there are a number of situations where functional appliances can be successfully used to correct Class II malocclusion. Clinically significant restraint of maxillary growth was not found. Although the mandibular body length is increased, the facial impact of it is reduced by the simultaneous increment of the face height. It is important that functional appliances are used in a growing patient to achieve the maximum benefit. They simplify the following phase of fixed appliance by gaining anchorage and achieving Class I molar relationship. In this case, the patient was treated with twin block appliance followed by fixed appliance phase.

**REFERENCES**

1. Clark WJ. 1988. The Twin Block technique. A functional orthopaedic appliance system. *Am J Orthod Dentofac Orthop.*, 93:1-18.
2. Graber TM, Rakosi T, Petrovic A. Dentofacial orthopedics with functional appliances. 2nd ed. St Louis: Mosby; 1997. Brien. The effectiveness of treatment of class II malocclusion with the Twin Block appliance: A randomised, controlled trial. *Am J Orthod Dentofac Orthop* 2003;124:128-37.
3. Brien. The effectiveness of treatment of class II malocclusion with the Twin Block appliance: A

- randomised, controlled trial. Part 2: Psychological effects. *Am J Orthod Dentofac Orthop* 2003;124:488
4. Mills JR. The effect of functional appliances on the skeletal pattern. *Br J Orthod* 1991;18:267-75.
  5. Singh GD, Hodge MR. Bimaxillary morphometry of patients with Class II division 1 malocclusion treated with twin block appliances. *Angle Orthod* 2002;72:402-9.
  6. Harradine N, Gale D. The effects of torquing spurs in Clark Twin Block appliances. *Clin Ortho Res* 2000;3:202-10.
  7. Lee RT, Kyi CS, Mack GJ. A controlled clinical trial of the effects of the Twin Block and Dynamax appliances on the hard and soft tissues. *Eur J Ortho* 2007;29:272-82
  8. Lund DI, Sandler PJ. The effect of Twin Blocks: A prospective controlled study. *Am J Orthod Dentofac Orthop* 1998;13:104-10.
  9. Hichens L, Rowland H, Williams A, Hollinghurst E, Ewings P, Clark S, et al. Cost-effectiveness and patient satisfaction: Hawley and vacuum-formed retainers. *Eur J Orthod* 2007;29:372-8.
  10. Little RM. Stability and relapse of mandibular anterior alignment: University of Washington studies. *Semin Orthod* 1999;5:191-204.
  11. Chadwick SM, Banks P, Wright JL. The use of myofunctional appliances in the UK: A survey of British orthodontists. *Dent Update* 1998; 25:302-8.
  12. Petrovic AG, Stutzmann JJ, Gasson N. The final length of the mandible: Is it genetically determined? In: Carlson DS, editors. *Craniofacial Biology. Monograph No. 10*. Ann Arbor: Center for Human Growth and Development, University of Michigan; 1981. p. 105-26.
  13. Sharma NS. Management of growing skeletal class II patient: A case report. *Int J Clin Paediatr Dent* 2013; 6:48-54.
  14. Clark WJ. The twin block traction technique. *Eur J Orthod* 1982; 4:129-38.
  15. Al-Anezi SA. Class II malocclusion treatment using combined Twin Block and fixed orthodontic appliances - A case report. *Saudi Dent J* 2011; 23:43-51.
  16. Trenouth MJ. A comparison of twin block, Andresen and removable appliances in the treatment of Class II Division 1 malocclusion. *Funct Orthod* 1992; 9:26-31.
  17. Trenouth MJ. Cephalometric evaluation of the Twin-block appliance in the treatment of Class II Division 1 malocclusion with matched normative growth data. *Am J Orthod Dentofacial Orthop* 2000; 117:54-9?

\*\*\*\*\*