



ISSN: 0975-833X

Available online at <http://www.journalcra.com>

INTERNATIONAL JOURNAL
OF CURRENT RESEARCH

International Journal of Current Research
Vol. 12, Issue, 08, pp.13293-13296, August, 2020

DOI: <https://doi.org/10.24941/ijcr.38993.08.2020>

RESEARCH ARTICLE

EFFICACY OF 2.5MM STAINLESS STEEL MINI-PLATE VERSUS STAINLESS STEEL LAG SCREW IN ANTERIOR MANDIBULAR FRACTURES- A COMPARATIVE EVALUATION

*Dr. Divyachampa D. N. Khaunte and Dr. Kiran Gadre

Bharati Dental College & Hospital, Pune, Maharashtra

ARTICLE INFO

Article History:

Received 05th May, 2020
Received in revised form
27th June, 2020
Accepted 14th July, 2020
Published online 30th August, 2020

Key Words:

Anterior Mandibular fractures, Lag screw, Miniplates, True Occlusal Radiograph, Orthopantomogram.

ABSTRACT

Background: Anterior mandibular fractures are common entity in maxillofacial trauma with average incidence of 17%. The unique anatomy of mandible along with vector forces exerted by muscles separates the inferior border of mandible making these fractures problematic. **Aim:** To compare and evaluate use of 2.5mm stainless steel single lag screw with 2.5mm single miniplate (6-hole with gap) for non-communitated anterior mandibular fractures **Objective:** 1. Evaluation of efficacy of lag screw as compared to miniplate, 2. Evaluation of intra-operative/post-operative complications, 3. Comparison of ease of placement of hardware, 4. Radiological evaluation of adequacy of fracture reduction **Method:** All patients were operated at an institute in Pune from 2012-2014. They were divided in two groups- Group S (2.5mm suitable length lag screw) and group P (2.5mm 6-hole with gap miniplate with 6 bicortical screws). Arch bar was spanned at upper border in both the groups. Standard pre-operative clinical and radiological evaluation-orthopantomogram for supero-inferior and true occlusal for antero-posterior displacement was done. Post-operative assessment was done for correctness of implant position, adequacy of fracture reduction, and evidence of infection, relation of hardware to vital structures, occlusion, wound healing & vitality of teeth on 7th day, one month & 3 months interval. **Results:** Male predominance with mean age of 25 years was noted in sample group. Wound dehiscence of less than 3cms in two patients, infection in one patient were noticed in group P which were statistically insignificant. Mean time required for procedure in group S was 78.4min while in group P was 75.3 min. Inter-maxillary fixation post-surgery was required in two patients in group P. Seven patients in group S had reduction of fracture segment less than 0.5mm as compared to four in group P. **Conclusion:** Minimum difference was noted in time required for procedure and adequacy of reduction which were in favour of group S over group P.

Copyright © 2020, Divyachampa et al. This is an open access article distributed under the Creative Commons Attribution License, which permits unrestricted use, distribution, and reproduction in any medium, provided the original work is properly cited.

Citation: Dr. Divyachampa D. N. Khaunte and Dr. Kiran Gadre. 2020. "Efficacy of 2.5mm stainless steel mini-plate versus stainless steel lag screw in anterior mandibular fractures- a comparative evaluation", *International Journal of Current Research*, 12, (08), 13293-13296.

INTRODUCTION

Maxillofacial surgeons operating facial trauma have known that, fractures of the anterior mandible are common entity. Wide variance has been reported in incidence of fracture of the anterior mandible (9-57 %), with average incidence of 17 % of all mandibular fractures (Matthew, 2008; Agnihotri, 2014). The fixation of mandibular fractures has visited different concepts and evolved based on the needs of the patient and understanding of principles of biomechanics and fixation with scientific advances in materials and instrumentations. The bone at the fracture site retains ability to take the compressive tasks and open reduction & internal fixation (ORIF) substitutes for lost tensile properties (Deepak, 2011). The unique anatomy of mandible with vector forces exerted by the temporalis and

masseter muscles, makes fractures of anterior mandible particularly problematic. These vector forces separate the inferior border of mandible at the site of the fracture (Thalita Regina Vieira e Oliveira, 2011). The fractures in the anterior mandible are readily treated by either application of bone plates and/or bone screws. Ellis et al (1990) stated that due to its unique anatomy; anterior mandibular region lends itself to stabilization of the fracture by compression with lag screws. Miniplates are based on principle of bridging the fracture site so that the continuity of the fracture fragments is maintained with two screws on either sides 5 mm away from the fracture line and allowing at the most micro-movements at the fracture site. Finally, the selection of one technique over other is based on surgeon preference, experience and availability of internal fixation hardware (Edward, 2011; Aditi Bhatnagar, 2013). In this study, we compared both the type of internal fixation i.e. lag screw versus miniplate to evaluate the better method of fixation with minimal implanted material to minimise post-operative complications.

*Corresponding author: Dr. Divyachampa D. N. Khaunte, Bharati Dental College & Hospital, Pune, Maharashtra.

MATERIAL AND METHODS

This was a prospective study done at an Institution in Pune, Maharashtra from 2012-2014. Ethical clearance was obtained for this study as per protocol. This study adhered to the Helsinki declaration for human trial with consented subjects. The study included detailed clinical and radiological assessment of 20 patients of isolated anterior mandibular fractures treated by ORIF with 10 patients being assigned randomly to each group i.e. Plate group & Screw group. Group P (Plate group) was where 2.5 mm 6-hole plate with 6 compatible/suitable screws was used at lower border with arch bar spanning at superior border (Figure 1) and Group S (Lag screw group) where 2.5mm screw of suitable length was used at lower border with arch bar spanning at superior border of fracture site (Figure 2). The patients above 18 years of age of both sexes with isolated anterior mandibular fractures between mental foramina with adequate number of teeth, healthy patients with no known allergies (ASA I/II) were included in the study. Patients with any other associated facial fractures, edentulous patients, head injury patients, with known systemic conditions were excluded from the study. Uniformity in data collection were followed with standardised case history format, standardised imaging studies, pre-operative antibiotic cover with oral hygiene and standardised implants were used.

All patients were advised Orthopantomogram (OPG) to note down the supero-inferior displacement in the fracture fragments and Occlusal radiograph to note down the antero-posterior displacement in the fracture fragments. The displacement was measured with measuring gauge (1/10mm) {manufactured by Medis}. Detailed Informed written consent was taken from every patient participating in the study after explaining the procedure. We followed a standardised operating protocol, with first bridal wire to align the fragments and 26gauge Erich's arch bar placed in upper & lower arches pre-operatively. Intra-operatively, Semi Rigid fixation was done at lower border with transosseous wiring followed by Rigid fixation with 2.5mm lag screw with suitable washer/miniplate with removal of transosseous wiring.

Post-operatively, Arch bar was removed 3 weeks after fixation. Patients were reviewed on weekly basis. Occlusion, Wound healing, Teeth vitality, Correctness of implant position, Adequacy of reduction, Evidence of infection, Non-union, Mal-union, Relation of hardware to nerve & teeth were checked post operatively by clinical & radiological evaluation with OPG+ Occlusal on 7th day, 1 month & 3 months. Soft diet was advised for two weeks with meticulous maintenance of oral hygiene (Figure 3 & 4). Efficacy of both groups were assessed on following parameters; age of patient, gender, etiological factors, socio-economic strata, time required from incision till suturing (total operative time), Presence/absence of post-operative infection, Healing at the end of 10 days, Neuro-sensory evaluation (Mental nerve-sensory evaluation) by pin-prick method/ 26gauge needle on three pre-determined points (Table1). Occlusion with articulating paper for occlusal interference, X-ray evaluation on pre & post-operative OPG and occlusal radiograph measured with depth gauge for adequacy of reduction, Hardware breakage drill/implants, Inter-incisal opening (IIO) post-operatively.

RESULTS

The mean age of patients in this study is 25.2 years for group P while 25.4 years for group S. The ratio of male to female in our study was 9:1 in both the groups. RTA was the most common etiological factor with 7 cases in group P and 6 cases in group S. The patient's families were more from socio-economic strata with income between 10,000-20,000/month while 6 patients had income less than 10,000/month and 4 had income more than 20,000/month. The mean time required for the procedure from incision till suturing was 79.4 minutes in group P and 74 minutes in group S. No case of dehiscence more than 3cms was observed in either of the groups. Two cases from group P showed dehiscence less than 3cms while all others in both groups had complete mucosal healing. Only 1 case of infection noted in group P while none in group S. No hardware breakage was observed in both groups (drill/lag screw). Only two cases and one case had discrepancy which required MMF in group P and group S respectively. None of the patient required any re-surgical procedure. Temporary mental nerve paraesthesia was observed in both groups for 1 month but none got permanent neuro-sensory deficit. Supero-inferior displacement of the fractures were noted pre-operatively and post-operatively at 7th, 30th and 90th days with measuring gauge (1/10mm) on OPG and antero-posterior displacement of the fractures at 7th, 30th and 90th days with measuring gauge (1/10mm) on occlusal radiograph (Table 2 & 3).

The statistical evaluation was done with standard deviation with level of significance set at $p < 0.05$ along with frequency analysis. Statistically significant difference was noted in time required for the procedure and adequacy of reduction on OPG in screw group.

DISCUSSION

Symphysis region of mandible presents with one of the highest negative bending movements compared to other regions, generating stress at inferior edge and compression at superior edge (Deepak, 2011). The lag screw technique has added advantage over miniplate osteosynthesis as it provides primary bone healing with compression, reduces hardware, healing time and cost. Edward Ellis compared lag screw versus mini plates in anterior mandibular fractures and found dehiscence of the wound more in plate group which were attributed to poor closure, smoking, trauma and infection. In our study also we found dehiscence of less than 3 cms in two cases of plate group and none in screw group which is not statistically significant and could be attributed to small sample size. No exposure of hardware in lagscrew group could be due to internal position of the hardware which allowed better adaptation of soft tissue and is in accordance with study by A. Agnihotri et al. (2014).

We included socio-economic condition of the patient in criteria as we most often dealt with people from lower socio-economic strata and thus the selection of type and nature of implant became important. With the use of titanium implants and imported implants the cost difference is significant as compared to stainless steel miniplates & screws. We used stainless steel implants in our study as chances of shearing and breakage of titanium lag screws is higher as discussed by Deepak et al⁸ where they observed shearing and fracture of titanium screws in almost 20 % of patients treated for mandibular fractures.

Table 1

POINT	RAMI OF THE MENTAL NERVE	LOCATION
1	Labial inferior rami	A third of the distance between the oral angles on the vermillion border.
2	Oral angular rami	5mm below the oral angle
3	Mental rami	Midpoint of the perpendicular line from point 1 to the lower extremity of the mentum.

Table 2

	Group	N	Mean	Std. Deviation	T
Pre-op	P	10	6	1.63	1.76 (NS)
	S	10	4.9	1.10	
Post_7	P	10	0.80	0.30	2.423*
	S	10	0.50	0.24	
Post_30	P	10	0.80	0.30	2.423*
	S	10	0.50	0.24	
Post_90	P	10	0.80	0.30	2.423*
	S	10	0.50	0.24	

Table 3

	Group	N	Mean	Std. Deviation	T
Pre_op	P	10	6.3	1.70	.91 (NS)*
	S	10	5.5	2.17	
Post_7	P	10	.6	.27	1.07 (NS)*
	S	10	.49	.17	
Post_30	P	10	.6	.27	1.07 (NS)*
	S	10	.49	.17	
Post_90	P	10	.6	.27	1.07 (NS)*
	S	10	.49	.17	

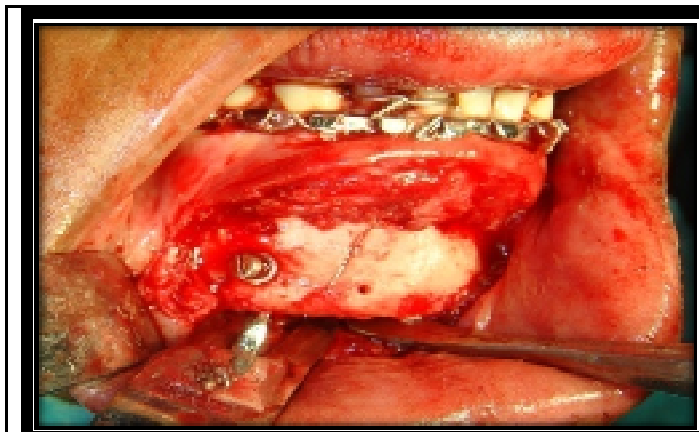


Figure 1

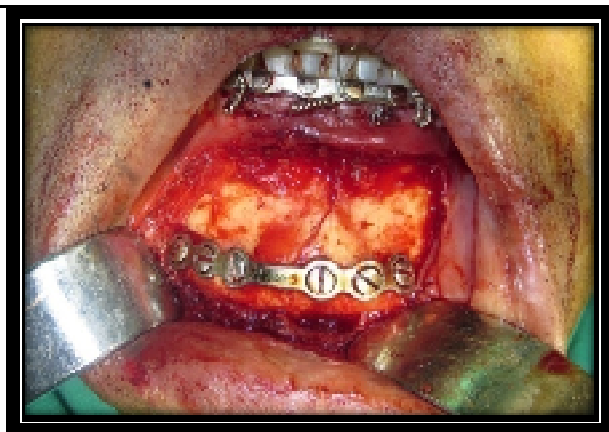


Figure 2

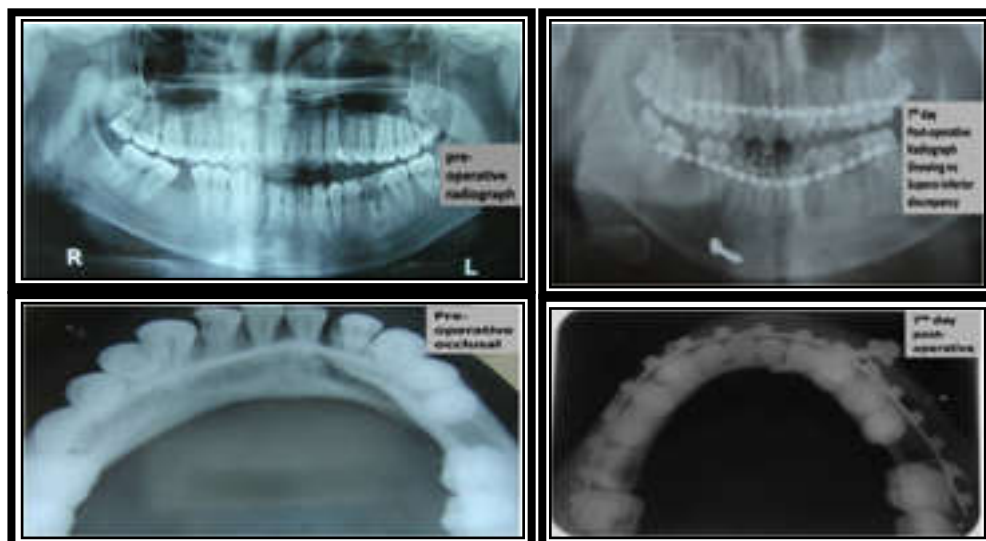


Figure 3

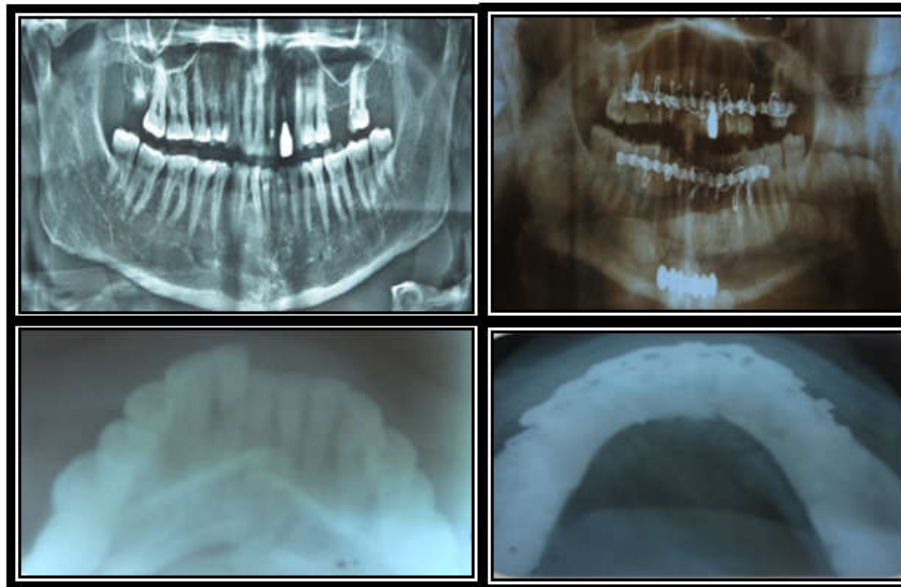


Figure 4

In our study, time required for procedure from incision till suturing was statistically significant. The mean duration of time required was 78.4 min and 75.3 min in plate and screw group respectively. In accordance with our study, Ellis and Ghali et al. (1990) also concluded that the time required for LSF is less as the procedure is relatively quicker and the time-consuming task of plate bending and adaptation is avoided. Following ORIF, Post-operative MMF was required in 2 patients of plate group which could be attributed to difficult nature of fracture. In his study, Edward Ellis noted that displacement of bony fragments was more common during bone plate placement as adequacy of plate contouring was not known unless screws were inserted whereas displacement was minimal with LSF.⁰⁹ Mal-occlusion was minor and managed by elastics for 2 weeks post-operatively. We compared adequacy of reduction radiographically on OPG and Occlusal (pre and post-operatively) found that no statistical difference was noted between two groups on occlusal while statistical difference of 0.05 was noted on OPG for group P. Reduction achieved by lag screw was superior as seven cases had reduction gap less than 0.5mm while in plate group only 4 cases had reduction gap less than 0.5. Statistically insignificant data on occlusal x-ray could be attributed to smaller sample size, Inter-fragmentary gap was stable throughout 3 months follow up period and none of the patients reported with mobility of fracture fragments, non-union, mal-union. Champy et al reported an incidence of 0.5 % for delayed union and non-union in patients treated with small plate osteosynthesis¹. In our study three patients who required MMF also showed clinically stable union by 6 weeks.

Conclusion

All the basic criteria of anatomic reduction, functionally stable fixation, preservation of blood supply and early, active pain-free mobilization were met by both the techniques for osteosynthesis. Lag screw had added advantage of minimum implanted material and ability of inter-fragmentary compression. We found statistical difference between time required for procedure, IO and adequacy of reduction on OPG in favour of group S over group P whereas in rest parameters we couldn't and the reason for same most likely can be related to the small sample size in our study.

Thus, we recommend further studies with larger sample size for conclusive evidence on better method of fixation.

REFERENCES

- Champy M, Lodde JP, Schmitt R, Jaeger JH, Muster D, Mandibular osteosynthesis by miniature screwed plates via a buccal approach, *J Oral Maxillofac Surg*, 6: 14-21, 1978
- Edward Ellis III, A study of two bone plating methods for the fractures of the mandibular symphysis/body, *J Oral Maxillofac Surg* 69:1978-1987, 2011
- Edward Ellis III, G. E. Ghali, Lag screw fixation of anterior mandibular fractures, *J Oral Maxillofac Surgery*, 49:13-21, 1990
- Tams J, van loop JP, Rozema FR et al, A three-dimensional study of loads across the fracture for different fracture sites of the mandible, *Br J Oral Maxillofac Surg*, 34:400, 1996
- Paul S. Tiwana, George M. Kushner and Brian Alpert, Lag screw fixation of anterior mandibular fractures: A retrospective analysis of intra-operative and post-operative complications, *J Oral Maxillofac Surg*, 65:1180-1185, 2007
- Matthew J. Madsen, Christopher A. McDaniel, Richard H. Haug, A biomechanical evaluation of plating techniques used for reconstructing mandibular symphysis/parasymphysis fractures, *J Oral Maxillofac Surg* 66:2012-2019, 2008
- Thalita Regina Vieira e Oliveira, Luis Augusto Passeri, Mechanical evaluation of different techniques for symphysis fracture fixation- An in vitro polyurethane mandible study, *J Oral Maxillofac Surg* 69: e141- e146, 2011
- Deepak S, Manjula; Comparison of Titanium bone plates and screws vs. stainless steel bone plates and screws in the management of mandibular fractures – A long term clinical study, 2(3) August, 2011 *Int. Journal of Clinical Dental Science*, 2011
- Edward Ellis III, Is lag screw fixation superior to plate fixation to treat fractures of the mandibular symphysis? *J Oral Maxillofac Surg* 70: 875-882, 2012
- Aditi Bhatnagar, Vishal Bansal, Sanjeev Kumar, Aporva Mowar, Comparative analysis of osteosynthesis of mandibular anterior fractures following open reduction using stainless steel lag screws and miniplates., *J Maxillofac Oral Surg*. 2013 June; 12(2):133-139
- Agnihotri, S. Prabhu, S. Thomas A comparative analysis of the efficacy of cortical screws as lag screws and miniplates for internal fixation of mandibular symphyseal region fractures: a randomized prospective study. *Int. J. Oral Maxillofac. Surg.* 2014; 43: 22–28