



ISSN: 0975-833X

Available online at <http://www.journalcra.com>

International Journal of Current Research
Vol. 12, Issue, 10, pp.14153-14155, October, 2020

DOI: <https://doi.org/10.24941/ijcr.39947.10.2020>

INTERNATIONAL JOURNAL
OF CURRENT RESEARCH

RESEARCH ARTICLE

DISPARITY IN ANATOMY OF MANDIBULAR SECOND MOLAR: A CASE REPORT

Varnika Yadav^{1,*}, Praveen Singh Samant² and Vipul Srivastava³

MDS, Department Of Conservative Dentistry and Endodontics, Saraswati Dental College And Hospital, Lucknow¹
Professor & Head, Department Of Conservative Dentistry And Endodontics, Saraswati Dental College And Hospital, Lucknow²
Professor, Department Of Conservative Dentistry And Endodontics, Saraswati Dental College And Hospital, Lucknow³

ARTICLE INFO

Article History:

Received 09th July, 2020
Received in revised form
27th August, 2020
Accepted 14th September, 2020
Published online 30th October, 2020

Key Words:

Mandibular Second Molar, Root Canal Morphology, Single Canal, Single Root, Variations.

Copyright © 2020, Varnika Yadav et al. This is an open access article distributed under the Creative Commons Attribution License, which permits unrestricted use, distribution, and reproduction in any medium, provided the original work is properly cited.

Citation: Varnika Yadav, Praveen Singh Samant and Vipul Srivastava. 2020. "Disparity in anatomy of mandibular second molar: A case report.", *International Journal of Current Research*, 12, (10), 14153-14155.

ABSTRACT

Mandibular second molars are known to have high root canal complexity. Diagnosis and successful endodontic treatment is a challenge for multi-rooted teeth with complex root morphology. This case report represents a rare of mandibular second molar having variation in anatomy, having single root with single root canal. Proper radiographic and clinical interpretation is essential. Clinicians should be aware of disparity in root canal anatomy other than normal root canal morphology. Thus, the aim of this case report is to present an endodontic management of mandibular second molar having single root and single root canal.

INTRODUCTION

For the successful endodontic treatment thorough knowledge of dental anatomy is essential. Prior to the root canal treatment, clinicians required an insight about tooth morphology, shape, form and structure.¹ Main objective of endodontic treatment is to treat the endodontic disease successfully. High quality of chemo-mechanical cleaning and shaping are required to completely eliminate the microorganism from the complex root canal system.² Previously, it was described that teeth had simplified canals. Later in 1925, it became that teeth have complex root canals.³ Additional canals, lateral canals, bifurcation, canal ramifications, apical deltas are some variations which are frequently encountered during root canal therapy; clinical significance and incidence of these variations have been reported earlier.² Generally, mandibular second molars have two roots, mesial and distal.³ Four canals, two canals, taurodontism, e-shaped canals and one canal in single root are some other configurations that have been reported in mandibular second molar.² Weine et al. stated that percentage

of mandibular second molar having single canal configuration (orifice to apex) is 1.3%.⁴ Pretreatment periapical radiographs helps in assessing the curvature, number, length and aberrations of root canal of the tooth.¹ Digital radiography, micro-computed tomography, CBCT, dental operating microscope and improved obturation techniques are some devices which have contributed to efficient root canal treatment.² The purpose of this case report is to describe the diagnosis and management of rare root canal configuration, showing single conical root having single canal.

Case Report: 26 years old male patient reported to the Department of Conservative Dentistry and Endodontics with complained of pain in lower right back molar region since 2 months. The history revealed that the pain aggregates on food lodgment. There was no relevant medical history. No significant finding was there, on extra-oral examination. On intraoral examination, deep occlusal caries was seen in tooth 47. Tooth was not tender on percussion and palpation. Radiographic examination revealed the radiolucent area involving enamel, dentin and pulp [Fig. 1]. The tooth showed positive vitality test for heat and cold. Hence, on the basis of above findings diagnosis of irreversible pulpitis was made for tooth 47.

*Corresponding author: Varnika Yadav,
MDS, Department Of Conservative Dentistry and Endodontics,
Saraswati Dental College And Hospital, Lucknow.

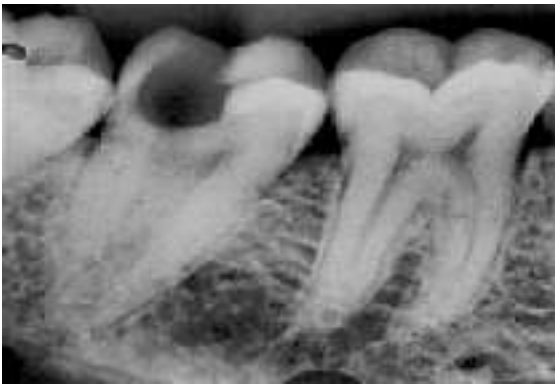


Figure 1. Pre-operative radiograph of tooth showing radiolucency involving enamel, dentin and pulp #47.

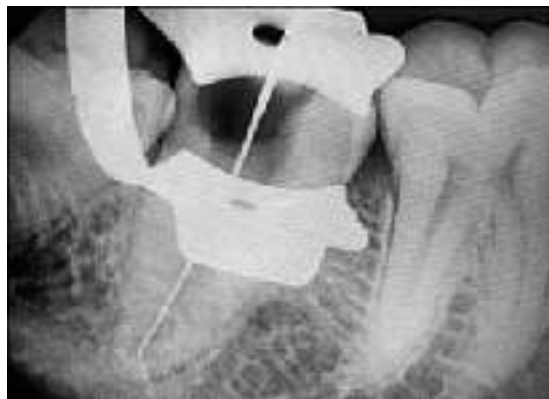

Figure 2. Radiograph of working length #47.

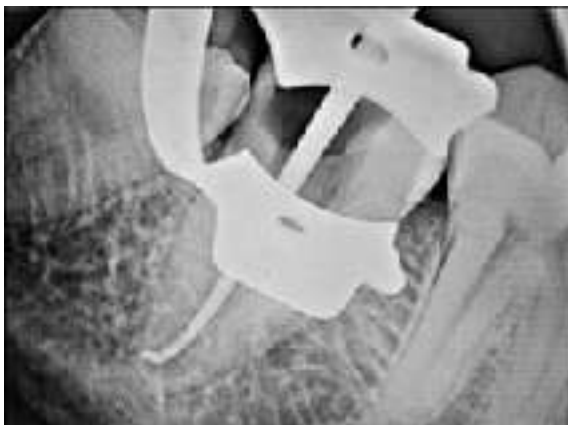

Figure 3: Radiograph of master cone #47.

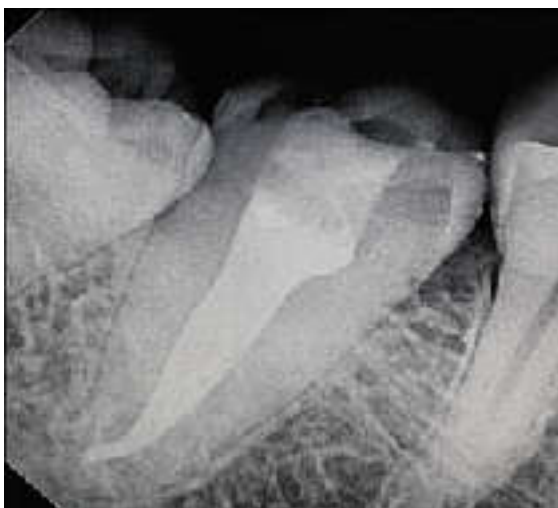

Figure 4. Radiograph showing obturation #47.

Local anesthesia was administered and access was prepared under rubber dam. A huge canal orifice was present at the middle of tooth revealing the pulp chamber. The working length was determined using apex locator and conventional radiograph, after the pulp extirpation [Fig.2]. The cleaning and shaping of the canal was done and then canal was irrigated with sodium hypochlorite 5.25%, EDTA 17% and normal saline. Master cone radiograph was taken [Fig.3]. Sterile absorbent paper points were used to dry the canal. AH plus sealer was evenly applied in the canal using lentulo spiral. Obturation was done using cold lateral compaction technique and post-endodontic restoration was done with composite resin [Fig.4].

DISCUSSION

The study of the root canal morphology has an endodontic importance. Variations in the root canal anatomy are not uncommon like number of roots and number of root canals. Generally, two roots with three root canals are observed in the mandibular second molars.³ Therefore, for diagnosis and successful endodontic treatment especially in multi-rooted teeth thorough understanding of root canal morphology is very important. Failure of the root canal treatment can occur due to the extra or hidden canals. Apical deltas, extra canals, canal ramification, etc are frequently come across. Moreover, their importance and prevalence is well registered in literature.⁵ Conical root, single root or c-shape form has prevalence of 21.8%. Dentists should have an understanding of the pulp chamber location and dimension; as in certain cases there might be cases there might be of occurrence of extra canal than normal expected canal.⁵ In permanent maxillary first, second and third molars, mandibular first and second premolars, mandibular first and second molar, c-shaped canals are commonly found.³

Spiral CT was used to spot the presence of single root with single root canal in maxillary first molar by Gopi Krishna et al.⁶ Slowly et al. reported that there are 14% chances for presence of single canal in mesial root of mandibular first molar.⁷ Fava et al. reported that in same patient, all mandibular second molars have single root with single root canal.⁸ Mashyakhly et al. reported that in Saudi Arabian population, in the same person the bilateral symmetry of number of root is 100% and number of canals is 56%.⁹ Evaluation of pre-operative radiograph helps in diagnosis of anatomical variations, c-shaped canal usually have fused root with a longitudinal groove in the center of the root.¹ Cone Beam Computed Tomography is an authentic method that can be used for the diagnosis and treatment plan for endodontic cases, especially in cases where bucco-lingual dimension is required and angled radiograph fails to provide conclusive information.² In this case of mandibular second molar, the presence of single conical root with single root canal was evaluated with the help of angle radiographs. Further, after access cavity preparation the broad single oval canal orifice was suggestive of presence of one canal and the pulp chamber exploration didn't revealed any extra or hidden canals. Endodontic loupes were also helpful in managing the complexity of canal.

Conclusion

For successful endodontic treatment proper cleaning and shaping is required. For cleaning and shaping complete

knowledge of root canal morphology is must. When atypical anatomic form come across, careful interpretation using angled radiographs, proper access cavity preparation and exploration of pulp chamber under the magnification will help in revealing the unusual complexity of the root canal system.

Conflict of interest: Nil

Source of funding: Nil

REFERENCES

1. Sujit R and Kiranmurthy D. Mandibular second molar with single root single canal: A case report. *International Journal of Contemporary Dentistry* 2011;2(5):140-142.
2. Alfadley A, Alquraishi A, Almarzrou Y, Aljarbou F. A rare case of single rooted mandibular second molar with single canal. *Case Reports in Dentistry*. 2020 Jun 15;2020.
3. Acharya S. Single canal in a single-rooted mandibular second molar: An enigma. *Saint Int Dent J* 2016;2:50-2.
4. Weine FS, Pasiewicz RA, Rice RT. Canal configuration of the mandibular second molar using a clinically oriented in vitro method. *J Endod*. 1988;14(5):207-13.
5. Roy A, Velmurugan N, Suresh N, Mandibular second molar with a single root and a single canal: Case series. *JCDR*. 2013;7:2637-38.
6. Gopikrishna V, Bhargavi N, Kandaswamy D. Endodontic management of a maxillary first molar with a single root and a single canal diagnosed with the aid of spiral CT: A case report. *J Endod*. 2006; 32(7): 687-91.
7. Slowey RR. Root canal anatomy. Road map to successful endodontics. *Dent Clin North Am*. 1979; 23: 555-73.
8. Fava LR, Weinfield I, Pais CR. Four second molars with single roots and single canals in the same patient. *Int Endod J*. 2000; 33(2): 138-42.
9. Mashyakhly M, Chourasia HR, Halboub E, Almashraqi AA, Khubrani Y, Gambarini G. Anatomical variations and bilateral symmetry of roots and root canal system of mandibular first permanent molars in Saudi Arabian population utilizing cone-beam computed tomography. *Saudi Dent J* 2019;31(4):481-486.
