



ISSN: 0975-833X

Available online at <http://www.journalcra.com>

International Journal of Current Research
Vol. 12, Issue, 12, pp.15142-15146, December, 2020

DOI: <https://doi.org/10.24941/ijcr.40461.12.2020>

INTERNATIONAL JOURNAL
OF CURRENT RESEARCH

RESEARCH ARTICLE

ASSESSMENT OF TRANSVERSE ASYMMETRY IN UNILATERAL PALATAL CANINE IMPACTION, WHEN COMPARED WITH CONTRALATERAL NON IMPACTED SIDE: A POSTEROANTERIOR CEPHALOMETRIC EVALUATION

Dr. Sheikh Zahid Nazir^{1,*}, Dr. Mohammad Mushtaq², Dr Mariya Qadir³

¹Resident, Department of Orthodontics and Dentofacial Orthopaedics, Government Dental College and Hospital, Srinagar, J&K, India

²Professor and Head of Department (BDS, MDS, PGDHM), Department of Orthodontics and Dentofacial Orthopaedics, Government Dental College and Hospital, Srinagar, J&K, India

³Resident, Department of Orthodontics and Dentofacial Orthopaedics, Government Dental College and Hospital, Srinagar, J&K, India

ARTICLE INFO

Article History:

Received 30th September, 2020
Received in revised form
27th October, 2020
Accepted 25th November, 2020
Published online 30th December, 2020

Key Words:

Canine Impaction,
Palatally Displaced Canines,
Posteroanterior Cephalometrics.

*Corresponding author:

Copyright © 2020, Sheikh Zahid Nazir et al. This is an open access article distributed under the Creative Commons Attribution License, which permits unrestricted use, distribution, and reproduction in any medium, provided the original work is properly cited.

Citation: Dr. Sheikh Zahid Nazir, Dr. Mohammad Mushtaq, Dr Mariya Qadir. 2020. "Assessment of Transverse Asymmetry in Unilateral Palatal Canine Impaction, when Compared with Contralateral Non Impacted Side: A Posteroanterior Cephalometric Evaluation", *International Journal of Current Research*, 12, (12), 15142-15146.

ABSTRACT

Background: Impaction of tooth is a retardation or halt in the normal process of eruption. After the third molar, maxillary canine is the most frequently impacted tooth in the dental arch. The treatment of impacted teeth has caught the imagination of many in dental profession. However, the orthodontic / surgical modality has achieved the most satisfactory result in long-term. **Aims and objectives:** This study was aimed to measure and compare the linear and angular measurements and to perform maxillomandibular asymmetry comparison in transverse dimensions on impaction side with contralateral non impacted side. **Materials and Methods:** A total sample of 30 subjects in different malocclusion groups with unilateral palatally impacted canines were included. The age groups 13–30 years were included with male and female subjects. The linear and angular parameters were measured and variation was studied and maxillomandibular asymmetry comparison was done on impaction side with contralateral non impacted side, mean values, SDs, and P values were calculated by applying descriptive statistics along with student's independent t-test by using statistical software SPSS (version 20.0) and Microsoft Excel. The level of significance was set at p value < 0.05. **Results:** Descriptive statistical analysis was first done to find out the mean of each linear and angular parameter along with standard deviation. Then comparison was made between the impaction side with contralateral non impacted side by using student's independent t-test. Statistically significant difference was found in nasal cavity width between two sides. The distance from the centre of the canine crowns to median sagittal plane and angulation of long axis of canine to Za-Za plane was also found statistically significant between two sides, and on doing the maxillomandibular comparison of asymmetry, no statistically significant difference was found. **Conclusions:** This study concluded that the distance of canines on the impaction side from mid sagittal plane are decreased and long axis of canines showed more obtuse angulation with respect to the selected plane and there was decreased nasal cavity width on impaction side when compared with contralateral non impacted side. No maxillomandibular asymmetry was present in subjects with unilateral palatal canine impaction.

INTRODUCTION

In pathological terms, impacted teeth can be defined as a state where a tooth remains embedded in the oral mucosa or bone past its normal eruption period. However, the clinical definition of impacted teeth can be broadened to include teeth that are predicted to undergo abnormal eruption, even before its normal eruption period, due to position of tooth germ, tooth shape, direction of eruption, and available space (Kim et al., 2012).

Permanent maxillary canines are the second most frequent impacted teeth after third molars with 2% prevalence rate in the general population since they have an extended development period deep in maxilla, have large root surface area to develop and a long tortuous path of eruption compared to other teeth (Bedoya, 2009). Also, existence of additional teeth in the eruption path is an important factor for delaying maxillary canines from eruption. Impacted canine in the palatal position occurs 3 to 6 times more often than buccal position (Walker, 2005; Sajjani et al., 2012).

Impacted canines are twice as common in women as in men, and the incidence in the maxilla is more than double compared to the mandible (Jacoby, 1983). Canines play an important functional and aesthetic role in face. Moreover orthodontics has emphasized the importance of preserving impacted maxillary canines and has introduced various effective techniques for the treatment of this condition (Bedoya, 2009). Research studies lack the characterization of alveolar bone dimensions and mechanical environment at the impacted site; while it may be hypothesized that impaction may lead to reduce masticatory stimulation of the bone. With the advent of cone-beam computed tomography (CBCT), more specifically, by rendering three-dimensional (3D) views of teeth and bone at high resolution, detailed characteristic of alveolar bone dimensions can be obtained at the impacted side (Mischkowski, 2007; Timock et al., 2011).

Forced orthodontic eruption of teeth results in adequate development of alveolar bone height (Hinds, 2004). Other treatment modalities (guided bone regeneration) to augment alveolar bone height have been less predictable (Simon et al., 2000; Zubillaga, 2003). Investigations pointed out a lack of the accurate characterization of alveolar bone dimensions and the environment in the affected area (Mischkowski et al., 2007; Timock, 2011). The impaction can lead to reduced bone dimensions, or affect dental angulations of the nearby teeth. There are a few studies (Tadinada, 2015; Kanavakis et al., 2015) comparing specifically the impacted area with the area that had adequate canine eruption in the same individual. These results indicate the consequences generated by the impaction of a canine. Kanavakis et al. 2015 concluded that the root of lateral incisors adjacent to palatal impacted canines is angulated more mesially compared to that of lateral incisors adjacent to normally erupted canines.

For orthodontics, one single CBCT scan can effectively generate all the images needed for orthodontic diagnosis including the lateral cephalogram, the panoramic radiograph, the antero-posterior cephalogram, temporo-mandibular joint tomograms, occlusograms and many other oblique/cross-sectional slices previously unavailable in flat planar films at a relatively equivalent radiation dose, for a set of orthodontic X-ray initial records. So, in our study the antero-posterior cephalograms were extracted from CBCT scan to evaluate the linear and angular asymmetry along with maxillomandibular comparison of asymmetry of impaction side with contralateral non impacted side in transverse dimensions.

Aims and objectives: The purpose of this study was to compare the linear and angular dimensions in a sample with unilateral palatally impacted canines between impacted side and unaffected side and to analyse the characteristics of these dimensions and determine how they influence the impacted canines on transverse measurements and to evaluate any maxillomandibular asymmetry.

MATERIALS AND METHODS

The study was carried out on the patients undergoing fixed orthodontic treatment at Department of Orthodontics & Dentofacial Orthopaedics Government Dental College & Hospital, Shireen Bagh, Srinagar.

Inclusion criteria

-) Patients with a unilateral maxillary palatal canine impaction.
-) Patients more than 12 years of age.
-) Complete eruption of the contralateral canine, and
-) No prior orthodontic treatment.

Exclusion criteria

-) Patients with craniofacial anomalies and syndromes.
-) Cleft lip and cleft palate patients.
-) Cases with congenitally missing teeth.
-) CBCT scans showing supernumerary teeth, enlarged/cystic follicle, or any other pathology
-) History of facial trauma.
-) Previous history of orthodontic treatment.

The cephalometric analysis on PA films was the one proposed by Ricketts (Ricketts, 1998) with a modification that eliminated the mandibular measurements. Cephalometric variables were limited to transverse measurements because these are least affected by postural alterations of the head during radiographic registration. The following skeletal and dental landmarks and lines were used (Figure 1):

Cranial landmarks: Za (zygomatic arch), center of the zygomatic arch; Cg (crista galli), tip of the structure.

Maxillary landmarks: Nc (nasal cavity), most lateral margin of the nasal cavity; J (jugal process), crossing on the zygomatic process of the maxilla with the outline of the tuberosity; ANS (anterior nasal spine), center of the hard palate at the junction with the septum.

Dental landmarks: UI (upper interincisal point); A6L and A6R (upper molar left and right), the buccal most point on the crowns of the upper first molars; A3Lcc and A3Rcc (upper canine left/right crown center), defined as the intersection between the two maximal diameters of the canine crown.

Reference lines: Za-Za, frontal Frankfort plane; Cg-Vertical, a perpendicular line dropped through frontal Frankfort from crista galli, representing the midsagittal reference plane(MSR) Fig (1)

The following linear and angular measurements were performed: The distance of points Nc to MSR, J to MSR, ZA to MSR, A6L and A6R to MSR, A3Lcc and A3Rcc to MSR, was measured on both impacted and contralateral non impacted side from the median sagittal reference plane and the UI to MSR was measured to evaluate any deviation from MSR whether towards the impacted or non impacted side. The angular measurement was performed by measuring the A3L/R long axis to Za-Za angulation of the upper left/right canine to the frontal Frankfort plane. Maxillomandibular asymmetry comparison was done by drawing perpendiculars to MSR from J and GA, and connecting lines from Cg to J and GA. This produces two pairs of triangles, each pair bisected by MSR. If perfect symmetry is present, the four triangles become two, J-Cg-J' and AG-Cg-GA (Grummons, 1987).

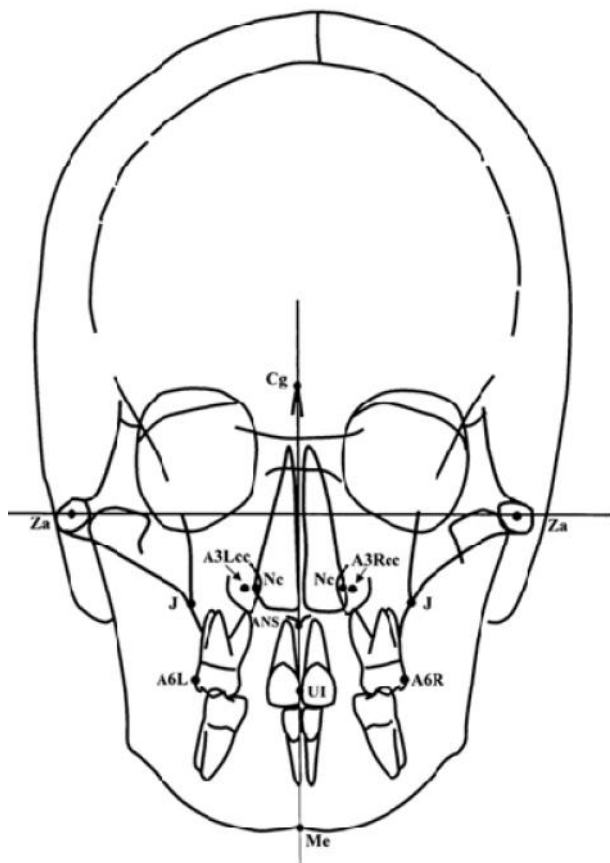


Fig (1)

Statistical analysis and Results

The recorded data was compiled and entered in a spreadsheet (Microsoft Excel) and then exported to data editor of SPSS Version 20.0 (SPSS Inc., Chicago, Illinois, USA). Statistical software SPSS (version 20.0) and Microsoft Excel were used to carry out the statistical analysis of data. Descriptive statistical analysis was first done and data were expressed as Mean \pm SD. Student's independent t-test was employed for the comparison of linear and angular measurements and maxillomandibular asymmetry comparison was done between impacted side and non impacted side.

A P-value of less than 0.05 was considered statistically significant. All P-values were two tailed. Statistically significant difference was found in nasal cavity width between two sides. The distance from the centre of the canine crowns to median sagittal plane and angulation of long axis of canine to Za-Za plane was also found statistically significant between two sides (Table 1) and on doing the maxillomandibular comparison of asymmetry, no statistically significant difference was found (Table 2).

DISCUSSION

In planning the surgical-orthodontic repositioning of malpositioned maxillary canines, correct diagnosis requires not only their precise location, but also a thorough and accurate assessment of their relationship with not only adjacent anatomical structures, but also in particular the roots of adjacent teeth (Preda *et al.*, 1997; Bodner, 1994; Schmuth, 1992). It appeared desirable, therefore, to identify a method that would provide the clinician with an earlier tool

for both the diagnosis of canine displacement and the prediction of subsequent canine impaction. The panoramic film has been used extensively for the identification of diagnostic parameters aimed at interceptive treatment planning (Ericson, 1987; Hurme, 1949; Ericson, 1988; Lindauer, 1992) but it unfortunately presents with considerable distortion in the frontal portion of the dentoalveolar regions.

Historically, a lack of interest and experience combined with difficulty in attaining consistent orientation of the head in the head holder at the time of exposure has limited the progress of the frontal analysis (Ricketts, 1972; Ricketts, 1960). On the contrary, when performed adequately, PA radiography is able to provide valuable information about the spatial characteristics of the dentoskeletal region. When the patient's head rests against the film, the frontal headfilm presents the anterior area of the face with a minimal amount of distortion. In the frontal headfilm it is easy to identify the position of the canine and its relationship with proximal teeth, the nasal cavity, and the palate. The aim of the present study was to identify predictive variables for canine impaction on the frontal headfilm in patients with unilateral palatal canine impaction. The existence of a normal maxillary arch width in cases with canine impaction had been pointed out by Langberg and Peck (Langberg, 2000).

From an etiological point of view the results of the present study, in addition to the ones by Langberg and Peck, (Langberg, 2000) confute the role of deficiency in maxillary width as a local mechanical cause of the palatally displaced canines. On the contrary, this theory had been supported by Mc-Connell *et al.* (1996) who used dental measurements to define transverse deficiency. The proposed method for early identification of subjects susceptible to canine impaction based on radiographic parameters might be complemented advantageously by the early recognition of morphological "risk signs" for canine impaction. It has been demonstrated that a series of concomitant tooth disturbances in the individual patient (small size of upper lateral incisors, enamel hypoplasia, aplasia of second premolars) can be regarded as factors for an increased prevalence rate of canine impaction (Baccetti, 1998; Peck, 2002; Baccetti, 1998; Leifert, 2003; Brenchley, 1997; Mossey, 1994; Oliver, 1989; Stahl, 2003; Svinhufvud *et al.*, 1988). Further, because of the additional radiation exposure, the use of the frontal X-ray could be recommended primarily in those subjects showing tooth anomalies that are recognized as associated with a higher prevalence of canine impaction.

From a clinical point of view the role of the prognosis of canine impaction represented by a deficiency in the distance between the crown of the canine and the midsagittal plane, in the absence of a deficiency in the posterior width of the maxilla, suggests the use of techniques to widen the anterior part of the maxilla without increasing the posterior part of the upper jaw, if not needed for other therapeutical purposes. Similarly in our study the distance from the centre of canine crown was decreased from mid sagittal plane on impaction side while as the distance from the buccal surfaces of both the molars from midsagittal plane was same on both sides which also suggests the use of techniques to widen the anterior part of maxilla rather than posterior part of maxilla if not necessary otherwise and the width of nasal cavity was

Table 1. Descriptive Statistics and Independent Sample t-Test of the two sides

| Variables | NIC side (n=30) | | IC side(n=30) | | Significance |
|--------------------------|-----------------|------|---------------|-------|--------------|
| | Mean | SD | Mean | SD | |
| Nc to MSR mm | 12.64 | .8 | 11.5 | 1.1 | * |
| J to MSR | 30.5 | 1.6 | 30.1 | 2.5 | NS |
| Za to MSR | 57.85 | 2.9 | 56.3 | 1.9 | NS |
| A6 to MSR | 48.2 | 2.4 | 47.8 | 1.9 | NS |
| U1 to MSR | -1.9 | 1.1 | 0.2 | 0.9 | NS |
| A3 to MSR | 13.8 | 1.2 | 10.7 | 1.4 | ** |
| A3 long axis to Za-Za(°) | 97 | 4.91 | 121.2 | 12.70 | *** |

NIC indicates nonimpaction canine; IC impaction canine; Nc: nasal cavity; J: jugal process; NS: not significant; and Za: Zygomatic arch; U1: upper interincisal point, A6: upper molar buccal most point, A3: crown centre of upper canine *P<0.05. * P<0.01. *** P<0.001.

Table 2. Maxillomandibular comparison of asymmetry

| Parameter | Description | Value |
|--|---|---|
| Cg-J-MSR(perpendicular to MSR through J on either side): Cg-AG-MSR(perpendicular to MSR through AG on either side) | This produces two pairs of triangles, each pair bisected by MSR | No asymmetry was present on impaction side versus non impaction side and the four triangles became two, J-Cg-J and AG-Cg-AG |

Cg: Crista galli; MSR: Median sagittal reference plane; Ag: Gonial point(AG: right, GA:left)

also decreased on the impaction side which again suggests anterior expansion. In our study, the angulation of canine was more obtuse on impaction side than contralateral side which also governs the prognosis of the impacted canine, greater is the angulation of the impacted canine, more horizontally it will be, more difficult it would be to bring it into the alignment without inadvertently touching the roots of adjacent teeth. While as the incisal point was also deviated towards the impaction side which should be taken into consideration for midline corrections while bringing canine into alignment. In our study both zygomatic arch and jugal process were at the same distance from the midsagittal plane and no significant difference was found in these skeletal parameters on impaction side versus contralateral non impacted side. On doing the maxillomandibular asymmetry evaluation, no asymmetry was found in our study in patients with unilateral palatally impacted canine. So during diagnosis all these radiographic parameters should be evaluated for prognosis in order to achieve successful treatment outcomes.

Conclusion

Unilateral palatally impacted maxillary canines represent an asymmetric dentoalveolar and/or basal bone structure of the right or left anterior segment of the maxillae. It is important to compare and contrast the linear and angular asymmetry of impaction side with contralateral non impaction side and also to evaluate any maxillomandibular asymmetry in transverse dimensions. In view of this, the present study was carried out to evaluate these parameters from posteroanterior cephalogram. The following conclusions can be drawn:

The distance of canines on the impaction side from mid sagittal plane are decreased and long axis of canines showed more obtuse angulation with respect to selected plane and there was decreased nasal cavity width on impaction side when compared with contralateral non impacted side. No statistically significant difference of skeletal parameters was present between impaction side and contralateral non impacted side. No maxillomandibular asymmetry was present in subjects with unilateral palatal canine impaction. All of these factors have an impact on prognosis and ultimate treatment outcome of a case.

Abbreviations and landmarks defined:

A1: A point selected at the interdental papilla of upper incisors at the junction of crown and gingiva.

ANS: The tip of the anterior nasal spine.

B1: A point selected at the interdental papilla of lower incisors at the junction of crown and gingiva.

Cd(condylion): The superoanterior point on the contour of the condylar head.

Cg: Crista galli.

G(gonial point): Points at the lateral interior inferior margin of the antegonial protuberance on mandible (left and right) GA-AG.

J point: The bilateral points at the intersection of maxillary tuberosity and zygomatic buttress(right and left).

ME: A point at the inferior border of symphysis directly inferior to mental protuberance and inferior to the centre of trigonum menti.

MSR: Median sagittal reference plane.

Nc: Nasal cavity.

Z point: Bilateral points on the medial margin of the zygomaticofrontal suture, at the intersection of the orbits (ZL as left and ZR as right).

ZA, AZ: Centre of the roof of zygomatic arch. It is abbreviated as ZA as left side and AZ as right side.

UI: Upper interincisal point.

A6L and A6R (upper molar left and right): The buccal most point on the crowns of the upper first molars. A3Lcc and A3Rcc (upper canine left/right crown center): It is defined as the intersection between the two maximal diameters of the canine.

REFERENCES

- Baccetti T. 1998. A clinical and statistical study of etiologic aspects related to associated tooth anomalies in number, size, and position. *Minerva Stomatol.* 47:655–663.
- Baccetti T. 1998. A controlled study of associated dental anomalies. *Angle Orthod.*, 68:267–274.
- Bedoya MM, Park JH. A Review of the Diagnosis and Management of Impacted Maxillary Canines. *J Am Dent Assoc* 2009;140:1485-93.
- Bodner L, Sarnat H, Bar-Ziv J, Kaffe I. 1994. Computed tomography in the management of impacted teeth in children. *J Dent Child.*, 61: 370-377.
- Brenchley Z, Oliver RG. 1997. Morphology of anterior teeth associated with displaced canines. *Br J Orthod.*, 24:41–45.
- Ericson S, Kuroi J. 1987. Radiographic examination of ectopically erupting maxillary canines. *Am J Orthod Dentofacial Orthop.* 91:483–492.
- Ericson S, Kuroi J. 1988. Early treatment of palatally erupting maxillary canines by extraction of primary canines. *Eur J Orthod.*, 10:283–295.
- Grummons DC, Kappeyne van de Copello MA. Frontal asymmetry analysis. *J Clin Orthod* 1987;21: 448-65.
- Hinds, K.F. 2004 Alveolar ridge development with forced eruption and distraction of retained natural dentition. *Oral and Maxillofacial Surgery Clinics of North America*, 16, 75–89.
- Hurme V. 1949. Range of normalcy in the eruption of permanent teeth. *J Dent Child.*, 16:11–15.
- Inspection V. 2000. A review of impacted permanent maxillary cuspid diagnosis and prevention. *J Can Dent Assoc.*, 66:497-501.
- Jacoby H. The etiology of maxillary canine impactions. A clinical and radiologic study. *Am J Orthod Dentofac Orthop.* 1983;84:125–32.
- Kanavakis G, Curran KM, Wiseman KC, Barone NP, Finkelman MD, Srinivasan S, Lee MB, Trotman CA. 2015. Evaluation of crown-root angulation of lateral incisors adjacent to palatally impacted canines. *Prog Orthod.* 16:4.
- Kim Y, Hyun H-K, Jan K.T. 2012. The position of maxillary canine impactions and the influenced factors to adjacent root resorption in the Korean population. *Euro J Orthod.*, 34: 302–306.
- Langberg BJ, Peck S. 2000. Adequacy of maxillary dental arch width in patients with palatally displaced canines. *Am J Orthod Dentofacial Orthop.*, 118:220–223.
- Leifert S, Jonas IE. 2003. Dental anomalies as microsymptom of palatal canine displacement. *J Orofac Orthop.* 64:108–120.
- Lindauer SJ, Rubenstein LK, Hang WM, Clark Andersen W, Isaacson RJ. 1992. Canine impaction identified early with panoramic radiographs. *J Am Dent Assoc.*, 123:91–97.
- McConnell TL, Hoffman DL, Forbes DP, Janzen EK, Weintraub NH. 1996. Maxillary canine impaction with transverse maxillary deficiency. *ASDC J Dent Child.*, 63:190–195.
- Mischkowski R, Pulsfort R, Ritter L, Neugebauer J, Brochhagen H, Keeve E. 2007. Geometric accuracy of a newly developed cone-beam device for maxillofacial imaging. *Oral Surg Oral Med Oral Pathol Oral Radiol Endod.* 104:551–9.
- Mischkowski, R.A. et al. (2007) Geometric accuracy of a newly developed cone-beam device for maxillofacial imaging. *Oral Surgery, Oral Medicine, Oral Pathology, Oral Radiology, and Endodontics*, 104, 551–559.
- Mossey PA, Campbell HM, Luffingham JK. 1994. The palatal canine and the adjacent lateral incisor: a study of a west of Scotland population. *Br J Orthod.*, 21:169–174.
- Oliver RG, Mannion JE, Robinson JM. 1989. Morphology of the maxillary lateral incisor in cases of unilateral impaction of the maxillary canine. *Br J Orthod.*, 16:9–16.
- Peck S, Peck L, Kataja M. 2002. Concomitant occurrence of canine malposition and tooth agenesis: evidence of orofacial genetic fields. *Am J Orthod Dentofacial Orthop.*, 122:657–660.
- Preda L, La Fianza A, Di Maggio EM, et al. The use of spiral computed tomography in the localization of impacted maxillary canines. *Dentomaxillofac Radiol* 1997;26: 236-41.
- Ricketts RM. 1960. A foundation for cephalometric communication. *Am J Orthod Dentofacial Orthop.*, 41:330–357.
- Ricketts RM. 1972. The value of cephalometrics and computerized technology. *Angle Orthod.*, 42:179–199.
- Ricketts RM. 2000. Progressive Cephalometrics. Paradigm. Scottsdale, Ariz: American Institute for Bioprogressive Education;1998:26–29.
- Sajrani A, King N. 2012. Dental age of children and adolescents with impacted maxillary canines. *J Orofac Orthop.*, 73:359–64.
- Schmuth GPF, Freisfeld M, Koster O, Schuller H. 1992. The application of computerized tomography (CT) in cases of impacted maxillary canines. *Eur J Orthod.*, 14: 296-301.
- Simon, B.I., Von Hagen, S. Deasy, M.J, Faldu, M. and Resnansky, D. 2000 Changes in alveolar bone height and width following ridge augmentation using bone graft and membranes. *Journal of Periodontology*, 71, 1774–1791.
- Stahl F, Grabowski R. 2003. Maxillary canine displacement and genetically determined predisposition to disturbed development of the dentition. *J Orofac Orthop.* 2003;64:167 -177.
- Svinhufvud E, Myllarniemi S, Norio R. 1988. Dominant inheritance of tooth malpositions and their association to hypodontia. *Clin Genet.* 1988;34:373–381.
- Tadinada A, Mahdian M, Vishwanath M, Allareddy V, Upadhyay M, Yadav S. 2015. Evaluation of alveolar bone dimensions in unilateral palatally impacted canine: a cone beam computed tomographic analyses. *Eur J Orthod.*, 37(6):596–602.
- Timock AM, Cook V, McDonald T, Leo MC, Crowe J, Benninger BL, Covell DA. 2011. Accuracy and reliability of buccal bone height and thickness measurements from cone-beam computed tomography imaging. *Am J Orthod Dentofac Orthop.* 140:734–44.
- Timock, A.M. et al. 2011. Accuracy and reliability of buccal bone height and thickness measurements from cone-beam computed tomography imaging. *American Journal of Orthodontics and Dentofacial Orthopedics*, 140, 734–744
- Walker L, Enciso R, Mah J. 2005. Three-dimensional localization of maxillary canines with cone beam computed tomography. *Am J Orthod Dento fac Orthop.*, 128:418–23.
- Zubillaga, G., Von Hagen, S., Simon, B.I. and Deasy, M.J. 2003. Changes in alveolar bone height and width following post-extraction ridge augmentation using a fixed bioabsorbable membrane and demineralized freeze-dried bone osteoinductive graft. *Journal of Periodontology*, 74, 965–975.