



ISSN: 0975-833X

Available online at <http://www.journalera.com>

INTERNATIONAL JOURNAL
OF CURRENT RESEARCH

International Journal of Current Research
Vol. 13, Issue, 01, pp. 15712-15714, January, 2021

DOI: <https://doi.org/10.24941/ijcr.40673.01.2021>

RESEARCH ARTICLE

RESULTS OF SHORT SEGMENT POSTERIOR FIXATION IN AO TYPE C FRACTURE OF DORSOLUMBAR SPINE

*Dr. Santosh A Hingu, Dr. Kuldip Chovatiya and Dr Paritosh Solanki

Senior Resident, Orthopedic Department, B J Medical College Civil Hospital, Ahmedabad

ARTICLE INFO

Article History:

Received 09th October, 2020
Received in revised form
07th November, 2020
Accepted 16th December, 2020
Published online 30th January, 2021

Key Words:

Thoracolumbar,
managements and rehabilitations

ABSTRACT

Introduction: Spinal injuries are one of the common injuries in road traffic accidents and high velocity traumas. Needs special attentions regarding its managements and rehabilitations. Thoracolumbar is the second most common segment involved in the vertebral column following cervical segment in patients with spinal injuries. The goal of treatment of any spinal injury is restoration of the patient to maximum possible function with disability free life. Initially, Long segment transpedicular fixation was done, which is providing stability to spine but in this type of fixation Motion segments of spine are involved which leads to rigid and fix spine. To overcome this problem, Short segment fixation is developed in which Motion segments of spine can be preserved without disturbing stability of fixation. In this study patients were managed with short segment spinal fixations and follow-up with various criterias regarding its out-come. **Materials and Methods:** 32 atients out of which 23 male and 9 female with thoraco-lumbar junctions injuries are managed with short segment posterior spinal fixation. And follow-up with various criteria regarding its outcomes such as vertebral heights attained, sagittal and anterior wedge angle, pain relief and complications such as inplant failure and infections. Mean duration of follow-up was 6 months. **Results:** in this study which was done on 32 patient. Mean age was 35.6 for males and 33.56 for females. The mean regional angle observed during pre-operative stages was $16.0^{\circ} \pm 5.1$ and during pre-op-24th post op week it was $4.1^{\circ} \pm 4.2^{\circ}$. mean difference between this two is 11.95° and $p < 0.05$. the mean anterior wedge angle observed during pre-operative stages was $18.0^{\circ} \pm 6.9^{\circ}$ and during 24th post op week it was $5.2^{\circ} \pm 4.8^{\circ}$. mean difference between this two is 13.6° and $p < 0.05$. The mean difference in vertebral height between the pre-operative stage and 6th post-op week was 7.96mm. in terms of complication one patient developed post-op infection. **Conclusion:** Short segment posterior instrumentation is a good implant system used in the treatment of vertebral fractures. There is a statistically significant restoration of vertebral body height, mean regional angle and mean anterior wedge angle, sparing of motion segments which are sacrificed in the conventional long segment fixation and avoiding morbidity of anterior approach for anterior reconstruction.

Copyright © 2021, Dr. Santosh A Hingu et al. This is an open access article distributed under the Creative Commons Attribution License, which permits unrestricted use, distribution, and reproduction in any medium, provided the original work is properly cited.

Citation: Dr. Santosh A Hingu, Dr. Kuldip Chovatiya and Dr Paritosh Solanki. "Results of short segment posterior fixation in ao type c fracture of dorsolumbar spine", *International Journal of Current Research*, 13, (01), 15712-15714.

INTRODUCTION

Spinal traumas are common and leading problem in orthopaedics practice. The individuals are at a risk of high energy trauma in modern era. Unstable thoraco-lumbar burst fractures are serious injuries of concern, if left untreated may result in marked morbidity and disability to the patient. Thoracolumbar is the second most common segment involved in the vertebral column following cervical segment in patients with spinal injuries. It constitutes 30-60% of all spinal injuries. Only 15-20% of thoracolumbar fractures are associated with neurological injury.

Thoracolumbar injuries classically exhibit a bimodal distribution, with peaks among males under 30 years of age and in the geriatric population. The goal of treatment of any spinal injury is restoration of the patient to maximum possible function with disability free life. The surgery for the treatment of thoracolumbar fractures can be performed by different approaches such as anterior, posterior, lateral or antero-posterior approaches. The posterior approach is a safe option since most of the specialists are familiar with this approach. The added advantage being the spine can be stabilized by the posterior approach by many available instruments. In Transpedicular Screw Placement system, the fixation achieved is more rigid as the screw is passed through the 'force nucleus' of the vertebrae and through all the three columns. This is the point through which 5 anatomical structures - the superior facet, the inferior facet, the lamina, the pedicle and the

*Corresponding author: Dr. Santosh A Hingu

Senior Resident, Orthopedic Department, B J Medical College Civil Hospital, Ahmedabad

transverse process; channel all posterior forces that are transmitted to the body. Initially, Long segment transpedicular fixation was done, which is providing stability to spine but in this type of fixation Motion segments of spine are involved which leads to rigid and fix spine. To overcome this problem, Short segment fixation is developed in which Motion segments of spine can be preserved without disturbing stability of fixation. In this study, we stabilized the patients with Ao type C thoracolumbar fractures with short segment posterior instrumentation with transpedicular screws.

METHODS AND MATERIOLOGY

Background: Traditionally Ao type C fractures of thoracolumbar spine were treated with long segment fixation. In this type of fixation motion segments of spine were affected. While in short segment fixation motion segment of spine are preserved. Insertion of screw at fracture site provides additional stability. So vertebral height can be maintained and additionally it prevents the parallelogram effect which was occurring with short segment fixation in Ao type C fractures.

Aim of study:

-) To study efficacy of short segment posterior instrumentation in achieving stabilization of Ao type C fractures of thoracic and lumbar spine.
-) To study the advantages and complications of short segment posterior instrumentation
-) To facilitate early mobilization of patients and thus helping easy nursing care of the patients in order to create stable, pain-free spinal column.

Study Level: This is a therapeutic study – LEVEL II, prospective comparative study.

Method of collection of data

Sampe size: Thirty two adult patients with acute thoracolumbar injuries who gave the consent for surgery admitted during the study period were included as the study sample. A detailed history was obtained for evaluating the mode of trauma, ASIA grading, sensory level and to check for any spinal deformity. They were clinically and radiologically evaluated for ensuring the thoracolumbar fracture. Plain x-rays in antero-posterior and lateral views were obtained.

MRI/CT scan were conducted. All fractures were classified Type C according to the AO classification system.

Inclusion and exclusion criteria

Inclusion criteria

-) Traumatic thoraco-lumbar fracture from T10 to L5
-) Age > 18 years.
-) Duration of injury < 2 weeks

Exclusion criteria

-) Patients not willing for surgery.
-) Patients medically unfit for surgery.
-) Age < 18 years

-) Fracture anywhere in spine other than thoracolumbar region.
-) Associated head injury
-) Pathological thoracolumbar fractures.
-) Traumatic thoracolumbar fractures treated with other methods.
-) Duration of injury > 2 weeks.

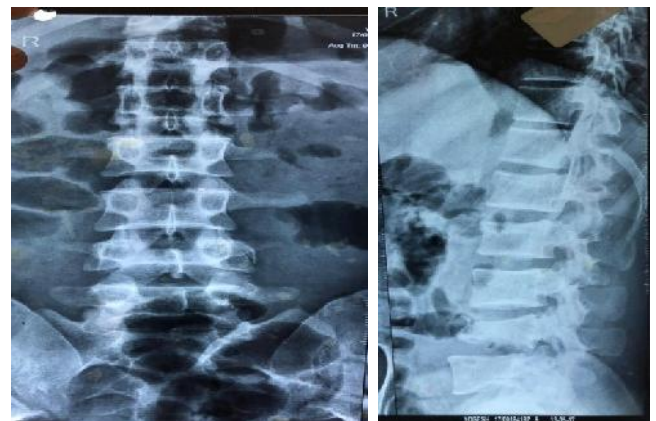OBSERVATIONS AND RESULTS

Table 1. Distribution of the study group according to age group and sex

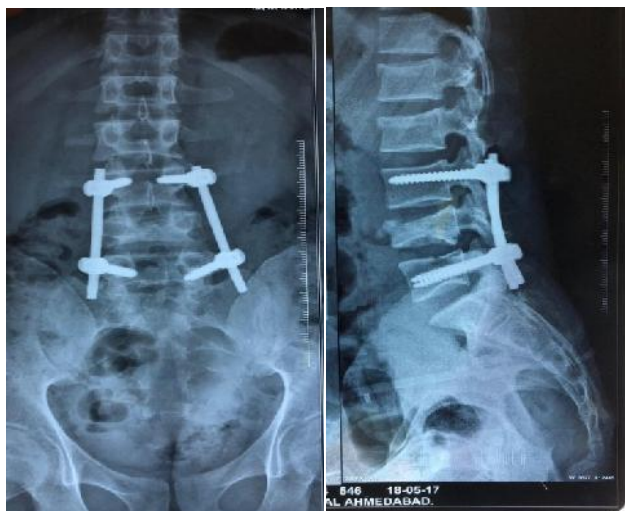| Age group | Male | Female | Total |
|--------------------|--------------|--------------|-----------|
| Less than 20 years | 2(6.4%) | 1(3.2%) | 3(9.6%) |
| 21-30 years | 9(28.8%) | 2(6.4%) | 11(35.2%) |
| 31-40 years | 4(12.8%) | 4(12.8%) | 8(25.6%) |
| 41-50 years | 5(16%) | 1(3.2%) | 6(19.2) |
| More than 50 years | 3(9.6%) | 1(3.2%) | 4(12.8%) |
| Total | 23(73.6%) | 9(28.8%) | 32(100%) |
| Mean ±SD | 35.6 ± 11.62 | 33.56 ± 11.2 | |

Most common vertebra involved in the study group was T12 (31.25%). Because dorsolumbar junction is a transition zone between rigid thoracic spine and mobile lumbar spine. It is observed that, 53% patients of study group had a stay of about 11-20 days in the hospital. 44% patients had a stay of less than 10 days. The mean difference in the regional angle between pre-operative stage and 24th post op week was 11.95°. The p values corresponding to the same was 0.0001 (p<0.05). Since the p values are less than 0.05, there is a significant difference between pre-op and post-operative regional angles.

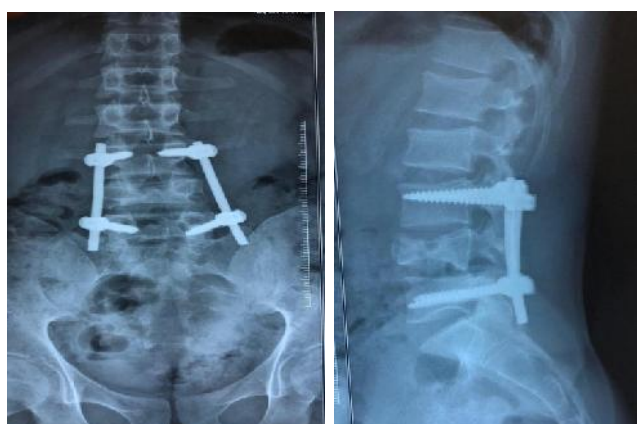
In the study group, The mean difference in the anterior wedge angle between pre-operative stage and 24th post op week was 13.6°. The p values corresponding to the same was 0.0001 (p<0.05). Since the p values are less than 0.05, there is a significant difference between pre-op and post-operative anterior wedge angles. The mean difference in vertebral height between the pre-operative stage and 6th post-op week was 7.96mm, The p values corresponding to the same was 0.0001, which is less than 0.05, which implies that there is a significant difference in the vertebral height between pre-operative and post-operative stages. Complications in the study group. 78% patients had no complications. Pressure sores, and screw misplacement, each was observed in some patients of study group. Discharging sinus was observed in 3% patients.



Preop X-ray



Immediate Postop



6 Months Follow up

A 26-year male patient had h/o bike accident and was L4 fracture with paraparesis without bowel bladder involvement. Patient was similarly operated by Short Segment Posterior Fixation.

CONCLUSION

Short segment posterior instrumentation is a good implant system used in the treatment of vertebral fractures. There is a statistically significant restoration of vertebral body height, mean regional angle and mean anterior wedge angle, sparing of motion segments which are sacrificed in the conventional long segment fixation and avoiding morbidity of anterior approach for anterior reconstruction. However, in patients who presented with type A neurological deficits, this procedure did not improve neurological status statistically but it helped to stabilize and helped in good nursing care and early mobilization of patients.

REFERENCES

- Alpantaki K Bano A, Pasku D, Mavrogenis AF, Papagelopoulos PJ, et al(2010) Thoracolumbar burst fractures; a systematic review of management, *Orthopaedics* 33;422-429.
- Benson DR, Keenen TL, Evaluation and Treatment of Trauma to Vertebral column, *Journal of Bone and Joint Surgery* 1990; 39; 577-588.
- Blick EM, source of Orthopaedics, Baltimore, Lippincott Williams Ans Wilkins, 1948; 236-238.
- Burney RE, Maio RF, Maynard F. incidence, characteristics and outcomes of spinal cord injury at trauma centers in North America. *Arch Surg* 1993; 128(5);596-9.
- Francaviglia N, Bragazzi R, Maniello M, Berucci C: "Surgical treatment of fracture of thoracic and lumbar spine via the transpedicular route"; *British Journal of Neurosurgery*;9(4): 511-8, 1995.
- Gutman I: "Spinal cord injuries – Comprehensive management and research";Oxford: Blackwell Scientific Publications: 137-176, 1976.
- Jens R Chapman Sohail K Mirza H. Rockwood, Green Fracture in Adults, Lippincott Williams and Wilkins, volume 2; 1295 – 1466
- Lefertint VJM, Zimmer KW, Veldhuis EFM, Ten Vergert E.M, Ten Duis, HJ. Thoracolumbar spinal fractures: radiological results of transpedicular fixation combined with transpedicularcancellous bone grafts and posterior fusion on 183 patients. *Eur Spine J* 2001; 10(6): 517
- Leventhal MR, "Fracture, dislocations and fracture dislocation of spine" *Campbell's operative orthopaedics*, Edited by S. Terry Canale, 9th edn, 1998, Vol 3; 2747-2779.
- Memmert M (1999) EinVersuch, die Geschichte Der Wirbelsaulenchirurgiezuumreissen. In: Memmert M, Memmert G (eds) *Die Wirbelsuale in der Anschauung. Spurensuche in Kunst, Geschichte and Sprache*. Springer Verlag, Berlin Heidelberg, pp 247-270.
- Nicoll EA (1949) Fractures of Dorsolumbar Spine. *J Bone and Joint Surgery Br* 31; 376-394.
- Oner FC, Wood KB, Smith JS, Shaffrey CI (2010) Therapeutic decision making in thoracolumbar spine trauma. *Spine (Phila Pa 1976)* 35; S235-244.
- Riggins RS, Kraus JF. The risk of neurological damage with fractures of vertebrae, *Journal of trauma* 1977; 126-133.
- Robert W. Bucholz, James D Heckman: "Rockwood and Green's Fractures in adults" Lippincott, Williams and Wilkins; 5th edition; Vol 2; 1293-1466,2001.
- Watson – Jones R: "Fractures and Joint injuries"; Ed. J.B.Wilson, Edinburgh: Churchill livingstone: 789-792, 1982.
