



ISSN: 0975-833X

Available online at <http://www.journalcra.com>

INTERNATIONAL JOURNAL
OF CURRENT RESEARCH

International Journal of Current Research
Vol. 13, Issue, 06, pp.17932-17934, June, 2021

DOI: <https://doi.org/10.24941/ijcr.41664.06.2021>

RESEARCH ARTICLE

OPEN ACCESS

RARE CASE OF LIVER ABSCESS IN COVID 19 POSITIVE

¹Dr. Simranjit Kaur Dhadiala and ^{2,*}Dr. Abhijit Anil Whatkar

¹MBBS, MS, FMAS, DMAS, ²MBBS, DNB GEN Surgery, FMAS, DMAS, FIAGES, FCPS, Noble Hospital & Research Centre, Pune

ARTICLE INFO

Article History:

Received 15th June, 2021
Received in revised form
25th June, 2021
Accepted 30th June, 2021
Published online 10th July, 2021

Key Words:

SARS – CoV 2
Liver Abscess, Cytokine storm Cytokine S.

ABSTRACT

SARS-CoV-2, previously known as 2019-nCoV, also known as COVID-19, belonging to the group of coronaviruses, originated in Wuhan, Hebei, China, is responsible for acute respiratory disease. In March 2020 WHO declared COVID-19 as pandemic. Previous outbreaks of coronavirus group were SARS in 2002-2003 and MERS in 2012. In the initial phase of the pandemic, this disease affected mainly the elderly, immunocompromised patients and patients with underlying chronic diseases. COVID-19 has shown many presentations, primarily being pulmonary symptoms, but has shown gastrointestinal implications such as hepatic injury by serum markers and histologic evaluation. We present here a case of liver abscess in COVID-19 positive patient that was managed with minimal invasive procedures.

Copyright © 2021. Dr. Simranjit Kaur and Dr. Abhijit Anil Whatkar, This is an open access article distributed under the Creative Commons Attribution License, which permits unrestricted use, distribution, and reproduction in any medium, provided the original work is properly cited.

Citation: Dr. Simranjit Kaur and Dr. Abhijit Anil Whatkar, "Rare case of liver abscess in covid 19 positive", 2021. International Journal of Current Research, 13, (06), 17932-17934.

INTRODUCTION

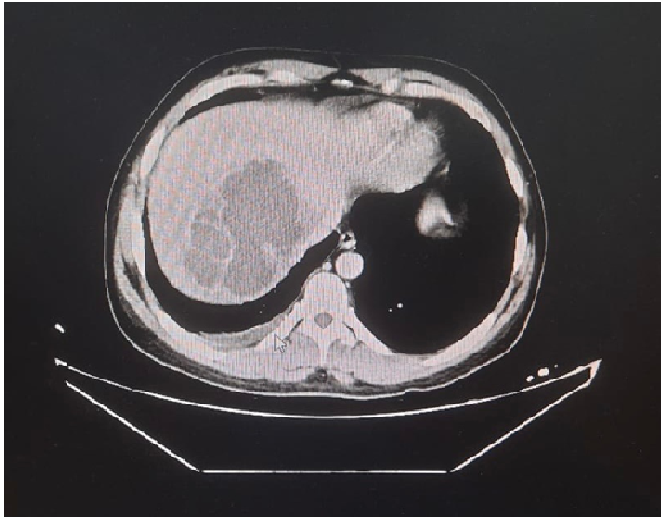
In mid March 2021, a 36 year old male patient without significant medical history presented to the hospital emergency department with two days period of history of fever, cough, bodyache and shortness of breath. At that time of pandemic, universal testing of COVID-19 for individuals requiring admission was implemented, and the patient was tested positive for SARS-COV 2. On admission, patient's vitals were HR-90 beats/min, BP-110/80mmHg, SpO₂-94% on room air, RR-16 breaths/min, Temp-98.4 F. As per COVID-19 hospital protocols, HRCT thorax was done which was suggestive of small right pleural fluid with subtle left pleural fluid and a large lobulated iso to hypo-dense lesion measuring 7.5x6.2 cm in segment VIII of liver. His blood work up had been notable for WBC-14700/cmm, Hb-11.1 gm%, ESR-83 mm/1 hr. Liver enzymes and bilirubin were in normal limits (Total bilirubin-1.69 mg/dl, SGOT-49 IU/Lt, SGPT-58 IU/Lt). Alkaline phosphatase was elevated (487 IU/Lt). There was also an elevation in inflammatory markers (CRP-207.50 mg/L, serum Ferritin-551.3 ng/ml, IL 6-499.3 Pg/ml). Patient was started on treatment for COVID-19 and also antibiotics for liver abscess. After two days, patient started complaining of pain in right hypochondrium and increased cough. Blood work revealed elevation in WBC count to 16500/cmm, Hb-10.7 gm%, no elevation in liver enzymes and total bilirubin.

CT abdomen and pelvis was notable for well defined, lobulated, walled off multi-septae lesion noted involving posterior segments of right lobe of liver, measuring approximately 10.5 x 7.0 x 6.0 cm, with 80-90% liquefaction. Patient was a high risk surgical candidate, and was planned for percutaneous drainage of the abscess. A sonography guidance pigtail drainage catheter was placed, and the purulent fluid aspirated was sent for gram stain, culture and sensitivity for targeted antibiotic therapy. In addition, right sided intercostal drainage tube (ICD) was inserted in view of pleural effusion. Pus culture did not show any organism growth. Patient was continued on antibiotic course. Subsequently, fever, abdominal pain and cough resolved, and there was a gradual decline in WBC count. Post-procedure day 3, ICD was removed with a maintained oxygen saturation of above 95% in room air, and patient was discharged on the same day with pigtail catheter in situ. With this conservative line of management, the patient responded well and his drain output reduced to 20-25 cc per day. On day 10 of post procedure, pigtail catheter was removed. Patient recovered from COVID-19 and liver abscess symptoms, and is hemodynamically stable.

DISCUSSION

In 2019 December, an outbreak of severe respiratory syndrome causing pneumonia was identified in Wuhan, China. In March

2020 WHO declared COVID-19 as a pandemic. SARS CoV2 responsible for this pandemic belongs to a group of coronaviruses. Chan et al found that genome responsible for SARS CoV2 had 80% homology with human SARS CoV, and both were responsible for the pathology due to interaction with angiotensin converting enzyme (ACE) 2 receptor (Chan *et al.*, 2019; Zhou *et al.*, 2020). In early stage of pandemic, SARS CoV2 was seen to cause gastrointestinal symptoms such as diarrhoea, nausea, vomiting and abdominal pain.



However, in recent studies COVID-19 has reported to cause varying degrees of liver damage. 60% of COVID-19 positive patients are reported with deranged liver function tests (LFT) (Chau *et al.*, 2004). Symptoms of COVID-19 range from fever, cough, dyspnoea to acute respiratory distress syndrome and shock (Yang, 2020). However, there have been cases of other organ involvement due to COVID-19, such as liver. A recent study showed 43 cases of COVID-19 patients with deranged liver function tests, higher values of alanine aminotransferase (ALT) and aspartate aminotransferase (AST), and 1 of 99 patients had severe liver damage (Chen, 2019). Deranged liver function test reported were higher levels of ALT or AST, or increase in bilirubin levels. In a study by Cai et al, 298 patients included in the study, of which 44 had liver injury (14.8%), 36.2% showed severe liver injury, were more prone to deranged liver function tests than patients with mild liver injury (9.6%)(6). Angiotensin converting enzyme-2 receptor has been reported responsible for entry of virus into the cells. This receptor is found rarely in hepatocytes, but found in abundance in cholangiocytes, and is known to be unregulated to liver cells in physiologic stress (Portincasa *et al.*, 2020).

COVID-19 plays a role by causing bile duct dysfunction, which along with viral immunologic injury is responsible to interfere with liver regeneration and immune response. ACE-2 receptors are also found on endothelial cells, such as in portal vasculature (Varga, 2020). In a study by Lagana et al, liver and lung sections of 40 consecutive COVID-19 patients was examined, of which 2 of them showed fibrosis and 1 had abscess, and histologic examination showed macro vesicular steatosis, mild acute hepatitis and minimal portal inflammation (Lagana, 2020). In addition, sudden initiation of inflammatory storm i.e systemic inflammatory response syndrome caused by viral infection has been reported in some cases. Cytokine storm increases the release of multiple pro-inflammatory cytokines and markers (tumour necrosis factor, IL-2, IL-6, IL-18, ferritin,

granulocyte colony stimulating factor). This hypercytokinemia leads to tissue injury and multi organ failure, including liver. Liver impairment due to COVID-19 can be due to other reasons, such as drug induced injury, hypoxic injury or exacerbation of underlying chronic liver disease. Indirect liver injury from cytokine storm or ischaemia is a more likely explanation (Zhang, 2020). Since indirect injury to liver is commonly seen, correction of underlying etiology is important. Hypoxic injury correction can be done by oxygen supplementation or mechanical ventilation. Renal replacement therapy can be given for cytokine storm, restoration of intravascular volume and broad spectrum antibiotics for shock. In cases with drug induced liver injury, prompt discontinuation of drug prevents further injury, and adjuvant therapy with hepato-protective anti-inflammatory drugs such as L-ornithine L-aspartate can be used. Rare cases of liver injury causing abscess have been reported. Drainage of abscess under all COVID-19 precautions and targeted antibiotic therapy should be the goal of management.

CONCLUSION

We presented a case of liver abscess in COVID-19 patient which was successfully managed with minimal invasive procedure. Gastrointestinal symptoms and liver function abnormalities of varying degrees has been noted in SARS CoV2. Suspected liver injuries require further investigations and timely management according to the etiology of injury. Very few cases of liver injury causing abscess have been reported. Prompt management with drainage of abscess and targeted antibiotic therapy is the appropriate line of treatment. While treating the underlying etiology, utilisation of anti-inflammatory liver protecting drugs should be considered to prevent further injury.

REFERENCES

- Cai Q, Huang D, Ou P, Yu H, Zhu Z, Xia Z, Su Y, Ma Z, Zhang Y, Li Z, He Q, Liu L, Fu Y, Chen J. COVID-19 in a designated infectious diseases hospital outside Hubei Province, China. *Allergy*. 2020;00:1–11.
- Chan JF, Kok KH, Zhu Z, Chu H, To KK, Yuan S, Yuen KY. 2020. Genomic characterization of the 2019 novel human-pathogenic coronavirus isolated from a patient with atypical pneumonia after visiting Wuhan. *Emerg Microbes Infect*. 9:221–236.
- Chau TN, Lee KC, Yao H, Tsang TY, Chow TC, Yeung YC, Choi KW, Tso YK, Lau T, Lai ST, Lai CL. SARS-associated viral hepatitis caused by a novel coronavirus: report of three cases. *Hepatology*. 2004;39:302–310
- Chen N, Zhou M, Dong X, Qu J, Gong F, Han Y, Qiu Y, Wang J, Liu Y, Wei Y, Xia J, Yu T, Zhang X, Zhang L. Epidemiological and clinical characteristics of 99 cases of 2019 novel coronavirus pneumonia in Wuhan, China:
- Lagana, S.M., Kudose, S., Iuga, A.C. et al. Hepatic pathology in patients dying of COVID-19: a series of 40 cases including clinical, histologic, and virologic data. *Mod Pathol* 33, 2147–2155 (2020).
- Portincasa P, Krawczyk M, Machill A, Lammert F, Di Ciaula A. Hepatic consequences of COVID-19 infection. Lapping or biting?. *European journal of internal medicine*. 2020 Jun 1.

- Varga Z, Flammer AJ, Steiger P, Haberecker M, Andermatt R, Zinkernagel AS, Mehra MR, Schuepbach RA, Ruschitzka F, Moch H. Endothelial cell infection and endotheliitis in COVID-19. *The Lancet*. 2020 May 2;395(10234):1417-8.
- Yang RX, Zheng RD, Fan JG. Etiology and management of liver injury in patients with COVID-19. *World J Gastroenterol*. 2020;26(32):4753-4762. doi:10.3748/wjg.v26.i32.4753
- Zhang C, Shi L, Wang FS. Liver injury in COVID-19: management and challenges. *Lancet Gastroenterol Hepatol*. 2020;5:428-430.
- Zhou P, Yang XL, Wang XG, Hu B, Zhang L, Zhang W, Si HR, Zhu Y, Li B, Huang CL, Chen HD, Chen J, Luo Y, Guo H, Jiang RD, Liu MQ, Chen Y, Shen XR, Wang X, Zheng XS, Zhao K, Chen QJ, Deng F, Liu LL, Yan B, Zhan FX, Wang YY, Xiao GF, Shi ZL. A pneumonia outbreak associated with a new coronavirus of probable bat origin. *Nature*. 2020;579:270–273.
