



ISSN: 0975-833X

Available online at <http://www.journalcra.com>

INTERNATIONAL JOURNAL
OF CURRENT RESEARCH

International Journal of Current Research
Vol. 14, Issue, 02, pp.20717-20719, February, 2022

DOI: <https://doi.org/10.24941/ijcr.42898.02.2022>

RESEARCH ARTICLE

SYNCHRONOUS TRIPLE COLON CANCER CASE REPORT AND LITERATURE REVIEW

Georgios Meimaris, *Ioannis Stamatatos, Makis Kritikos, Marigo Theodorou, Efstathios Metaxas, Georgios Anagnostopoulos, Basilis Mpoumis and Athanasios Rogdakis

Second Surgical Department General Hospital of Nikaia- Piraeus "Agios Panteleimon" Piraeus-Greece

ARTICLE INFO

Article History:

Received 14th November, 2021

Received in revised form

19th December, 2021

Accepted 24th January, 2022

Published online 28th February, 2022

Keywords:

Synchronous Triple Colon Cancer,
Synchronous Colorectal Cancer, Rare
Colon Cancer Case Report.

*Corresponding author:

Ioannis Stamatatos

ABSTRACT

Synchronous multiple colorectal cancers are defined as multiple malignant tumors of the colon and rectum, occur simultaneously, are distant from each other and are not a result of metastasis. We present a case of a 76 years old male who was admitted to our hospital complaining of diffuse, mild abdominal pain started a month ago, associated with diarrhea, fatigue and body weight loss. Computer tomography revealed a mass at the splenic flexure. Colonoscopy confirmed the finding of the tumor at the splenic flexure obstructing the lumen of the colon, not allowing the examination to be completed. Furthermore, a second tumor was found at the boundary between descending and sigmoid colon, narrowing the lumen at approximately 75%. Virtual colonography under CT reconstruction illustrated the previous two lesions and revealed an additionally mass at the hepatic flexure. The patient underwent an exploratory laparotomy the day after and all the above findings were confirmed intraoperatively for which he received a successful extended colectomy.

Copyright © 2022. Georgios Meimaris et al. This is an open access article distributed under the Creative Commons Attribution License, which permits unrestricted use, distribution, and reproduction in any medium, provided the original work is properly cited.

Citation: Georgios Meimaris, Ioannis Stamatatos, Makis Kritikos, Marigo Theodorou, Efstathios Metaxas, Georgios Anagnostopoulos, Basilis Mpoumis and Athanasios Rogdakis. "Synchronous triple colon cancer. case report and literature review.", 2022. *International Journal of Current Research*, 14, (02), 20717-20719.

INTRODUCTION

Colon is affected from cancer very often, especially in older people with familial history. Synchronous multiple colon cancer is a very rare condition especially in patients with negative family history. For treatment of synchronous multiple colon cancer identification of concurrent lesions is vital to improve prognosis. Here we present a case of a 76 years old male with a triple colon cancer without related familial history.

Case presentation: A 76 years old male admitted in our hospital with a history of diffuse abdominal pain started about a month ago, accompanied by diarrhea, fatigue and weight loss. Physical examination of the abdomen revealed mild tenderness at the deep palpation of hypogastrium and left flank. Digital examination of anus was negative for blood. There was no family history for cancer, while personal history of smoking cessation 25 years ago, appendectomy before 47 years and hypertension under treatment were mentioned. The blood test revealed Hct 27, 6%, Hgb 8,2gr/dl, Wbc 8,2gr/dl, total serum proteins 4,6gr/dl, serum albumin 1,9gr/dl, CRP level of 52,4mg/l and tumor markers were within normal range.

Computer Tomography scan revealed thickness of the wall of the splenic flexure and the presence of a mass in the same area. (Figure 1 & 2). Colonoscopy detected an ulcerative mass at the splenic flexure which occluded the lumen of the colon and it did not allow the colonoscope to promote any further. At the boundary between descending and sigmoid colon, a second mass was revealed, which occupied circumferentially the lumen at 75%. Biopsies from both lesions were taken. Due to incomplete endoscopic examination, a virtual colonoscopy was imperative and verily revealed a third suspicious mass. The patient, after the adequate preoperative evaluation was transferred into the operation room. During the explorative laparotomy, a sizable mass (max. diameter ~ 10cm) was found at the splenic flexure which penetrated posterior colon wall and successively invaded jejunum right after the Treitz ligament. A second tumor was detected at the sigmoid colon, approximately 25 cm of the anus at the boundary between descending and sigmoid colon. The third and larger mass (max. diameter ~ 12cm) was located at the hepatic flexure. A subtotal colectomy was decided and performed with an ileo-rectal anastomosis. The invaded segment of the jejunum was resected approximately in 10cm length followed by a side to side jejunum-jejunal anastomosis, after mobilization of the forth part of the duodenum and Treitz ligament.

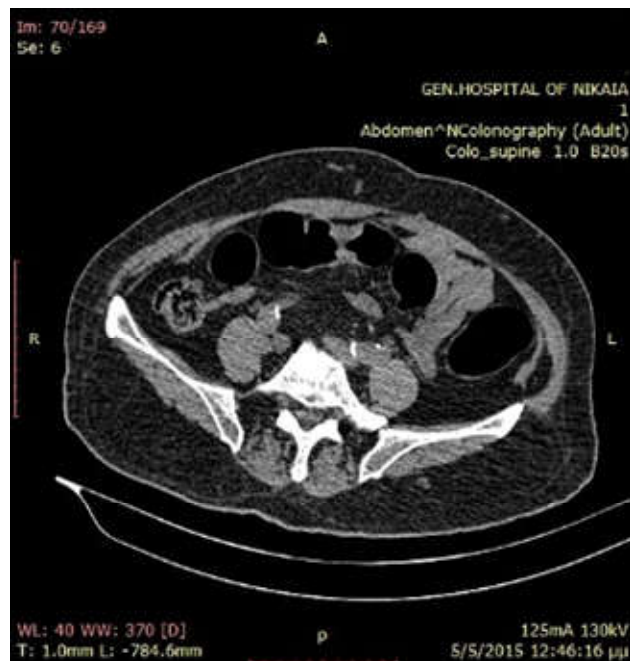
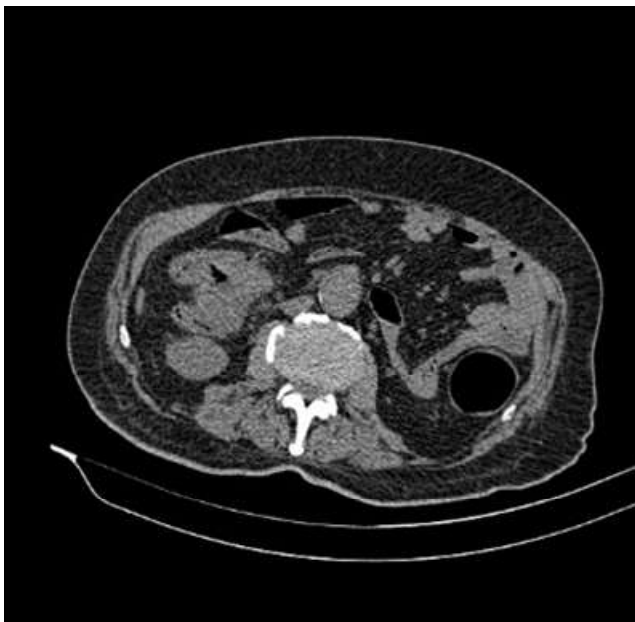
Figure 1 & 2. CT scan depicting colon mass in splenic flexure

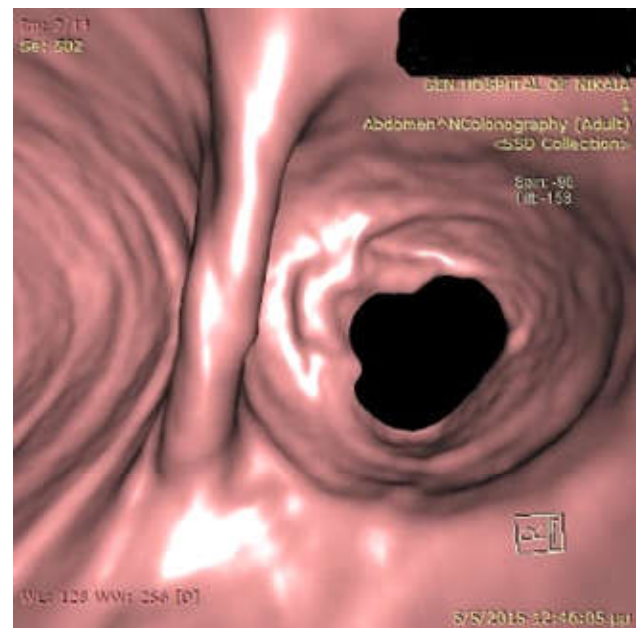
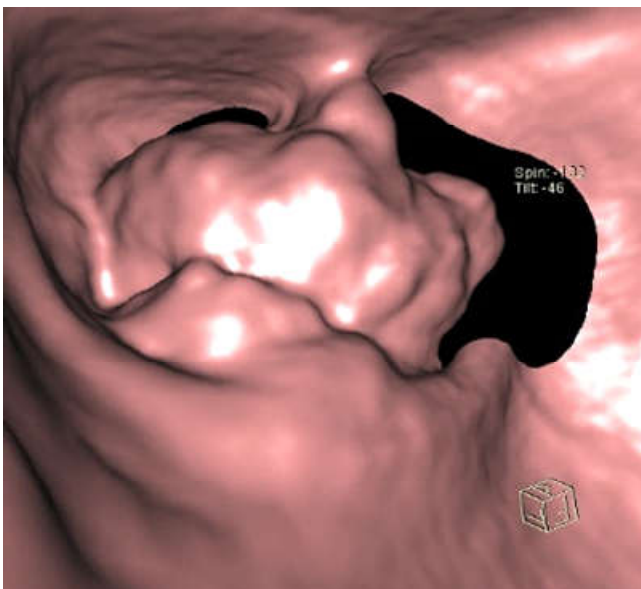


Figure 3 & 4. Virtual colonography & reconstruction demonstrating a mass in hepatic flexure

The rest of the abdominal cavity was checked, but no obvious metastases or other pathology was detected. An additional cholecystectomy was performed. Postoperative course of the patient was uneventful, and he was discharged on the 13th postoperative day. Histopathologic examination disclosed three tumors, one at the hepatic flexure with diameter of 12cm, a second one at the splenic flexure with diameter of 10cm and a third one at the descending colon approximately 3cm of diameter. Microscopically all three lesions were adenocarcinomas, with moderate and low degree of differentiation, with ulceration and necrosis, invasion of the nearby adipose tissue, but no detectable lymph node metastases were found.

DISCUSSION

Almost 50% of the population over 70 years old will develop a lesion at the colon and 10% is malignancy. This is why, in the USA colon cancer is the second cause of death from cancer.¹ From this group of patients, 15% have malignant lesions which are the result of hereditary dominant genes, such as in Familial Adenomatous Polyposis (FAP) and Hereditary Non-polyposis Colorectal Cancer (HNPCC).^{2,3} Cancer screening of the general population according to the American College of Gastroenterologists, suggests colonoscopy every ten years after the age of 50.⁴ Furthermore, CT colonography is recommended nowadays as a screening test also every 5 years.⁴

Patients who are diagnosed with colon cancer, is recommended to perform total preoperative colonoscopy to detect synchronous tumors, polyps with a great possibility of malignant transformation, or other lesions such as diverticulitis. Studies have illustrated that the preoperative colonoscopy findings may cause the extension of colectomy in 1/5 of cases.^{5,6,7} A common reason why synchronous lesions may be missed is impassable distal stenosis due to large tumors and inability to complete colon evaluation.⁸ In cases where a mass totally occludes the lumen of the colon, it is substantial to estimate the proximal colon. The methods which are used preoperative are barium enemas and virtual CT or MR

colonography while intraoperatively with direct palpation of the colon and colonoscopy. Preoperative barium enemas are sometimes technically difficult in these patients. Moreover, condensation of barium may delay the operation, because clearance of the colon must be achieved first.⁹ Some authors suggest that intraoperative palpation of colon is a reliable solution for detection of synchronous cancer and that colonoscopy may be accused for intraluminal spreading of malignant cells. Nevertheless, complete colonoscopy should be done shortly after the operation¹⁰, while palpation of a dilated colon or splenic flexure, may be difficult.⁹ CT colonography is another very useful examination today. Studies have proved that polyps over 6mm of diameter are detected, but, on the contrary, virtual colonoscopy is not so successful in detecting polyps under 5mm.¹⁰ It is a well-tolerated examination from the patient, which can eliminate the need of intraoperative colonoscopy or palpation of the colon.⁹ Synchronous colon cancer appears in a rate 1.7 to 9.3%, depending the criteria each writer uses, as in some series in situ cancers are listed.¹² Twenty seven to 55% of the patients have multiple adenomatous polyps, and possible an amount of early recurrences (in less than three years) are due to failure of detection of a synchronous malignancy.⁹ Operative strategy of synchronous multiple colon cancer, is a subject of debate and depends mainly on the lesions location. Usually, total or subtotal colectomy is the radical solution, although, in some cases partial colectomies can take place.^{12, 13}

CONCLUSION

From the current data, multiple synchronous triple colon cancer is extremely rare. To the best of our knowledge this is the first reported case of synchronous triple carcinoma of the colon in Greece. Preoperative study is essential if more than one tumor is suspected and additional examinations may be helpful in operative strategy. Intraoperative colonoscopy seems to be mandatory to confirm whether the remaining colon is disease free. Proper management of synchronous colon cancer requires an extensive abdominal surgery including exploratory laparotomy alongside intraoperatively confirmation of diagnosis and radical resection of the diseased bowel. Our report strengthens the importance of a thorough, extensive examination to adequate planning and avoids overlooking small or early-staged synchronous lesions.

Conflict of interest: None. The authors declare no conflict of interest

Consent: Written informed consent was obtained from the patient for publication of this case report and any accompanying images.

REFERENCES

1. Ms. Sheryl L. Parker MSPH, Mr. Tony Tong MS, Ms. Sherry Bolden BA, Dr. Phyllis A. Wingo PhD, MS: Cancer statistics, 1996, CA: A Cancer Journal for Clinicians, Volume 46, Issue 1, pages 5–27, January/February 1996
2. Kenneth W Kinzler, Bert Vogelstein : Lessons from Hereditary Colorectal Cancer, Cell press Volume 87, Issue 2, 18 October 1996, Pages 159–170
3. L.A. Cannon-Albright, M.H. Skolnick, D.T. Bishop, R.G. Lee, R.W. Burt: Common inheritance of susceptibility to colonic adenomatous polyps and associated colorectal cancers, N. Engl. J. Med., 319 (1988), pp. 533–537
4. Rex DK, Johnson DA, Anderson JC, Schoenfeld PS, Burke CA, Inadomi JM: American College of Gastroenterology. American College of Gastroenterology guidelines for colorectal cancer screening 2009 Am J Gastroenterology 2009 Mar;104(3):739-50
5. Richard B Arenas, MD, Alessandro Fichera, MD, Debbie Mhoon, Fabrizio Michelassi, MD: Surgery, October 1997, Volume 122, Issue 4, Pages 706–710
6. Adloff M, Arnaud JP, Bergamaschi R, Schloegel M: Synchronous carcinoma of the colon and rectum: prognostic and therapeutic implications. *Am J Surg* 1989; 157:299-302
7. Maxfield RG. Colonoscopy as a routine preoperative procedure for carcinoma of the colon. *Am J Surg* 1984; 147:477-480.
8. Kimura T, Iwagaki H, Fuchimoto S, Hizuta A, Orita K. Synchronous colorectal carcinomas. *Hepatogastroenterology*. 1994;41:409–412.
9. Helen M. Fenlon, FFR(RCSI), David B. McAneny, MD2, David P. Nunes, MRCPI, Peter D. Clarke, MD, and Joseph T. Ferrucci, MD: Occlusive Colon Carcinoma: Virtual Colonoscopy in the Preoperative Evaluation of the Proximal Colon, *RSNA Radiology*, February 1999 Volume 210, Issue 2
10. Sollenberger LL, Eisenstat TE, Rubin RJ, Salvati EP: Is preoperative colonoscopy necessary in carcinoma of the colon and rectum?, *The American Surgeon* [1988, 54(2):113-115]
11. Hara AK, Johnson CD, Reed JE, et al: Computed tomographic colography (virtual colonoscopy) for polyp detection: early comparison against barium enema (abstr). *Gastroenterology* 1997; 112:575
12. Schaal JC, Mondino JC, Paris F, Piat JM, Jaeck D: Synchronous colorectal cancers, *Journal de Chirurgie* [1991, 128(11):476-480]
13. Chien-Chih Yeh, Sheng-Chuan His, Chih-Pin Chuu, Yung-His Kao Synchronous triple carcinoma of the colon and rectum. *World J Surg Oncol* 2013; 11:66
