



ISSN: 0975-833X

Available online at <http://www.journalcra.com>

INTERNATIONAL JOURNAL
OF CURRENT RESEARCH

International Journal of Current Research
Vol. 14, Issue, 02, pp.20608-20614, February, 2022

DOI: <https://doi.org/10.24941/ijcr.42974.02.2022>

RESEARCH ARTICLE

ENDOVASCULAR TREATMENT OF INFECTED ABDOMINAL AORTIC ANEURYSM

*Ioannis Stamatatos, MD, MSc

Vascular and Endovascular Surgery Division, General Hospital of Nikaia, Piraeus, Greece

ARTICLE INFO

Article History:

Received 24th November, 2021

Received in revised form

19th December, 2021

Accepted 20th January, 2022

Published online 25th February, 2022

Keywords:

Infected (Infected), Mycotic (Mycotic),
Aorta (Aorta), Aneurysm (Aneurysm),
and Intravascular Intervention (Stent Graft).

*Corresponding author:

Ioannis Stamatatos, MD, MSc

ABSTRACT

Background: Infected aortic aneurysm is one of the major clinical challenges vascular surgeons are facing, with high incidence of morbidity and mortality. In this study we present the advantages of endovascular treatment in patients with infected aortic aneurysms and clarify the factors that determine favorable outcome of these patients. **Material and Methods:** A comprehensive systematic retrospective study (PubMed, Medline, Embase, Google Scholar and Scopus) according to the recommendations of the PRISMA statement for administrative dataset registries reporting outcomes after patients treated endovascularly for infected aortic aneurysm and a thorough evaluation of references. **Results:** Endovascular treatment of infected aortic aneurysms may reduce the early and mid-term mortality. Prolonged fever, fatigue, aortic rupture, aortoenteric, aortobronchial and aortoesophageal fistulas greatly increase the rates of reintervention, morbidity, and mortality. Survival rates in patients without fistulae even reached 94% at 2 years. **Conclusion:** In treatment of infected aortic aneurysms, the use of endovascular aortic graft provides an alternative, to open repair method, and simplifies the management of patients who are in this critical condition. Endovascular treatment of infected aortic aneurysms is feasible both as a temporary measure and the preferred definitive treatment in selected patients.

Copyright © 2022. Ioannis Stamatatos. This is an open access article distributed under the Creative Commons Attribution License, which permits unrestricted use, distribution, and reproduction in any medium, provided the original work is properly cited.

Citation: Ioannis Stamatatos MD, MSc. "Endovascular treatment of infected abdominal aortic aneurysm", 2022. International Journal of Current Research, 14, (02), 20608-20614.

INTRODUCTION

Infected aortic aneurysm is one of the major clinical challenges facing the vascular surgeon. In the Western world infected aortic aneurysms are rare and account for less than 1% -2% of all aneurysms of the aorta, while in Asian countries this figure is greatly increased since it seems to touch 13.6%. Often complicated by other factors such as a delay in diagnosis, rupture, sepsis and perivisceral distribution is associated with high morbidity and mortality 21% - 44%. Clinically the patients present with a painful, rapidly growing aneurysm, accompanied by fever, leukocytosis, and positive blood cultures. The gold standard in the management strategy consists of surgical resection of the aneurysm, extensive debridement of all infected tissue of the aorta wall and surrounding contaminated tissue. Additional coating of the infected field using muscle/ omental flaps and vascular reconstruction by either orthotopic direct transplant or extra-anatomic bypass (ex. axillobifemoral) followed by long term antibiotic treatment. Nevertheless, the surgical treatment of these patients presents with a high surgical risk and mortality.

During the last few decades, the endovascular treatment of degenerative aneurysms of the thoracic and abdominal aorta has been well established, providing obvious benefits in selected patients with high perioperative risk. Nevertheless, endovascular treatment of infected aortic aneurysms comes into conflict with basic surgical principles and acts as a matter of ongoing discussion between the vascular surgeons. Three questions that must be answered regarding the preferred method of endovascular treatment in infected aortic aneurysms is: 1) palliative therapy 2) a bridge to definitive surgical treatment, and 3) when the preferred definitive treatment. Endovascular treatment of infected aortic aneurysms, premiered by Semba and colleagues in 1998, since then several centers studied the advantages by comparing results of endovascular versus conventional open surgery.

History: Although aneurysmal disease is known to the western world, from antiquity and Galen,¹ passed centuries until Paré² in the mid 16th century, described for the first time the correlation between aneurysm and infection, where he presented the necrotomic findings of a patient with syphilitic ruptured aneurysm of the descending thoracic aorta.

During the 19th century, several individual cases have been presented in the literature and especially Rokitansky in Austria,³ Virchow and Koch in Germany,⁴ and Tufnell in Ireland⁵ trying to link infective endocarditis with septic emboli, arterial abscesses and rupture infected aneurysms of the upper mesentery and popliteal arteries. In 1885 William Osler presented the first comprehensive discussion⁶ of an infected aneurysm, and commented their anatomical characters, clinical features, etiology, and pathological correlations. The Gulstonian lectures on malignant endocarditis⁶ presents a 30-year-old man who died after a great bout with chills, diarrhea, headache, cough, and fever. The autopsy showed marked degeneration of the aortic valve vegetations and four aneurysms of the aortic arch because of endocarditis. These aneurysms represented a case of mycotic endocarditis while the largest had perforate and rupture in the pericardium. Hence, he introduced the term mycotic aneurysm, although nowadays is somewhat misleading as most aortic infections are bacterial. However, most authors use even today the term "mycotic aneurysm" to describe any aneurysm, which appears secondary to infection, regardless of the pathogenesis.⁷ Sommerville study in 1959 for atherosclerotic abdominal aortic aneurysms⁸ in more than 20,000 autopsies performed at Mayo Clinic found 178 aneurysms, of which six were infected and four of them had ruptured. On this study it is first described the additional infection to preexisting atherosclerotic aneurysms⁹ by Bennett and Cherry. With the advent of antibiotic therapy, the overall incidence of arterial infection fell as the successful treatment of bacterial endocarditis.¹⁰ Nowadays the incidence of infected aneurysms has increased significantly, mainly in response to the increase of immunocompromised¹¹ population, invasive hemodynamic monitoring^{12, 13} and drug addicts.^{14,15} In per day practice, the choice of orthotopic grafts,¹⁶ after successfully removal of infected aneurysms, is becoming more common as the early diagnosis and multivalent anti-microbial treatments¹⁷ making them ever more effectively. The first report of a successful endovascular treatment of infected aortic aneurysm is made by Semba et al in 1998¹⁸ who described for the first time in the literature successful endovascular treatment of three patients with infected aneurysms of the thoracic aorta and since then remains a subject of continuous debate between vascular specialists.

Classification: Based on etiology, infected arterial aneurysms (AA) are divided into four types: a) mycotic arterial aneurysm by septic arterial emboli, b) microbial arteritis with aneurysmal formation c) infected preexisting aneurysm and d) traumatic infected false aneurysm (Table 1).

Mycotic aneurysms: Mycotic aneurysms occur when septic emboli from the heart adhering to the lumen of the arteries and can affect both normal and pathological arteries. They can occur in any small, medium, or large artery showing preference to arteriovenous communications arterial bifurcations and arterial stenoses.¹⁹ In the pre-antibiotic era, about 90% of all infected aneurysms were mycotic aneurysms.²⁰ In 1984, Brown and colleagues²¹ reported that *Staphylococcus aureus* and various species of streptococcus represent 38% of infected aneurysms, while in 1986, Magilligan and Quinn²² showed that the predominant infectious microorganisms in patients with endocarditis and infected aneurysms is *Streptococcus viridans* (22%), *Staphylococcus aureus* (20%), *Streptococcus faecalis* (14%), and *Staphylococcus epidermidis* (11%).

Subsequent studies of large^{23 - 25} showed similar results with *Staphylococcus* species and *Streptococcus* occupy 30% of mycotic aneurysms.

Microbial arteritis- formation AA: Prevalence of infected aneurysms from microbial arteritis is estimated to be 0.06% to 0.65%.²⁶ Normally the inner arterial sheath is highly resistant to infection, but it seems that the process of atherosclerosis predisposes to embolisation and microbial colonization of the arterial wall²⁸⁻³⁰ with subsequent infection, suppuration, localized perforation, and formation of a false aneurysm. Several co-morbid conditions associated with some degree of immunosuppression is frequent and reported in up to 70% of patients with infected aneurysms on ground of microbial arteritis.^{23,31} The predominant organisms associated with microbial arteritis leading to aneurysms are *Escherichia coli* and *Salmonella* species and *Staphylococcus*.³² There are many references²⁶ about the importance of *Salmonella* in microbial arteritis, particularly in microbial aortitis. The most virulent *Salmonella* species are *S. choleraesuis* and *S. typhimurium*, which represent 62% of cases.³² Other microorganisms that have been isolated are *Listeria monocytogenes*, *Klebsiella pneumoniae*, *Clostridium septicum* and *Aspergillus niger*³⁴⁻³⁶

Infection arterial aneurysm: Infection of atherosclerotic aneurysms is relatively rare⁸ and is estimated to 3.4% but emphasizes the tendency for rupture.³⁷ The colonized by microbes' aortic aneurysms presented in two almost simultaneous reports from Ernst³⁸ and associates and Williams and Fisher.³⁹ In prospective studies of patients undergoing open abdominal aortic aneurysm restoration, cultures were obtained in samples of the wall and the contents of the aneurysm sac. Overall, 15% of cultures yielded positive results while there was a higher prevalence of positive cultures in patients with ruptured aneurysm (38%) than in those with asymptomatic (9%) and symptomatic (13%) aneurysms.³⁸ The most common organism implicated is *Staphylococcus* while there is a predominance of Gram- positive (59%) against Gram- negative (35%) of microorganisms.³⁷ Infection in preexisting aneurysm may be related to the subsequent infection of the stent²⁷ after endovascular implantation and is presented in 1% of endoluminal prostheses.³³

Traumatic false contaminated AA: In recent decades the infected traumatic false aneurysm has become the most frequent type of infected aneurysm in clinical practice and the main etiological factor is intravenous drug abuse³³ and iatrogenic injuries.⁴⁰ Frequently occurs in femoral triangle, but also presents to iliac, subclavian, brachial, and carotid arteries with less frequency. While the most frequent organism isolated is *Staphylococcus Aureus*.⁴¹

Clinical findings: Clinical picture of infected aneurysms depends on the causative mechanism and anatomical location. The clinical features of different types of aneurysms are summarized in Table 2. Although infected aneurysms affect all age groups,⁴² typical patient is older with advanced atherosclerosis.⁴³

Reddy DJ, Shepard AD, Evans JR, et al. Management of infected aortoiliac aneurysms. Arch Surg. 1991;126:873. Because of its insidious clinical picture infected aneurysms requires a high degree of suspicion especially in the following cases: positive blood cultures, corrosion of lumbar vertebrae, female gender, and presence of calcification in aneurysm wall

after microbial sepsis especially in immunocompromised patients.^{42,44} The clinical manifestation of these rare infections may be limited to fever or malaise or may be more apparent as peripheral limb gangrene due to distal embolization. All infected aneurysms have in common that eventually lead to sepsis or bleeding. Consequently, whenever the surgeon suspects this diagnosis, must act prompt to the confirmation of diagnosis and lead patient to urgent surgical treatment.

Diagnosis

Laboratory Tests: Leukocytosis, in most patients with infected aortic aneurysm, is a sensitive but non-specific marker.⁴⁵ The sensitivity of this index is further reduced when patients received previously antibiotic treatment, which suppressed, but did not cure the infection.⁴⁶ Similarly, increase in erythrocyte sedimentation rate (ESR) and C-reactive protein (CRP) are common detected in patients with infected aortic aneurysm but both deprived of specificity. Although positive cultures do not state specificity, when microorganisms are isolated from patients with aneurysm, are diagnosed with infected aneurysm until proven otherwise. Since positive blood cultures appear in about half of patients,⁴⁷ a negative blood culture alone is not sensitive enough to rule out the diagnosis of an infected aneurysm. During surgery suspicious outbreaks as pus or other unusual occurrence of periaortic tissue should be cultivated, as well as samples from the aortic wall and content of aneurysmal sac to direct staining Gram, aerobic, anaerobic and fungus. Nevertheless, neither negative blood cultures but neither negative intraoperative Gram stain is sensitive enough to exclude the diagnosis of infected aneurysm.²¹

Imaging tests: Ultrasonography of the abdominal aorta is a safe non-invasive imaging method and provides general information about the size of the aneurysm and location but is less reliable for detecting the presence or extent of infection. CT angiography (CTA) is the test of choice while findings may include saccular aneurysms or eccentric aneurysms in an otherwise normal aorta, inflammation of soft tissue or a mass around the aorta, and rupture or erosion. Other findings may include multilobar aneurysm and eccentric aneurysms with relatively narrow neck appearing specifically in infected aneurysms from microbial arteritis. Although CTA is a valuable imaging method for determining aneurysms, etiology and presence or absence of rupture, still fails to confirm the presence or absence of infection.⁴⁸⁻⁵⁰ Magnetic resonance imaging (MRI) can display useful information on retesting anatomic areas or when radiation or the use of contrast is contraindicated. The use of MRI is being reported with increasing frequency.^{50,51} Although not so frequently used after the development of CTA, digital subtraction angiography (DSA) is used in the diagnosis and treatment of infected aneurysms. The arteriogram criteria for aneurysmal infection are saccular aneurysm in an otherwise normal aortic aneurysm and multilobe and eccentric aneurysm with a relatively narrow neck. However, infected aneurysms may not present any of arteriography characteristic indicative of infection.⁵²

Surgical treatment

Preoperative preparation: In any suspicion of an infected aneurysm indication to start antibiotic therapy with broad spectrum antibiotics and must be continued until the causative microorganism is isolated.

Antimicrobial therapy should be adjusted to the isolated microorganism specifically targeted and always according to the sensitivities of the antibiogram. Drug therapy should be started prior to surgery and continued for long postoperatively and sometimes life-long.^{28,52} Although specific targeted antibiotic therapy contributes significantly to successful surgical treatment of an infected aneurysm, the survival of patients mainly depends on early diagnosis and surgery.²⁶ Reports of conservative treatment for infected aneurysms represent bibliographic exceptions.⁵³ In cases of symptomatic or ruptured infected aneurysm, surgery should be performed emergently.

Surgical principles

Traditionally six principles are applied in the surgical management of infected aneurysms:

- Control of bleeding
- Diagnosis of infection confirmed with direct Gram stain and cultures for aerobic, anaerobic, and fungal
- Aneurysmatectomy accompanied by wide debridement of all infected surrounding tissue and abundant local washes with antibiotics solutions and placement of large bore drains where necessary
- Meticulous postoperative wound care, including frequent changes of dressings and additional debridement as needed.
- Prolonged administration of antibiotics postoperatively according to antibiogram
- Arterial reconstruction of vital arteries through uninfected tissue planes with selected use of interposition grafting, soft tissue coverage such as omental wrap if possible, and the use of autologous tissue for reconstruction.
- Traditionally excision followed by extra-anatomic reperfusion bypass is the preferred therapy.^{16, 21, 28, and 32} But in certain cases of infected thoracoabdominal aneurysms, orthotopic interference with synthetic graft is the only way.

Extra- anatomic bypass: Traditionally the elective procedure for infected infrarenal aortic aneurysms is resection of the aneurysm, broad debridement of all infected tissues, drainage installation and creation of axillobifemoral bypass (Figure 1) through uncontaminated tract.^{45,55} This approach spares the risk associated with the placement of a synthetic graft in the infected retroperitoneum.⁵⁵ In one of the largest multi-center studies, Bacourt and Koskas⁵⁶ reported early mortality in 24% and overall mortality was 42%. Complications specific to this method include rupture of the aortic stump in 50% when cultures at the site are positive and further infection of the axillobifemoral graft from 6% to 20% as reported in several studies.^{10,45,54,56,57}

Orthotopic reperfusion: Some surgeons advocate orthotopic interposition graft after the resection of an infected aortic aneurysm (Fig 2).^{21,28,55,58} When infected aneurysm comprises suprarenal aorta or thoracoabdominal aortic aneurysm, direct orthotopic reconstruction is the only option.²⁸ As in the extra-anatomic bypass, so in orthotopic procedure should always be preceded by extensive debridement of all necrotic and inflammatory tissues until disclosure of healthy aortic tissue which can be used to create a more secure anastomosis with the graft and omental coverage (fig. 2).

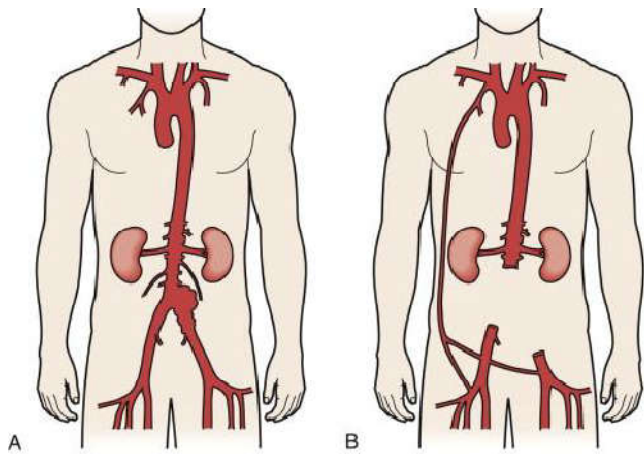


Figure 1

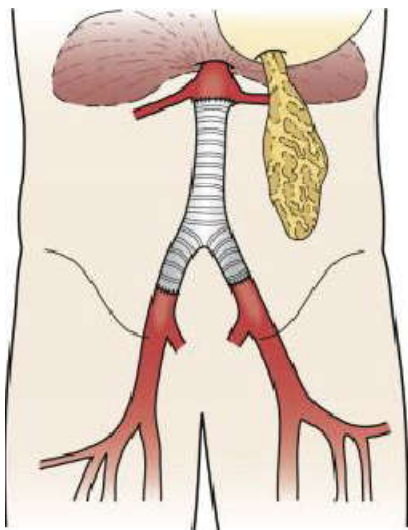


Figure 2

Prolonged antibiotic treatment is recommended by most authors, although the required period has not been clearly defined.

Endovascular treatment: Experience in endovascular treatment of aortic aneurysmal disease has increased significantly in the last decade and successful endovascular treatment of infected aortic aneurysms is increasing.⁵⁹⁻⁶¹ Kan and colleagues in their metanalysis reviewed the existing literature on the endovascular treatment of infected aneurysms of the aorta and reported a survival rate of 89% at 30 days and 82% survival at 2 years in a total number of 48 patients.⁵⁹ Following successful endovascular treatment of infected aortic aneurysms Kritpracha and colleagues⁶² in 2010 reported 94% survival at 2 years, excluding from these infected aneurysms with aortocaval, aortoenteric, aorto-esophageal and aortobronchial fistulas which showed up to 60% in-hospital mortality.

Purpose: Although the endovascular approach, of degenerative type, of aortic aneurysms are a proven safe therapeutic option for selected patients, the role of the infected aortic aneurysms remains controversial. In this study we try to present the advantages of endovascular management in patients with infected aortic aneurysms and to clarify the factors that affect disease progression and determine the favorable or unfavorable outcome of these patients.

MATERIAL AND METHOD

A retrospective systematic study was performed in PubMed, Medline, Embase, Google Scholar and Scopus according to the recommendations of the PRISMA statement for administrative dataset registries for patients treated intravascularly for primary infected aortic aneurysm, using the key words: infected (infected), mycotic (mycotic), aorta (aorta), aneurysm (aneurysm), and intravascular intervention (stent graft). From all the research we found and thoroughly evaluated 36 studies and the literature reports. Studies with previous endovascular aortic aneurysm repair with stents were all excluded. The term mycotic aneurysm was taken in account equally as infected aneurysm in the absence of mycotic endocarditis or other mycotic septic origin. The cured patient is defined as the afebrile, hemodynamically normal, sepsis-free and signs of bleeding during the monitoring period.

RESULTS

Prolonged fever, rupture and aortoenteric, aortobronchial, and aorto-esophageal fistulas greatly increased the reoperation rates and mortality of these patients.⁶² Survival rates in patients without fistulae in recent studies⁶² could reach even 94% at 2 years. Positive blood cultures were isolated in 63.5% of patients^{62,63} with frequent microorganisms constitute the Salmonella^{32,62} and Staph. Aureus.^{41,63} Ruptured aneurysms account for 35% of infected aortic aneurysms.^{59,63} The overall survival of the first 30 days is from 81% to 94% whereas the medium survival at 2 years from 73% to 94% in various references.^{59,62,63,64} Independent aggravating factors appeared to maintain the infection was a) age > 65, b) rupture (including aortoenteric, aortobronchial fistulas), and c) febrile patients during surgery, while protective factors were a) preoperative use of antibiotics for more than one week and b) adjunctive therapy in association with EVAR.⁵⁹

DISCUSSION

The management of infected aortic aneurysms is a clinical challenge for the vascular surgeon because apart from the rarity of these incidents their symptoms are unspecific and unclear. Nevertheless, the classical triad of fever, abdominal pain and leukocytosis are present in most patients.^{24,63} Given the high morbidity and mortality of those traditionally laborious and major open operations for those patients, minimally invasive endovascular treatment offers a therapeutic alternative particularly for those high perioperative risk patients. Endovascular surgery provides significant advantages over open surgery, such as avoid large incision, aortic clamp, systemic heparinization, extracorporeal circulation, massive blood transfusion and surcharge of respiratory and renal function.⁶⁵ Nevertheless, the endovascular placement of a device in a generally contaminated environment comes in contradiction with the principles of surgery. Endovascular treatment of infected aortic aneurysms was introduced more than a decade ago¹⁸ and since then from several small studies showed favorable results.^{63,66} Similarly a systematic meta-analysis⁵⁹ showed 48 cases of infected aortic aneurysms treated endovascularly, demonstrating an early mortality at 10.4% while unfavorable prognosis for patients with fever and / or rupture, one finding that was not confirmed by Kritpracha and partners 2011.

Table 1

	Mycotic AA	Microbial Arteritis AA	Infected AA	Posttraumatic- False AA
Etiology	Endocarditis	Bacteremia	Bacteremia	Trauma, Drug Abuse
Age	30-50	>50	>50	<30
Incidence	Rare	Common	Unusual	Common
Location	Aorta, Visceral, Intracranial, Peripheral	Aorta, Iliac artery, Intimal defects	Infrarenal Aorta	Femoral, Carotid
Microbiology	Gram (+) cocci	Salmonella & Others	Staphylococcus & Others	Staphylococcus aureus
Mortality	25%	75%	90%	5%

Table 2

Clinical marker	Number of patients (%)
Abdominal pain	12 (92)
Fever	10 (77)
Leukocytosis (>10x10 ⁹ /L)	9 (69)
Positive blood cultures	9 (69)
Palpable abdominal mass	6 (46)
Rupture	4 (31)

In addition, the latter showed early and mid-term two-year overall survival rate of 94% in patients without aortoenteric, aorto-esophageal or aortobronchial fistulas.⁶² Regardless the initial reconstructive surgery, when a fistula is present, traditionally is managed by graft explantation, wide debridement of the infected tissues, infrarenal aortic stump ligation, and extra-anatomic revascularization with axillobifemoral bypass.⁶⁷ The concept of permissive hypotension has been successfully applied in the routine clinical management of multiple trauma and the applicability to the treatment of ruptured AAA has been well demonstrated.⁶⁹ Endovascular treatment of infected aortic aneurysms seems that gained ground in the last decade, but the exact role remains to be elucidated.^{65, 66, 67, 68} Finally antibiotic treatment is crucial, and the antibiotic treatment should be individualized as appropriate.⁶³

CONCLUSION

Treatment of infected aortic aneurysms using endovascular aortic devices is continuously increasing, providing an alternative therapy since it greatly simplifies the management of patients who are in this critical condition. Special emphasis should be given in the perioperative, targeted antibiotic treatment and the careful post-operative monitoring. Endovascular treatment of infected aortic aneurysms is feasible both as a temporary measure, and the preferred definitive treatment in selected patients, showing better early and mid-term results. Nevertheless, a randomized multicenter clinical study, remains to prove that endovascular treatment of patients with infected aortic aneurysms is superior to conventional surgery, alongside long-term results.

REFERENCES

- Huebl HC, Read RC: Aneurysmal abscess. *Minn Med* 1966; 49:11.
- Paré A: Of aneurismas. The Apologie and Treatise Containing the Voyages Made into Divers Places with Many of His Writings upon Surgery, Birmingham, AL: The Classics of Surgery Library; 1984.
- Rokitansky CF: *Handbuch der Pathologischen Anatomie*. Austria 2nd ed. 1844.
- Koch R: Ueber aneurysma der arteria mesenterica superior [About an aneurysm of the superior mesenteric artery]. In: Erlangen JJ, ed. *Inaug Dural-Abhandlung*, Barfus'schen: Universitaets-Buchdruckerei; 1851.
- Tufnell J: On the influence of vegetation of the valves of the heart in the production of secondary arterial disease. *Dublin Q J Med* 1885; 15:371.
- Osler W: The Gulstonian lectures on malignant endocarditis. *BMJ* 1885; 1:467.
- M. Dubois, I. Fournau, Treatment of Mycotic Aneurysms with Involvement of the Abdominal Aorta, *Eur J Vasc Endovasc Surg* (2010) 40, 450-456.
- Sommerville RI, Allen EV, Edwards JE: Bland and infected arteriosclerotic abdominal aortic aneurysms: a clinicopathologic study. *Medicine (Baltimore)* 1959; 38:207.
- Bennett DE, Cherry JK: Bacterial infection of aortic aneurysms: a clinicopathologic study. *Am J Surg* 1967; 113:321..
- Elliott JP, Smith RF, Szilagyi DE: Aortoenteric and paraprostatic-enteric fistulas. *Arch Surg* 1974; 114:1041.
- Gouny P, Valverde A, Vincent D: Human immunodeficiency virus and infected aneurysm of the abdominal aorta: report of three cases. *Ann Vasc Surg* 1992; 6:239.
- Baker WH, Moran JM, Dormer DB: Infected aortic aneurysm following arteriography. *J Cardiovasc Surg* 1979; 20:313.
- Soderstrom CA, Wasserman DJ, Ransom KJ, et al: Infected false femoral artery aneurysms secondary to monitoring catheters. *J Cardiovasc Surg* 1983; 24:63.
- Patel KR, Semel L, Clauss RH: Routine revascularization with resection of infected femoral pseudoaneurysms from substance abuse. *J Vasc Surg* 1988; 8:321.
- Padberg F, Hobson II R, Lee B, et al: Femoral pseudoaneurysm from drugs of abuse: ligation or reconstruction?. *J Vasc Surg* 1992; 15:642.
- Noel AA, Gloviczki P, Cherry Jr KJ, et al: Abdominal aortic reconstruction in infected fields: early results of the United States cryopreserved aortic allograft registry. *J Vasc Surg* 2002; 35:847.
- Vogt PR, Brunner-LaRocca HP, Lachat M, et al: Technical details with the use of cryopreserved arterial allograft for aortic infection: influence on early and mid term mortality. *J Vasc Surg* 2002; 35:80.

18. Semba CP, Sakai T, Dake MD. Mycotic aneurysms of the thoracic aorta: repair with use of endovascular stent-grafts. *J Vasc Interv Radiol* 1998 Jan-Feb;9(1 Pt 1):33-40.
19. Reid MR: Studies on abnormal arteriovenous communications, acquired and congenital: I. Report of a series of cases. *Arch Surg* 1925; 10:601.
20. Revell STR: Primary mycotic aneurysms. *Ann Intern Med* 1943; 22:431.
21. Brown SL, Busutill RW, Baker JD, et al: Bacteriologic and surgical determinants of survival in patients with mycotic aneurysms. *J Vasc Surg* 1984; 1:541.
22. Magilligan Jr DJ, Quinn EL: Endocarditis. Medical and Surgical Management. New York, NY, Marcel Dekker, 1986.
23. Hsu RB, Tsay YG, Wang SS, Chu SH: Surgical treatment for primary infected aneurysm of the descending thoracic aorta, abdominal aorta and iliac arteries. *J Vasc Surg* 2002; 36:746.
24. Moneta GL, Taylor LM, Yeager RA, et al: Surgical treatment of infected aortic aneurysm. *Am J Surg* 1998; 175:396.
25. Muller BT, Wegener OR, Grabitz K, et al: Mycotic aneurysms of the thoracic and abdominal aorta and iliac arteries: experience with anatomic and extra-anatomic repair in 33 cases. *J Vasc Surg* 2001; 33:106.
26. Reddy DJ, Shepard AD, Evans JR, et al: Management of infected aortoiliac aneurysms. *Arch Surg* 1991; 126:873.
27. Parodi JC: Endovascular repair of abdominal aortic aneurysms and other arterial lesions. *J Vasc Surg* 1995; 21:549.
28. Chan YF, Crawford ES, Coselli JS, et al: In situ prosthetic graft replacement for mycotic aneurysms of the aorta. *Ann Thorac Surg* 1989; 47:193.
29. Mundth ED, Darling RC, Alvarado RH, et al: Surgical management of mycotic aneurysms and the complications of infection in vascular reconstructive surgery. *Am J Surg* 1969; 117:460.
30. Patel S, Johnson KW: Classification and management of mycotic aneurysm. *Surg Gynecol Obstet* 1977; 144:691.
31. Oderich GS, Panneton JM, Bower TC, et al: Infected aortic aneurysms: aggressive presentation, complicated early outcome but durable results. *J Vasc Surg* 2001; 34:900.
32. Wilson SE, Van Wagenen P, Passaro Jr E: Arterial infection. *Curr Probl Surg* 1978; 15:5.
33. Greenberg R, Chuer TA, Sternbergh 3rd UC, Fearnot NE: Zenith AAA endovascular graft: intermediate-term results of the US multicenter trial. *J Vasc Surg* 2004; 39:1209.
34. Gauto AR, Cone LA, Woodard DR, et al: Arterial infections due to *Listeria monocytogenes*: report of four cases and review of world literature. *Clin Infect Dis* 1992; 14:23.
35. Montoya FJ, Weinstein-Moreno LF, Johnson CC: Mycotic thoracic aneurysm due to *Clostridium septicum* and occult adenocarcinoma of the cecum. *Clin Infect Dis* 1997; 24:785.
36. Sailors DM, Eidt JF, Gagne PJ, et al: Primary *Clostridium septicum* aortitis: a rare cause of necrotizing suprarenal aortic infection: a case report and review of the literature. *J Vasc Surg* 1996; 23:714.
37. Jarrett F, Darling RC, Mundth ED, et al: Experience with infected aneurysms of the abdominal aorta. *Arch Surg* 1975; 10:1281.
38. Ernst CB, Campbell Jr C, Daugherty ME, et al: Incidence and significance of intra-operative bacterial cultures during abdominal aortic aneurysmectomy. *Ann Surg* 1977; 185:626.
39. Williams RD, Fisher FW: Aneurysm contents as a source of graft infection. *Arch Surg* 1977; 112:415.
40. Malanoski GJ, Samore MH, Pefanis A, et al: Staphylococcus aureus catheter-associated bacteremia: minimal effective therapy and unusual infectious complications associated with arterial sheath catheters. *Arch Intern Med* 1995; 155:1161.
41. Gomes MN, Choyke PL, Wallace RB: Infected aortic aneurysms: a changing entity. *Ann Surg* 1992; 215:435.
42. Byard RW, Leduc JR, Chambers J, Walley VM: The rapid evolution of a large mycotic aneurysm of the abdominal aorta. *J Can Assoc Radiol* 1988; 39:62.
43. Bennett DE: Primary mycotic aneurysms of the aorta. *Arch Surg* 1967; 94:758.
44. Vogelzang RL, Sohaey R: Infected aortic aneurysms: CT appearance. *J Comput Assist Tomogr* 1988; 12:109.
45. Taylor Jr LM, Deitz DM, McConnell DB, Porter JM: Treatment of infected abdominal aneurysms by extra-anatomic bypass, aneurysm excision, and drainage. *Am J Surg* 1988; 155:655.
46. Miller BM, Waterhouse G, Alford RH, et al: Histoplasma infection of abdominal aortic aneurysms. *Ann Surg* 1983; 197:57.
47. Anderson CB, Butcher Jr HR, Ballinger WF, et al: Mycotic aneurysms. *Arch Surg* 1974; 109:712.
48. Gomes MH, Choyke PL: Infected aortic aneurysms: CT diagnosis. *J Cardiovasc Surg* 1992; 33:684.
49. Lee MH, Chan P, Chiou HJ, et al: Diagnostic imaging of Salmonella-related mycotic aneurysm of aorta by CT. *Clin Imaging* 1996; 20:26.
50. Moriarity JA, Edelman RR, Tumei SS: CT and MRI mycotic aneurysms of the abdominal aorta. *J Comput Assist Tomogr* 1992; 16:941.
51. Walsh DW, Ho VB, Haggerty MF: Mycotic aneurysm of the aorta: MRI and MRA features. *J Magn Reson Imaging* 1997; 7:312.
52. Crawford ES, Crawford JL, ed. Diseases of the Aorta Including an Atlas of Angiographic Pathology and Surgical Techniques, Baltimore, MD: Williams & Wilkins; 1984.
53. Eshaghy B, Scanlon RJ, Amirparviz F, et al: Mycotic aneurysm of brachial artery: a complication of retrograde catheterization. *JAMA* 1974; 228:1574.
54. Ewart JM, Burke ML, Bunt TJ: Spontaneous abdominal aortic infections: essentials of diagnosis and management. *Am Surg* 1983; 49:37.
55. Bacourt F, Koskas F: Axillofemoral artery bypass and aortic exclusion for vascular septic lesions: a multi-centered retrospective study of 98 cases. *Ann Vasc Surg* 1992; 6:119-126.
56. Mcbeth GA, Rubin JR, McIntyre KE, et al: The relevance of arterial wall microbiology in the treatment of prosthetic graft infections: graft infection versus arterial infection. *J Vasc Surg* 1984; 1:750.
57. Yeager RA, Taylor LM, Moneta GL, et al: Improved results with conventional management of infrarenal aortic infection. *J Vasc Surg* 1999; 30:76.
58. Oz MC, Brener BJ, Buda JA, et al: A ten-year experience with bacterial aortitis. *J Vasc Surg* 1989; 10:439.
59. Kan C, Lee H, Yang Y: Outcome after endovascular stent graft treatment for mycotic aortic aneurysm: a systematic review. *J Vasc Surg* 2007; 46:906.
60. Bell RE, Taylor PR, Aukett M, et al: Successful endoluminal repair of an infected thoracic pseudoaneurysm

- caused by methicillin-resistant *Staphylococcus aureus*. *J Endovasc Ther* 2003; 10:29.
61. Kotzampassakis N, Delanaye P, Masy F, Creemers E: Endovascular stent-graft for thoracic aorta aneurysm caused by *Salmonella*. *Eur J Cardiothorac Surg* 2004; 26:225.
62. Boonprasit Kritpracha, MD, Dhanakom Premprabha. Endovascular therapy for infected aortic aneurysms. 2011 by the Society for Vascular Surgery. doi:10.1016/j.jvs.2011.03.301
63. R.E. Clough, S.A. Black, O.T. Lyons, H.A. Zayed, R.E. Bell, P.R. Taylor. Is Endovascular Repair of Mycotic Aortic Aneurysms a Durable Treatment Option? *Eur J Vasc Endovasc Surg* (2009) 37, 407e412
64. Karl Söreljus, Kevin Mani, Anders Wanhainen, Endovascular repair of mycotic aortic aneurysms 2009 by the Society for Vascular Surgery. doi:10.1016/j.jvs.2009.01.001
65. Chan YC, Morales JP, Taylor PR. The management of mycotic aortic aneurysms: is there a role for endoluminal treatment? *Acta Chir Belg* 2005;105:580-7
66. Lee KH, Won JY, Lee DY, Choi DH, Shim WH et al. Stent graft treatment of infected aortic and arterial aneurysms. 2006;13:338-45
67. Ioannis Stamatatos, electra kyrochristou, housein-elias zogbi, et al: Endovascular Treatment of Ruptured Secondary Aortoenteric Fistula 10 years after Open Repair of AAA. *Authorea*. April 06, 2020. DOI: 10.22541/au.158618439.94875969
68. Nadia Vallejo, Natasha Emma Picardo, Richard G.J. Gibbs et al. The changing management of primary mycotic aortic aneurysms. 2011 by the Society for Vascular Surgery. doi: 10.1016/j.jvs.2010.12.066
69. Stamatatos I, Metaxas E, Georgoudi S, Theodorou M, Milou EE, et al. (2018) Proper Management of Ruptured Abdominal Aortic Aneurysm. *Ann Cardiovasc Dis* 3(1): 1020
